CLERMONT-FERRAND
CENTRE HOSPITALIER UNIVERSITAIRE
UNIVERSITÉ Clermont Auvergne
Pascal Motreff, MD, PhD

13ÈME CARDIO RUN 2021
CONGRÈS DE PATHOLOGIE CARDIO-VASCULAIRE
29-30 SEPTEMBRE & 1 OCTOBRE 2021
HÔTEL SAINT ALEXIS - ÎLE DE LA RÉUNION, FRANCE

Le Paratonnerre

Mme Sophie. C, 55 ans

- **FRCV :** dyslipidémie, surpoids, tabagisme 30 P.A stoppé
- **ATCD :** névralgie cervico brachiale, AOMI avec stenting iliaque 2014

- **HDLM** : vague gêne thoracique d'effort, examen, ECG de repos et échocardiographie normaux, **EE positive en Décembre 2019**

Mme Sophie. C, 55 ans

- **FRCV :** dyslipidémie, surpoids, tabagisme 30 P.A stoppé
- **ATCD :** névralgie cervico brachiale, AOMI avec stenting iliaque 2014

- **HDLM** : vague gêne thoracique d'effort, examen, ECG de repos et échocardiographie normaux, **EE positive en Décembre 2019**

➡ Coronarographie

Mme Sophie. C, 55 ans

Coronarographie Janvier 2020

- Examen réalisé dans un grand centre Français sans couverture chirurgicale (opérateur excellent)

- Abord radial droit
- Coronaire droite normale
- Occlusion chronique courte IVA proximale
- Viabilité antérieure certaine, décision de recanalisation endoluminale

→ **Angioplastie CTO de l'IVA**

Mme Sophie. C, 55 ans

Angioplastie IVA Janvier 2020

- Recanalisation simple au guide par voie antérograde
- Stenting IVA proximale

Mme Sophie. C, 55 ans

Angioplastie IVA Janvier 2020

- Recanalisation simple au guide par voie antérograde
- Stenting IVA proximale

Mme Sophie. C, 55 ans

Angioplastie IVA Janvier 2020

- Recanalisation simple au guide par voie antérograde
- Stenting IVA proximale

- Rupture coronaire avec hémopéricarde
- Hémostase au ballon, MCE durant 10mn, manœuvres de réanimation durée totale 45mn, drainage péricardique
- Décision de **stent couvert Papyrus*** (Biotronik) au niveau de la fin du TC en direction de l'IVA sacrifiant la circonflexe

Mme Sophie. C, 55 ans

Suites simples

- 48h en réanimation, extubée sans séquelle
- Hypokinésie latérale, FEVG = 55%
- DAPT au moins 12 mois
- Invitée à un contrôle coronarographique à 6 mois (Papyrus?)

Revoit son généraliste à 6 mois :

- Dyspnée modérée sans angor, contrôle coro systématique au CHU de Clermont-Ferrand
- Allo à mon ami…t'inquiète pas…j'arrange le coup, elle va reprendre confiance…

Contrôle coro Août 2020

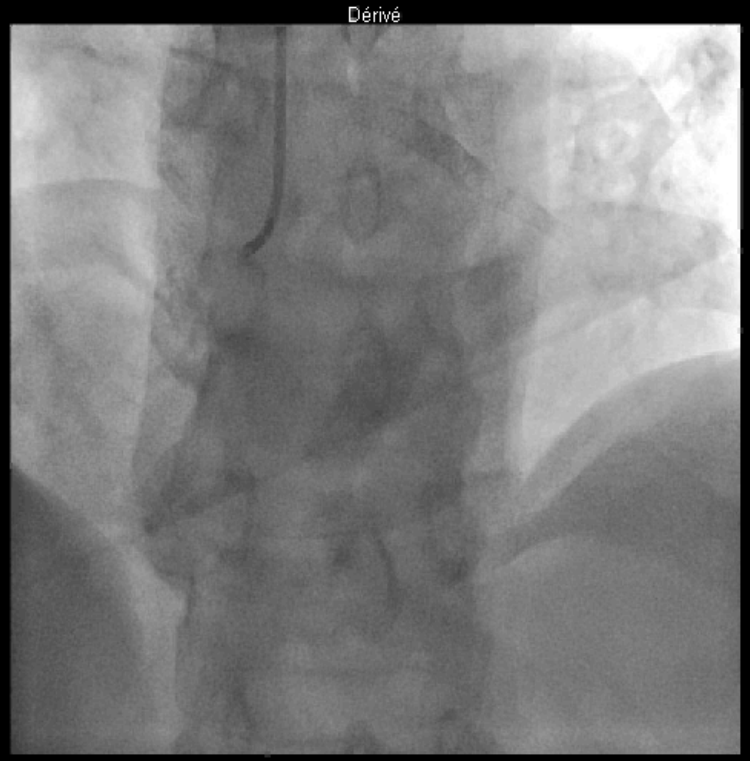

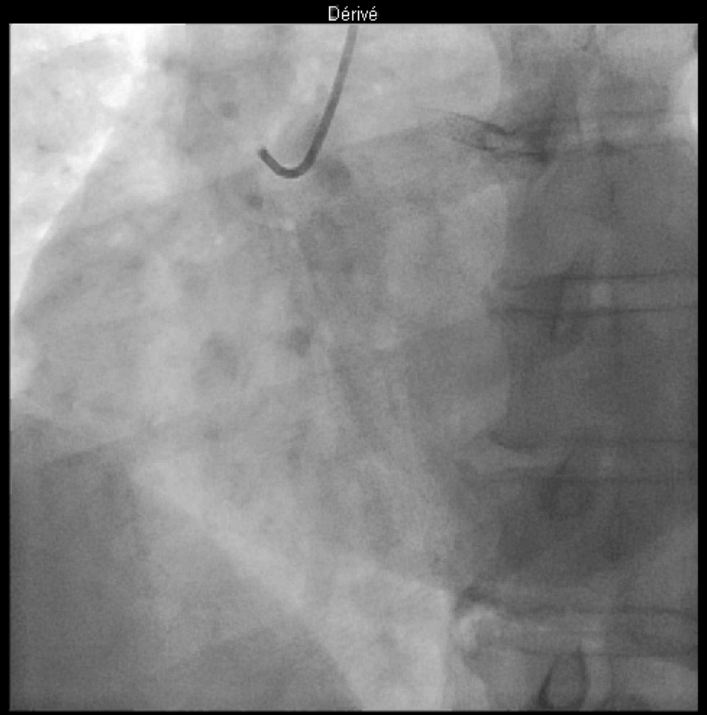

Contrôle coro Août 2020

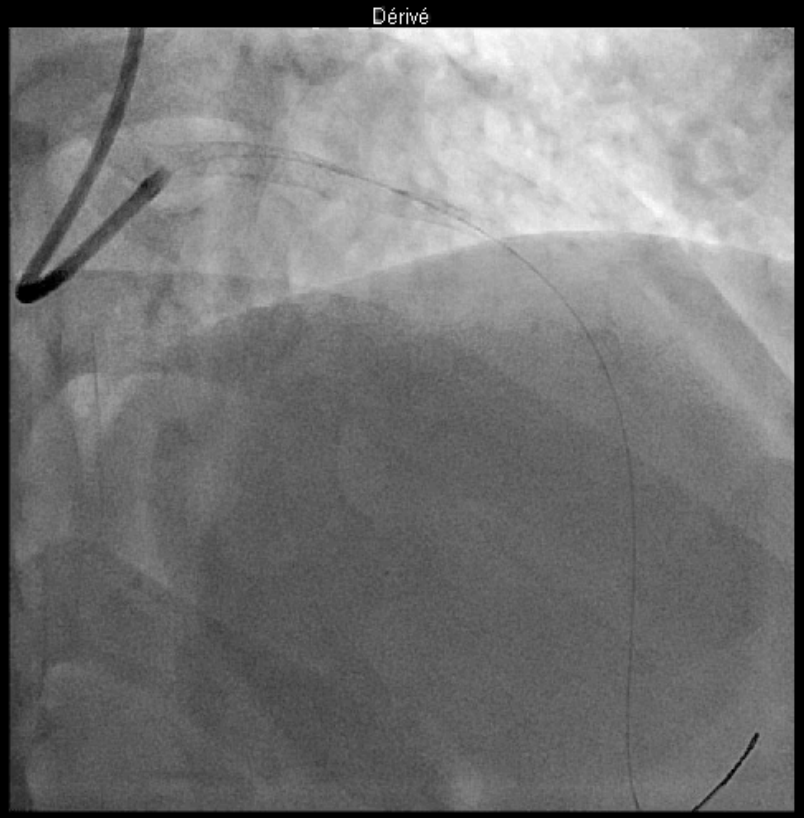

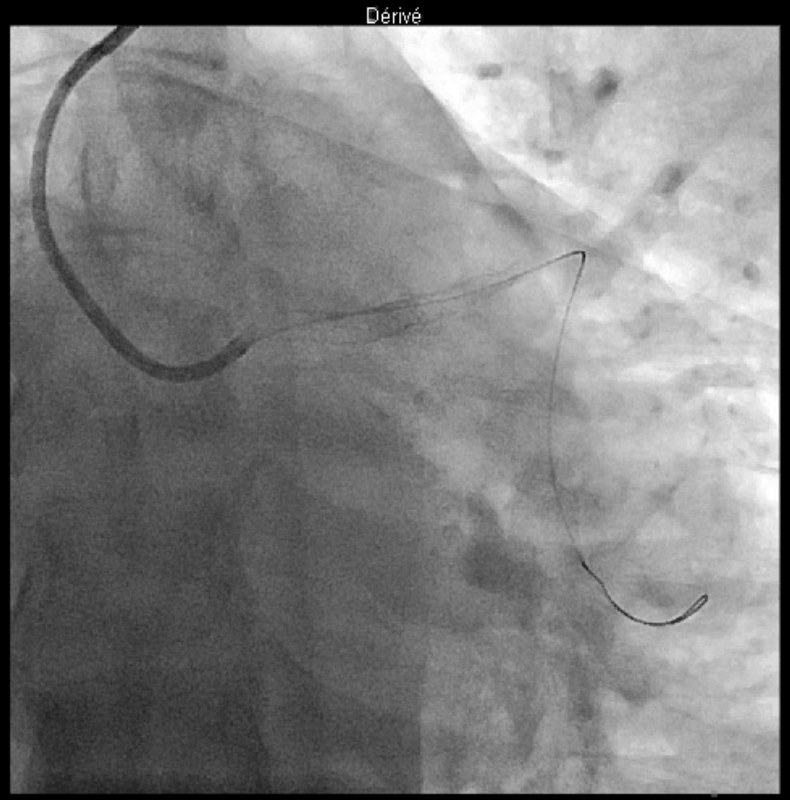

Guide BMW pour optimiser support
Arriere pense d’imagerie endocoronaire

Contrôle coro Août 2020

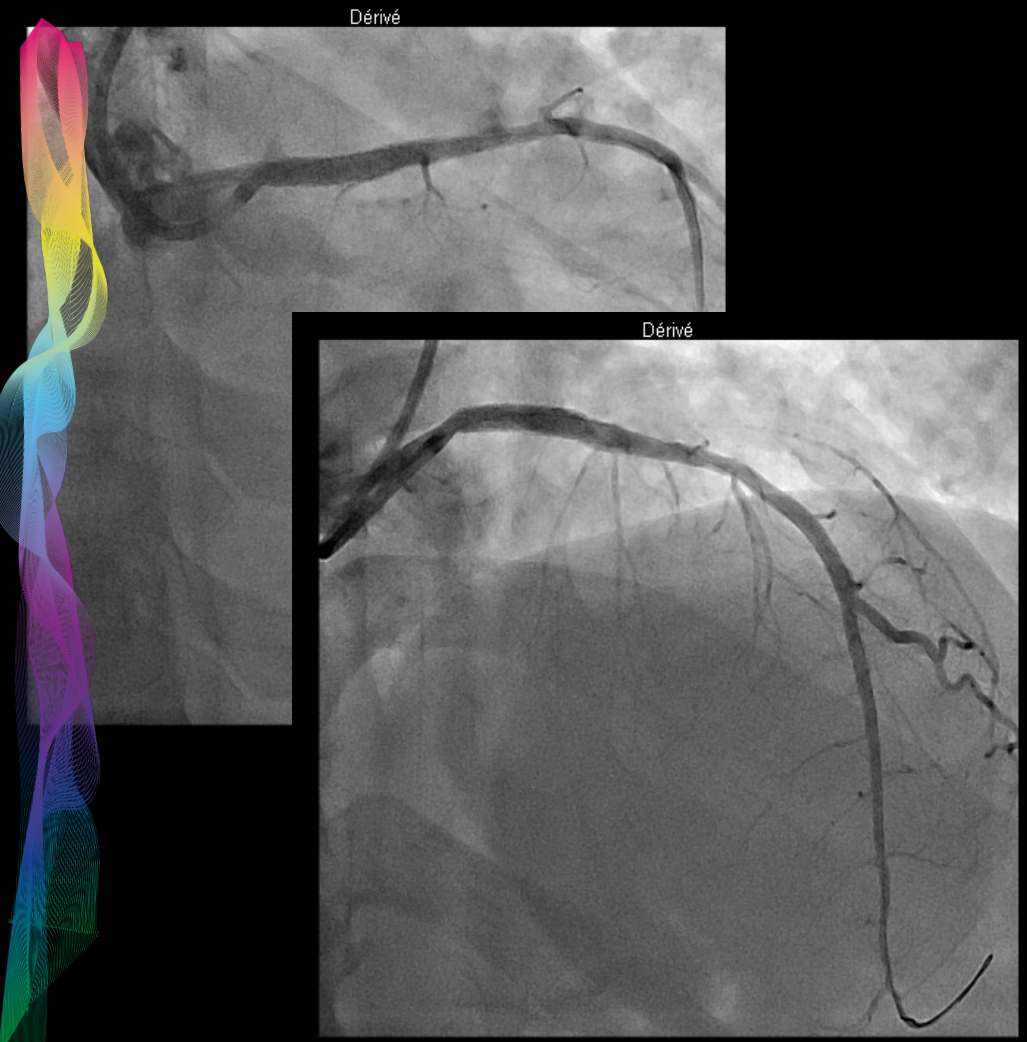

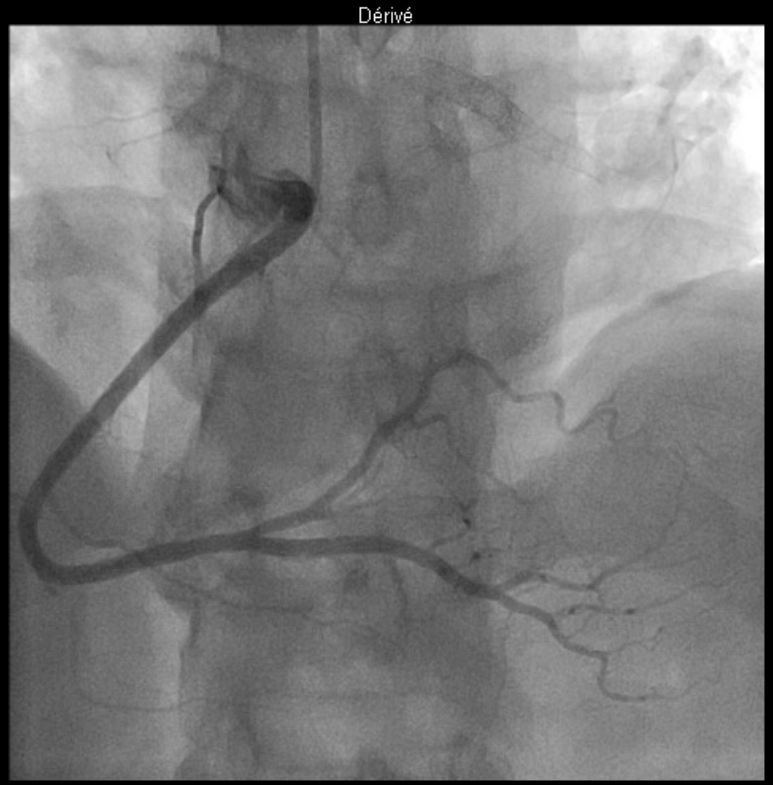

Mme Sophie. C, 55 ans

Contrôle coro Août 2020

- CD sans lésion
- Excellent résultat sur TC et IVA, pas de resténose (on décide de ne pas faire d'imagerie), faible reprise Cx
- Illusoire de recanaliser la Cx
- Chirurgie de pontage disproportionnée, à réserver si évolution péjorative du TC
- Poursuite DAPT au moins 3 ans
- Allo à mon ami…tout va bien

Mme Sophie. C, 55 ans

Contrôle coro Août 2020

- CD sans lésion
- Excellent résultat sur TC et IVA, pas de resténose (on décide de ne pas faire d'imagerie), faible reprise Cx
- Illusoire de recanaliser la Cx
- Chirurgie de pontage disproportionnée, à réserver si évolution péjorative du TC
- Poursuite DAPT au moins 3 ans
- Allo à mon ami…tout va bien

Mme Sophie. C, 55 ans

Contrôle coro Août 2020

- CD sans lésion
- Excellent résultat sur TC et IVA, pas de resténose (on décide de ne pas faire d'imagerie), faible reprise Cx
- Illusoire de recanaliser la Cx
- Chirurgie de pontage disproportionnée, à réserver si évolution péjorative du TC
- Poursuite DAPT au moins 3 ans

40 mn plus tard

« Monsieur, la jeune de tout à l'heure, elle est pas bien et elle sus-décale en inférieur… »

Mme Sophie. C, 55 ans

- Relecture du film

JR 3.5 diagnostique 5F, peu agressive
Aucun souci per-procédure

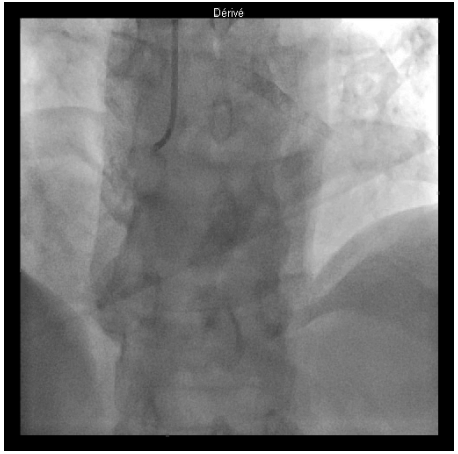

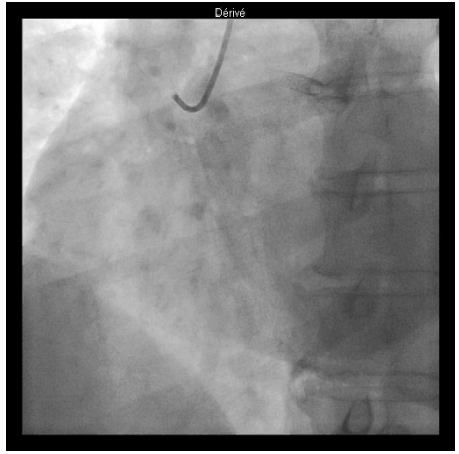

- Evoque un spasme
- Soulagée par nitrés avec normalisation de l’ECG

Mme Sophie. C, 55 ans

- Relecture du film

JR 3.5 diagnostique 5F, peu agressive
Aucun souci per-procédure

- Evoque un spasme
- Soulagée par nitrés avec normalisation de l'ECG
- **Récidive douloureuse 30' plus tard, TNT résistante**
- **Nouvelle coro sur SCA ST+ inférieur**

Coro en urgence, ST+ inférieur

JR 3.5 en 5F

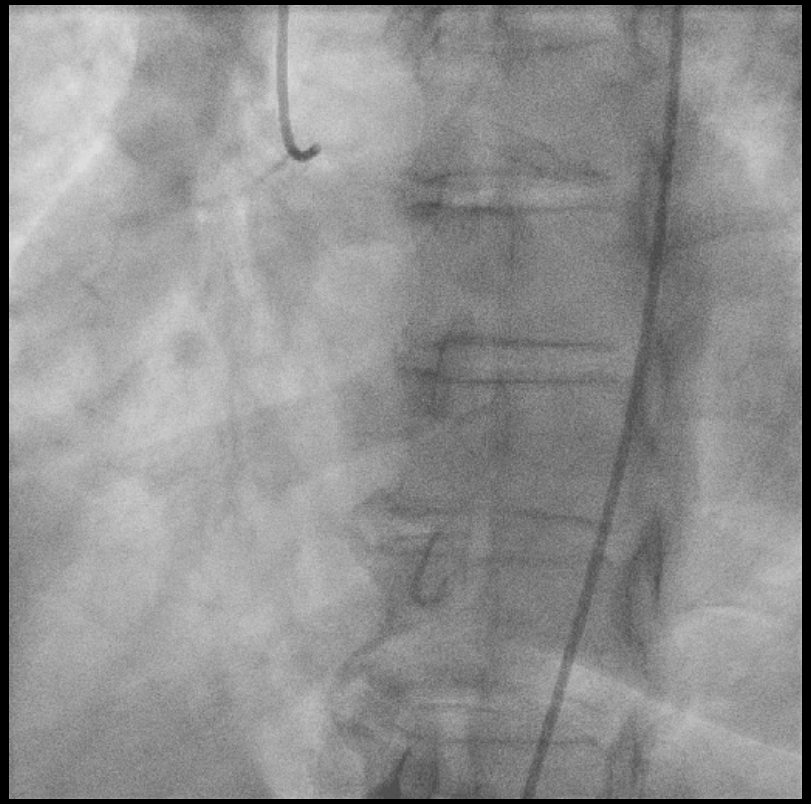

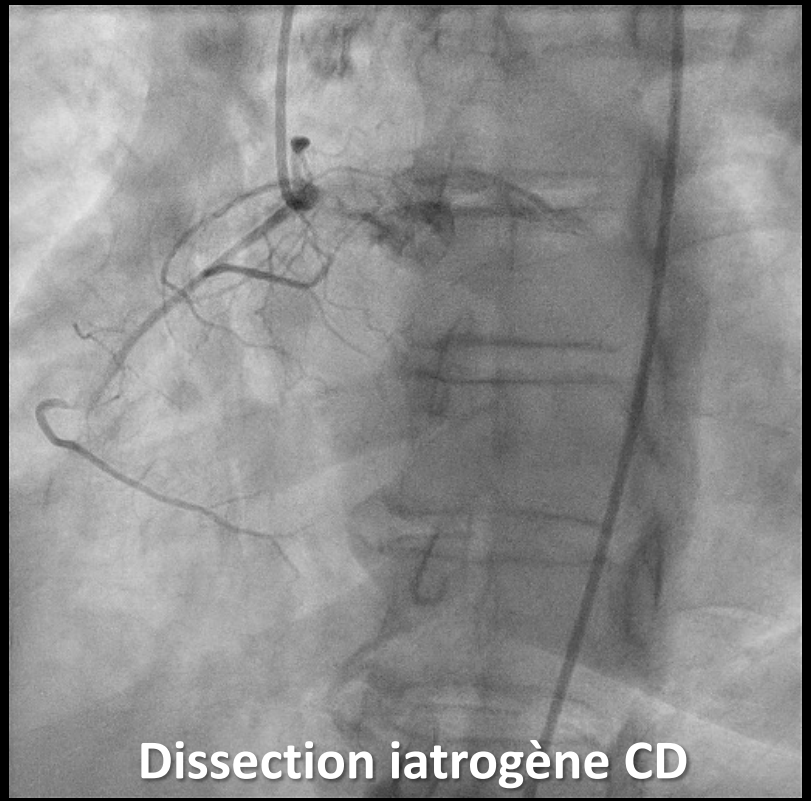

Coro en urgence, ST+ inférieur

ALR en 6F, guide BMW

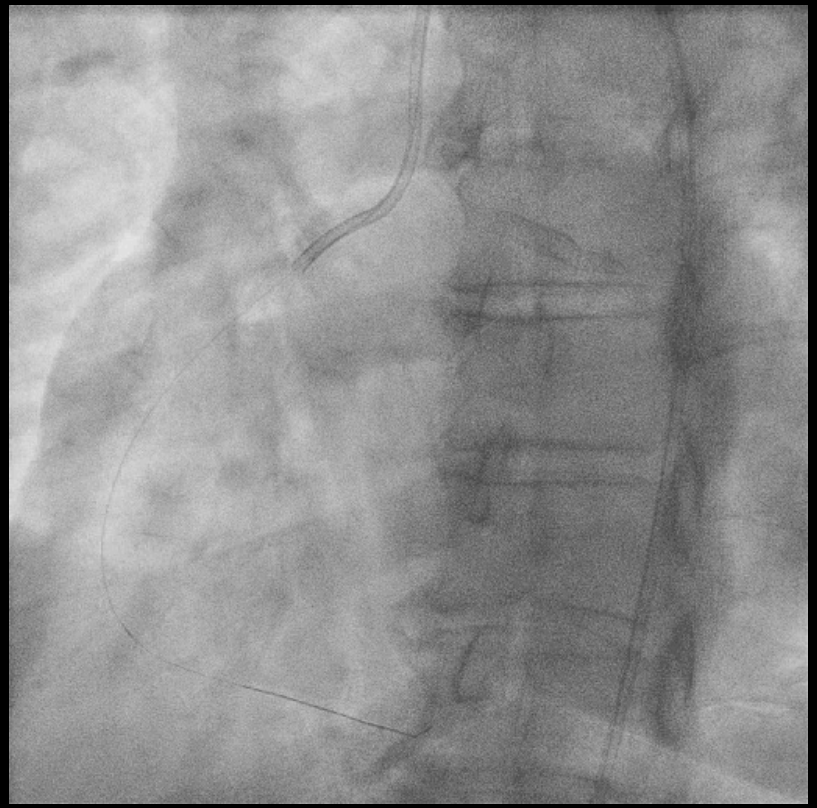

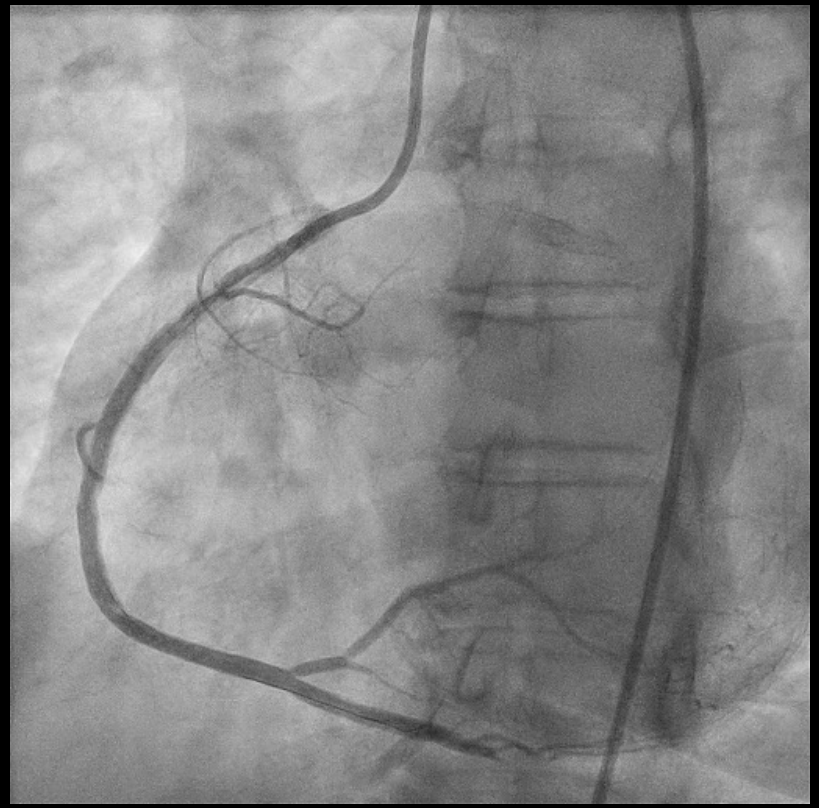

Recanalisation au guide BMW

Coro en urgence, ST+ inférieur

ALR en 6F, guide BMW

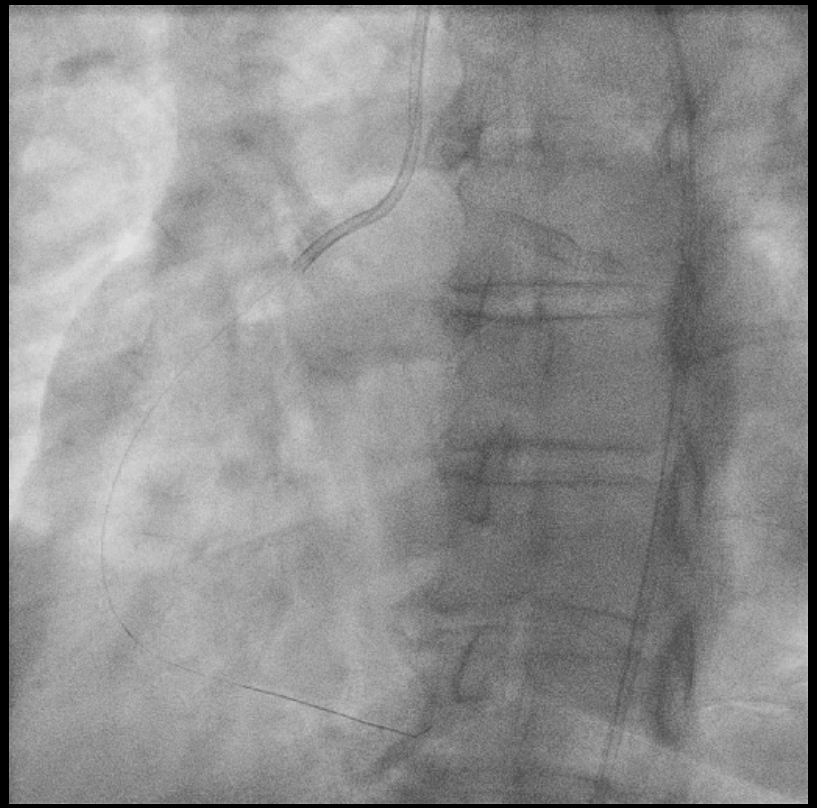

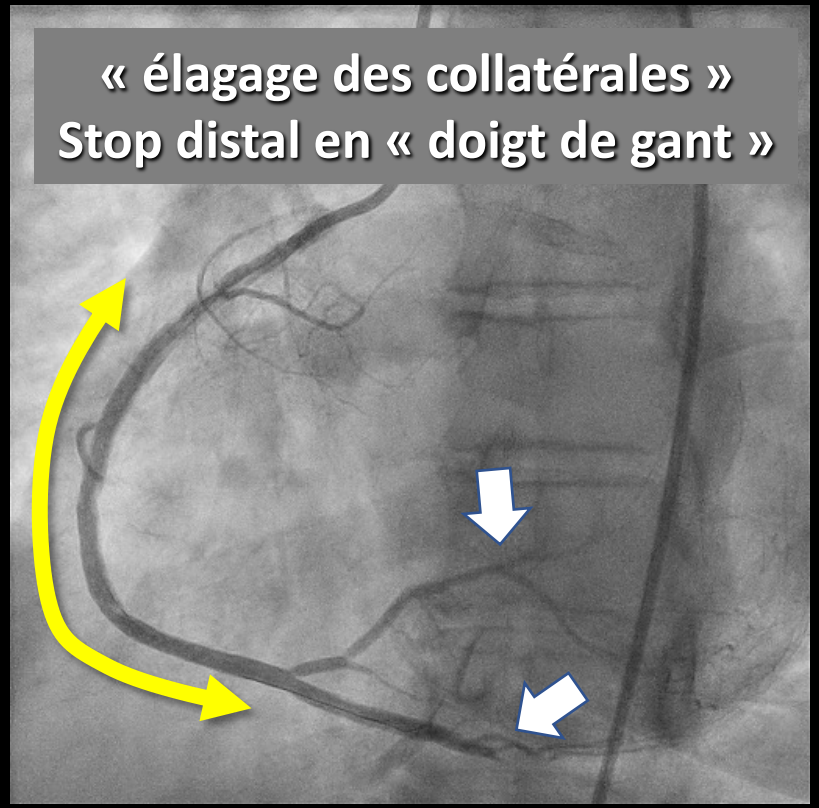

BMW probablement dans fausse lumière

Multiples tentatives d’emprunter autres trajets avec guides Whisper

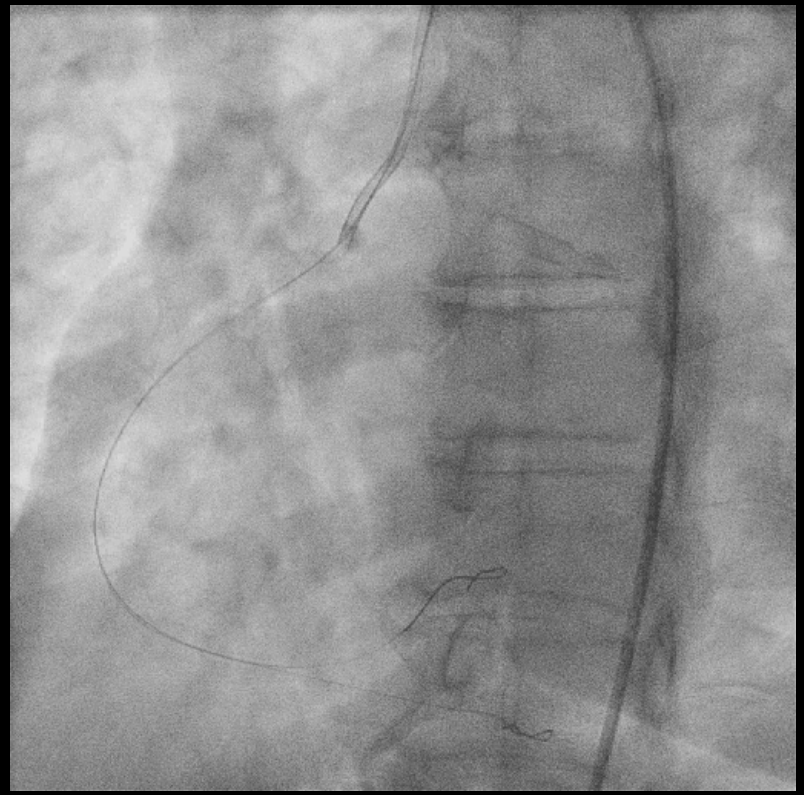

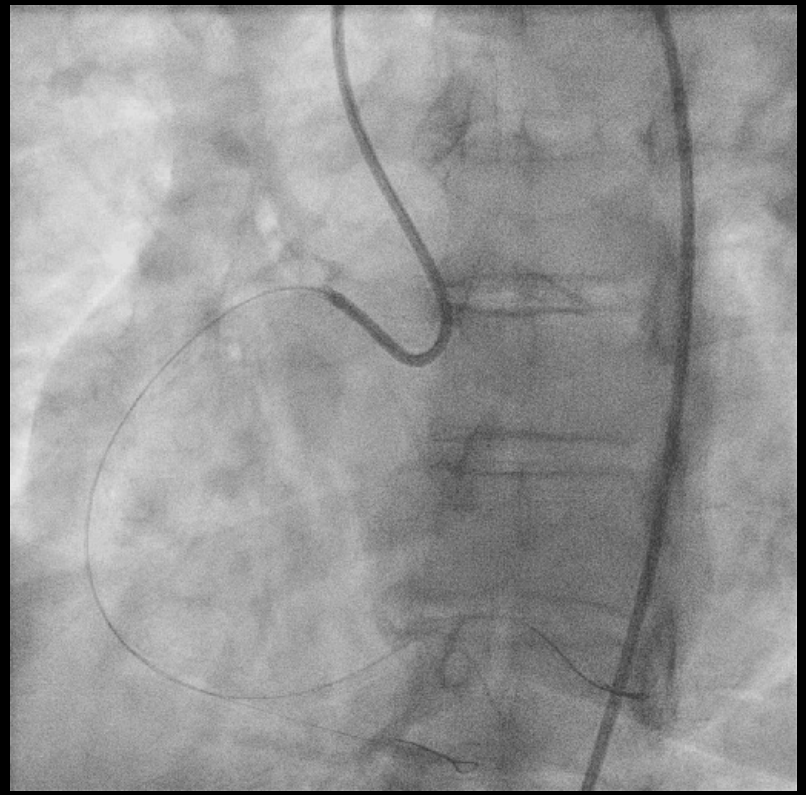

Aucune certitude

OFDI, Terumo®

Pullback sur 119 mm

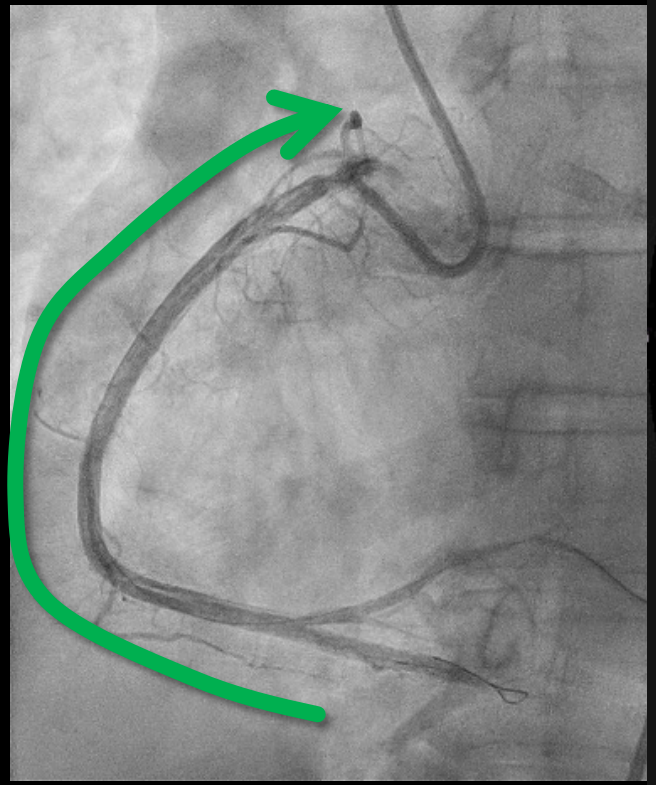

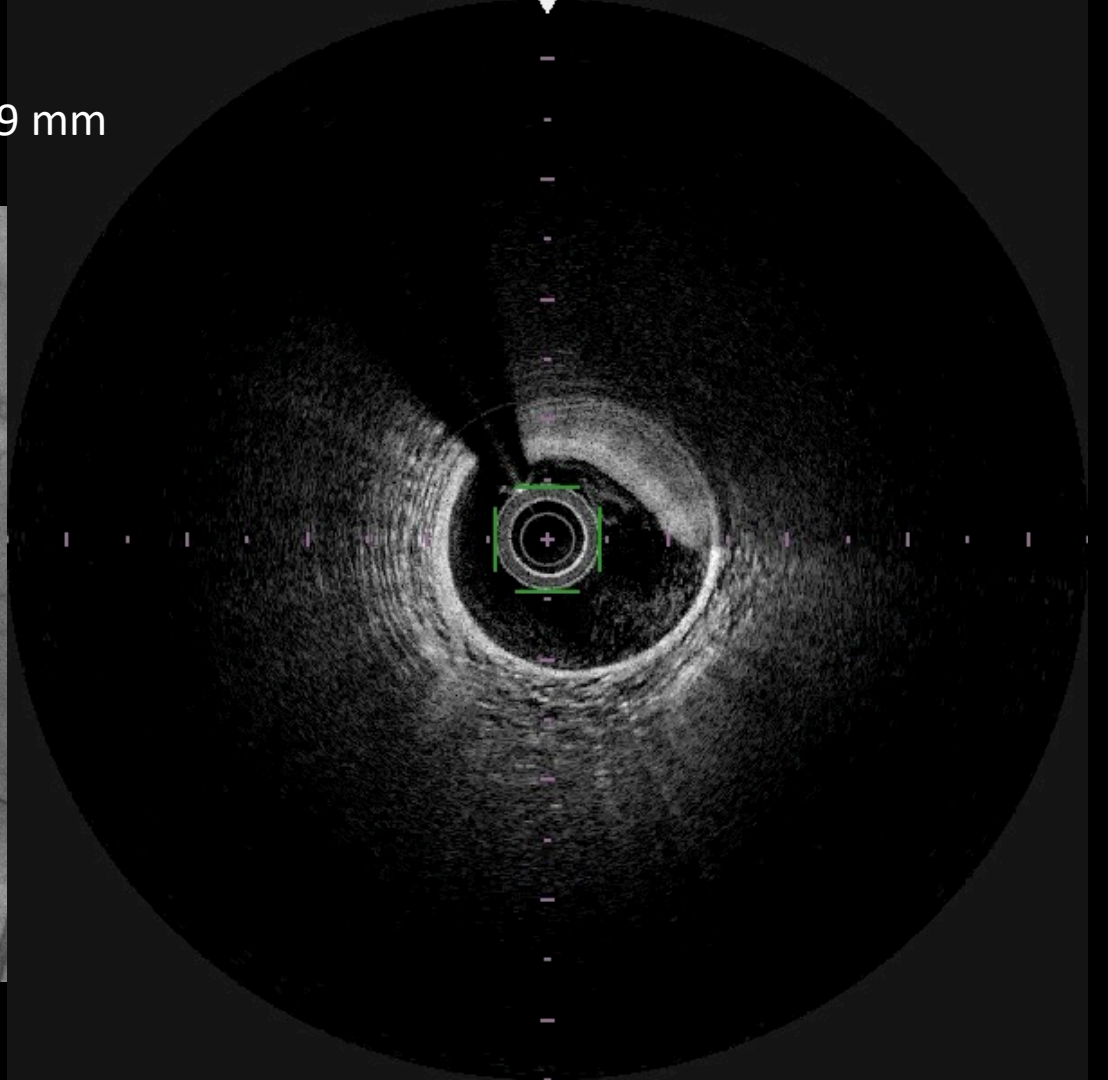

Nouvelle tentative avec guide « suspendu »

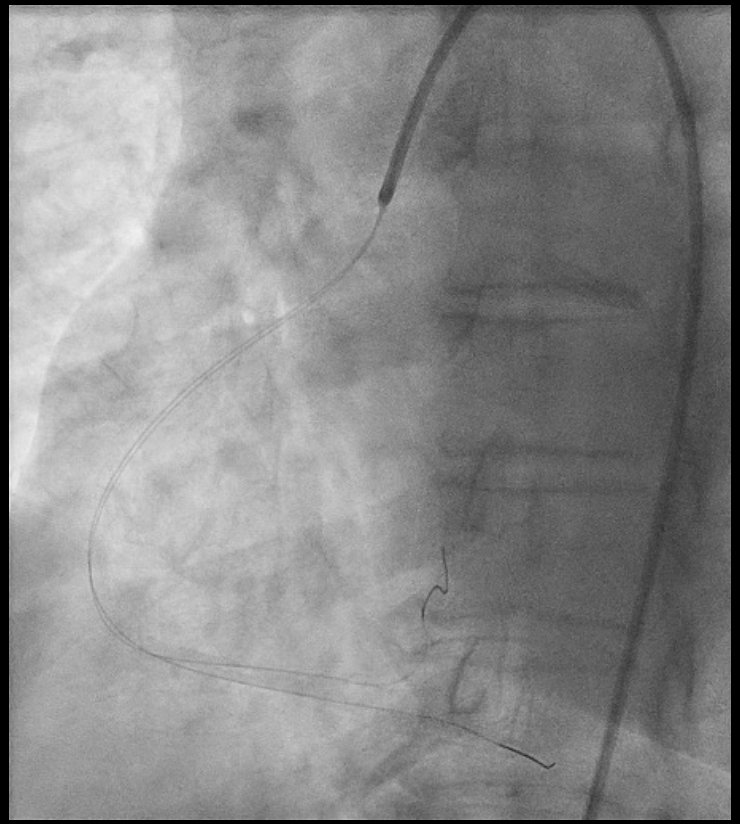

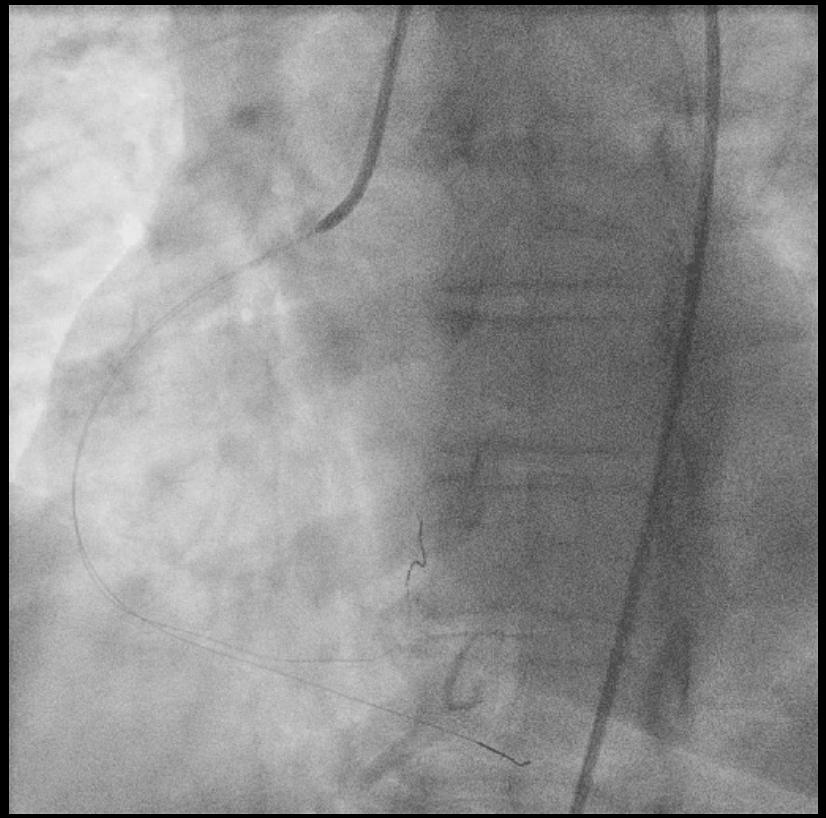

OFDI, Terumo®

Pullback sur 119 mm

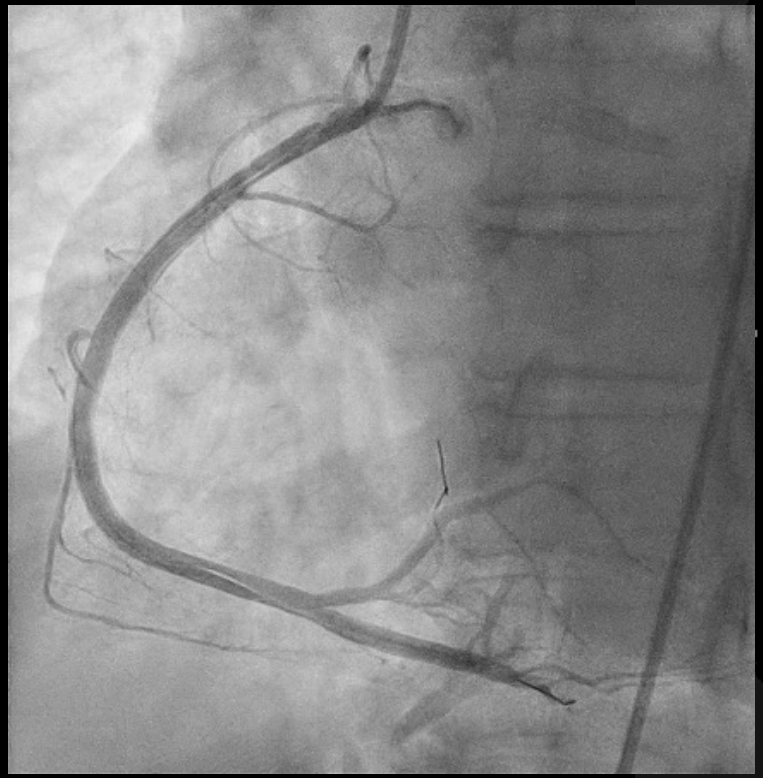

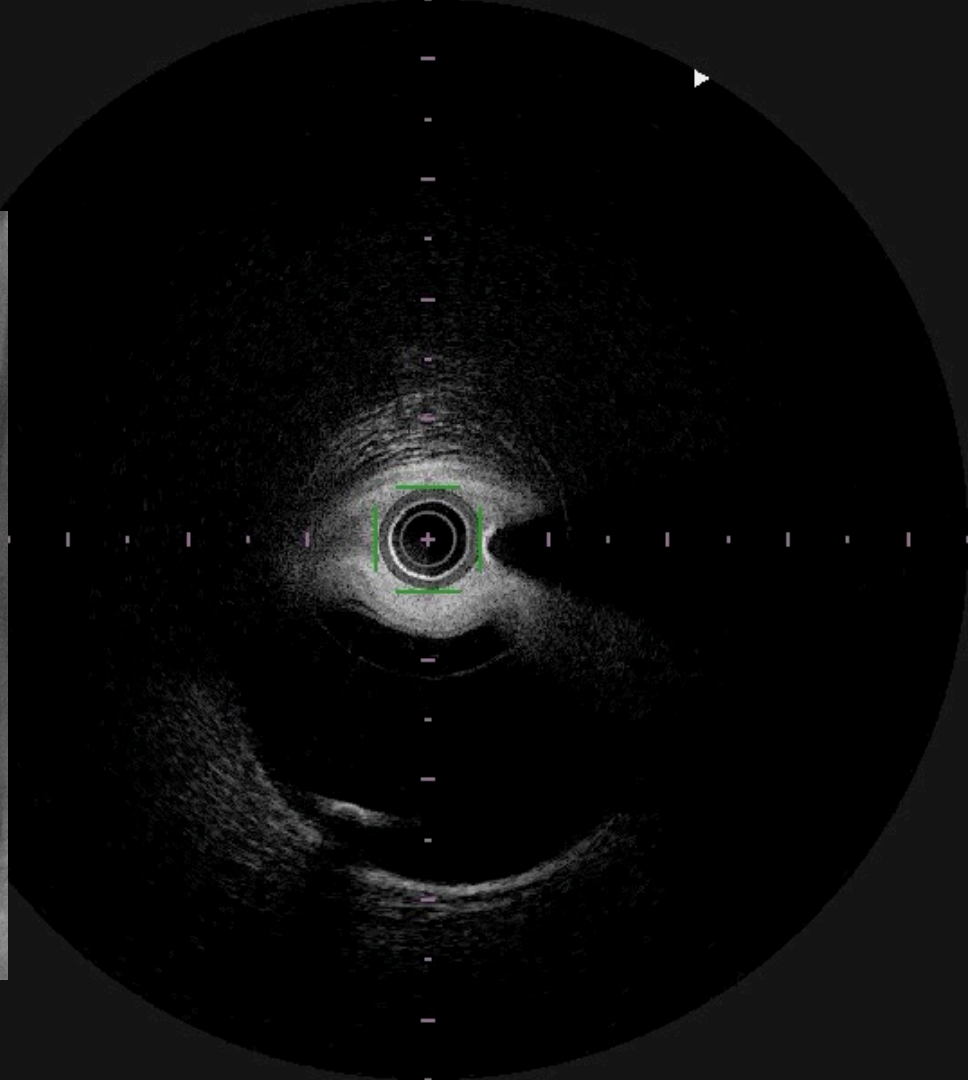

Stenting CD prox avec Synergy® 3.5 x 48mm

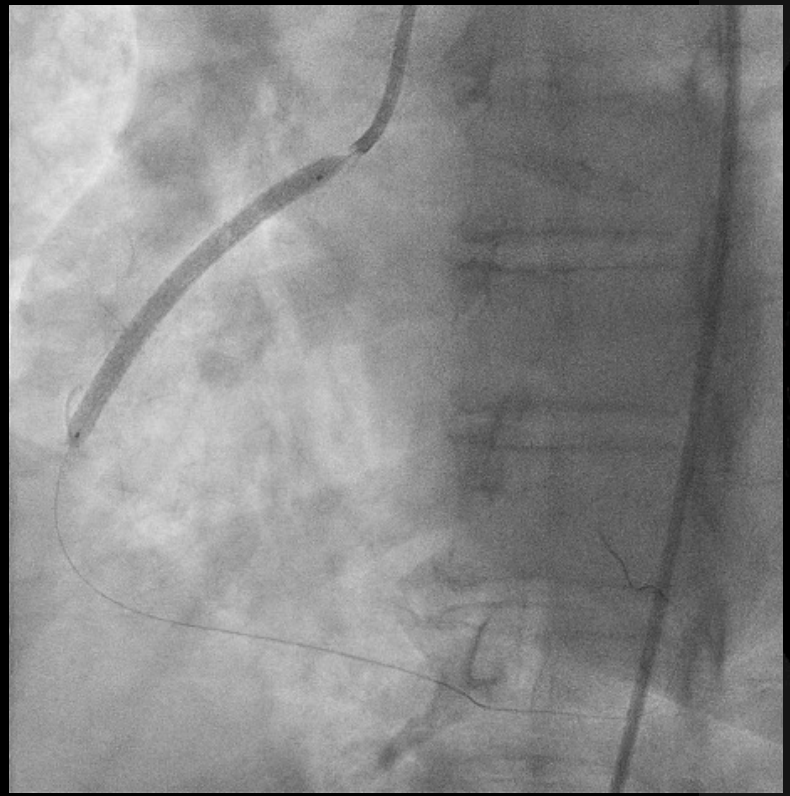

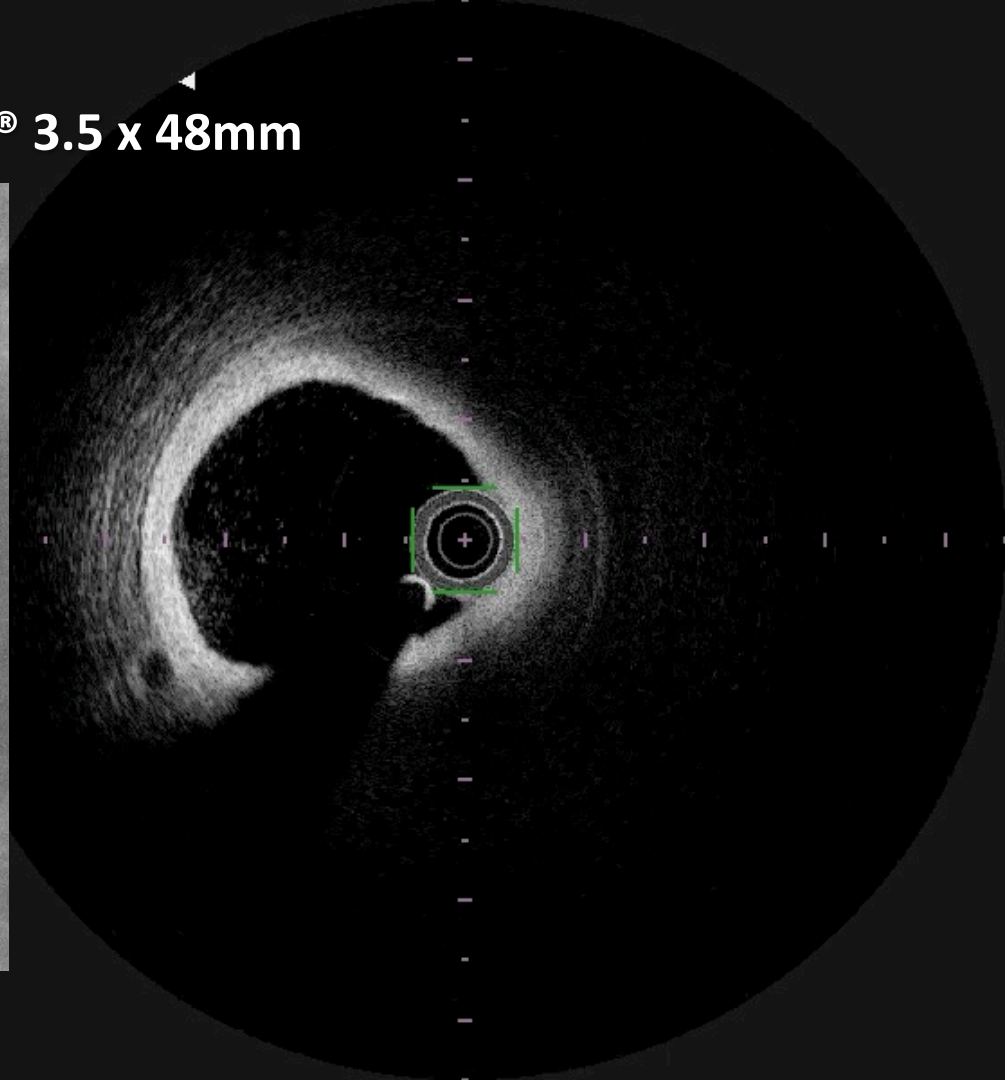

Post-dialtation, Overlapping avec Synergy® 4.0x12mm ostium

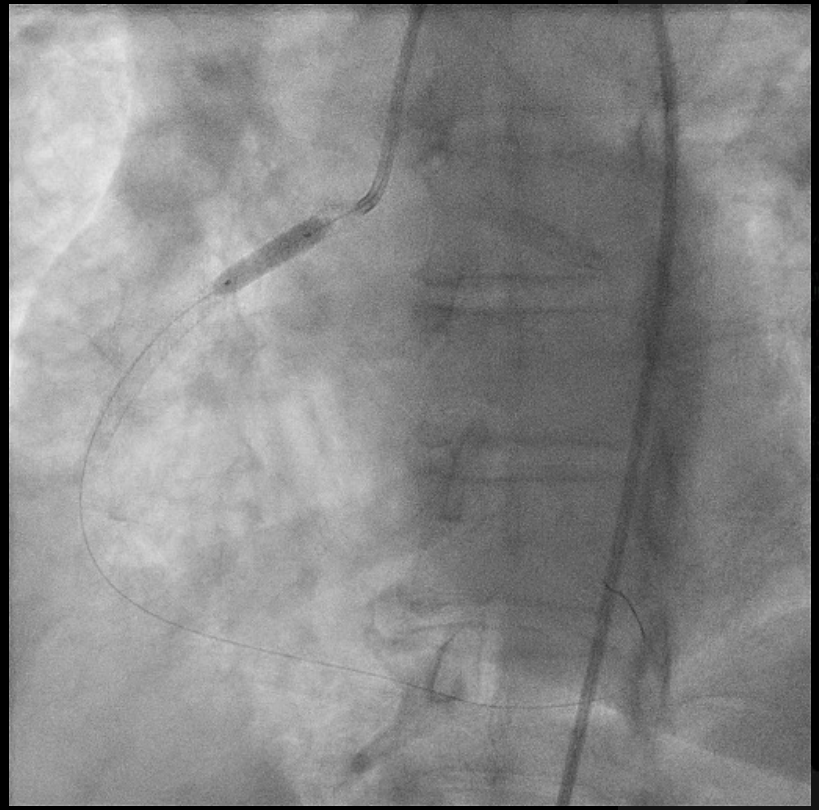

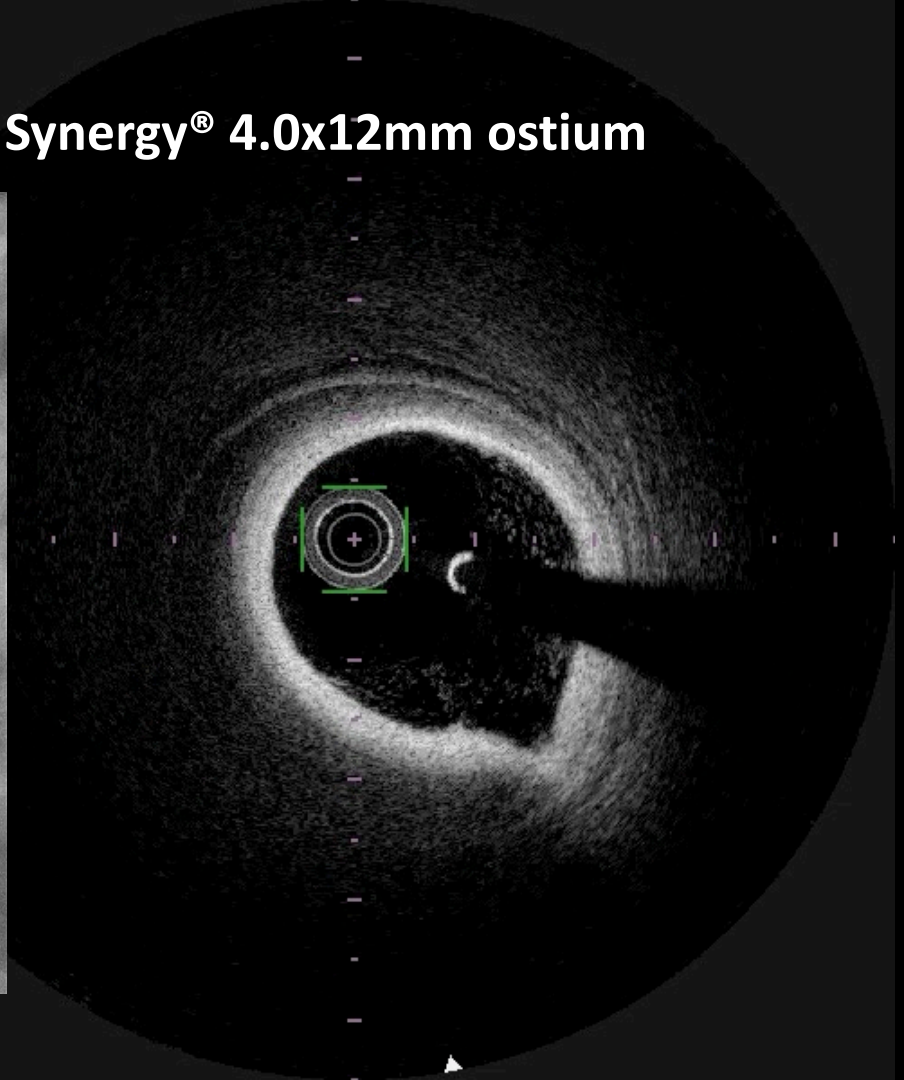

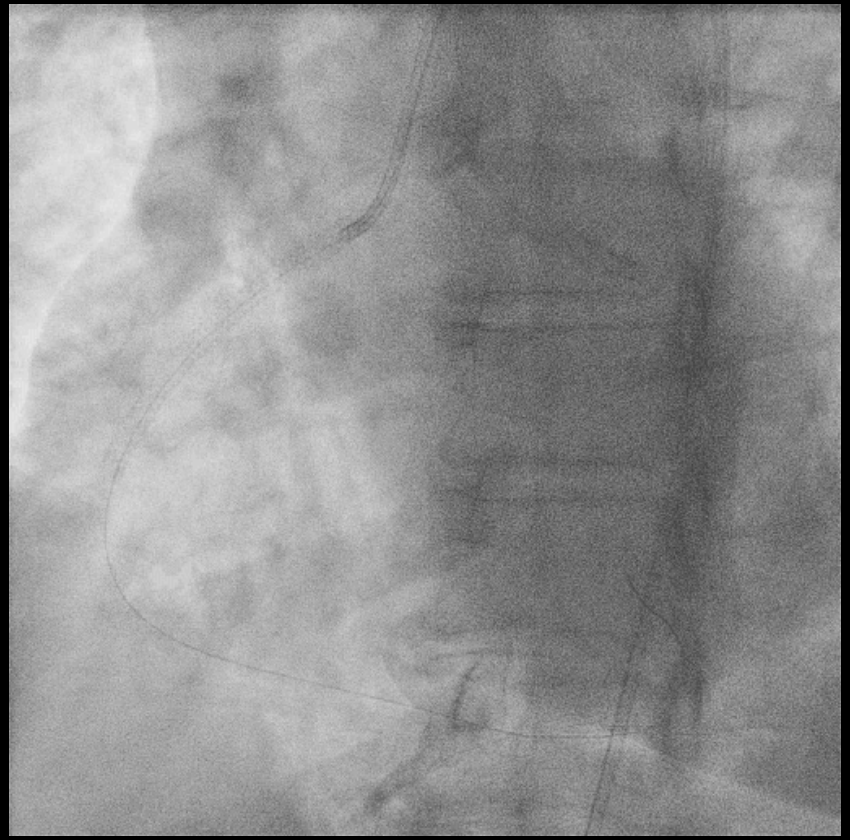

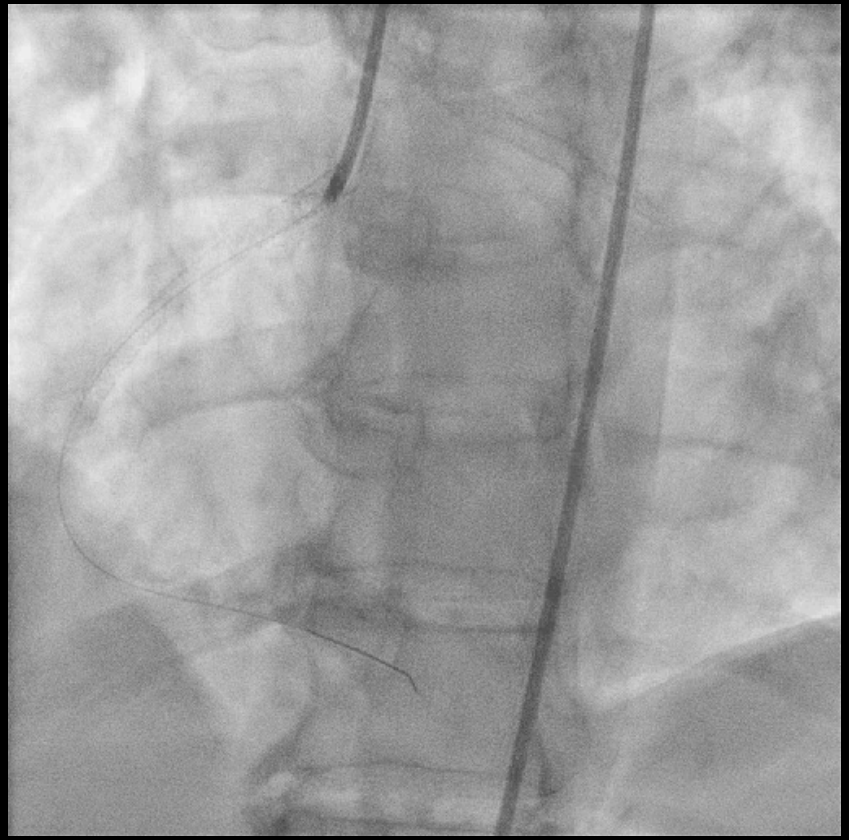

Résultat final

Sémiologie OFDI

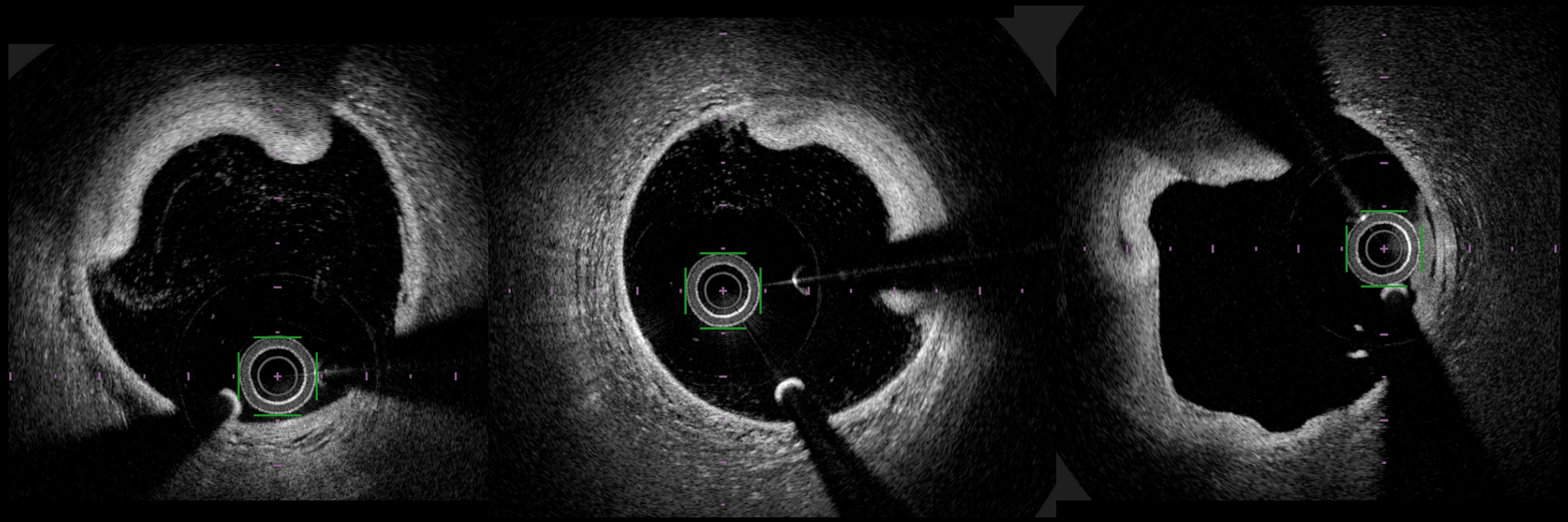

Deux guides dans fausse lumière

Sémiologie OFDI

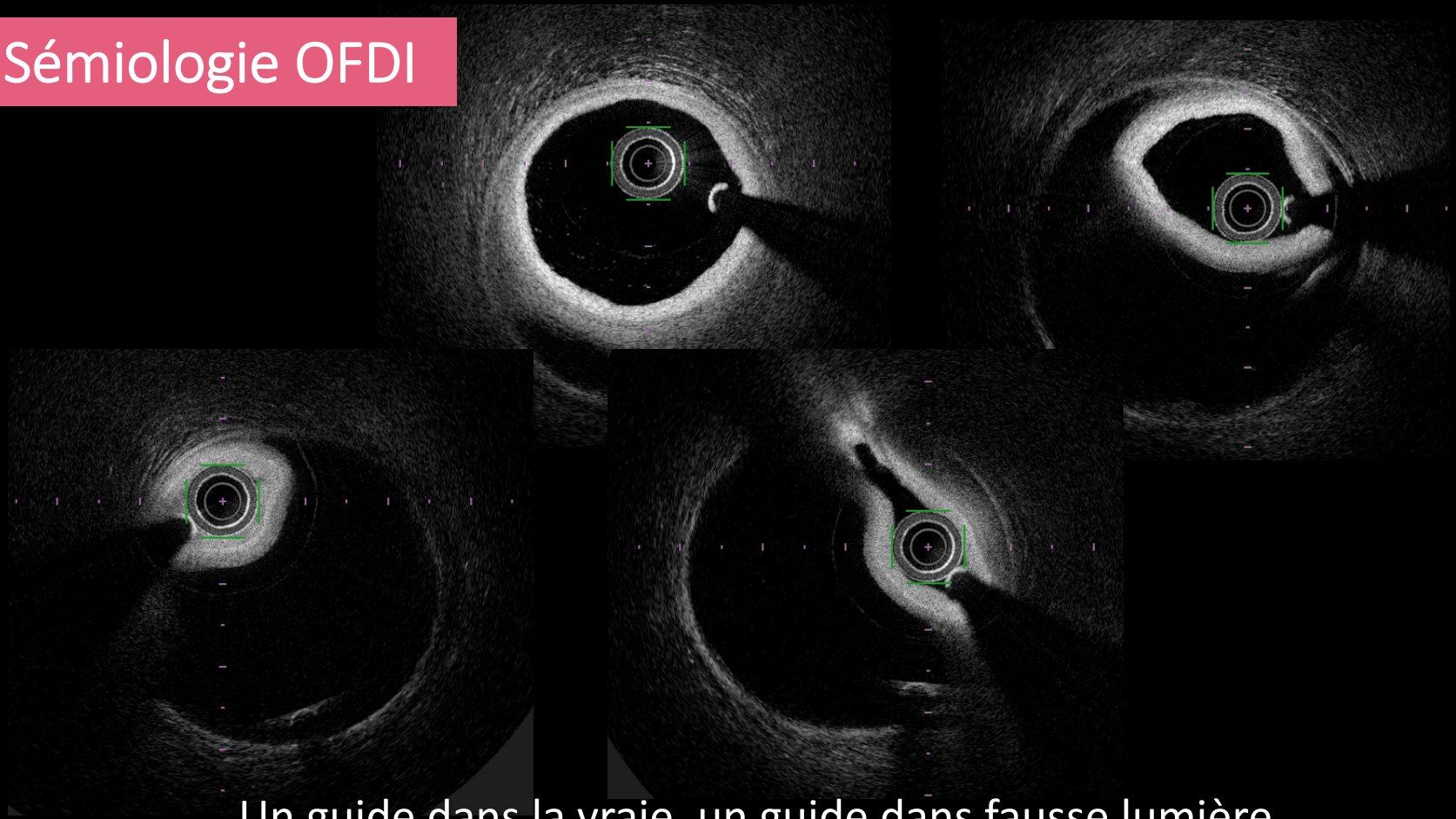

Un guide dans la vraie, un guide dans fausse lumière

Sémiologie OFDI



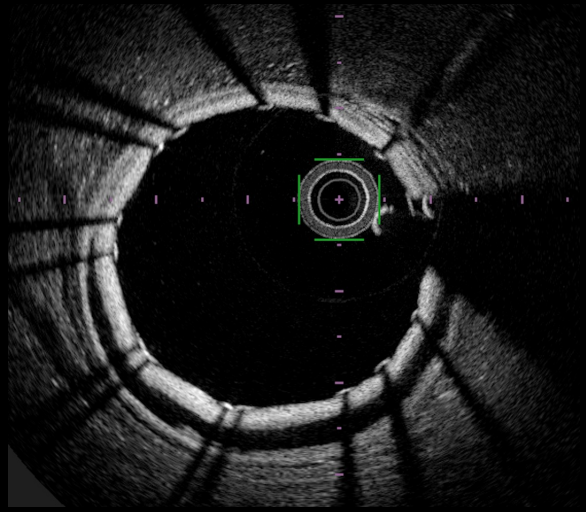

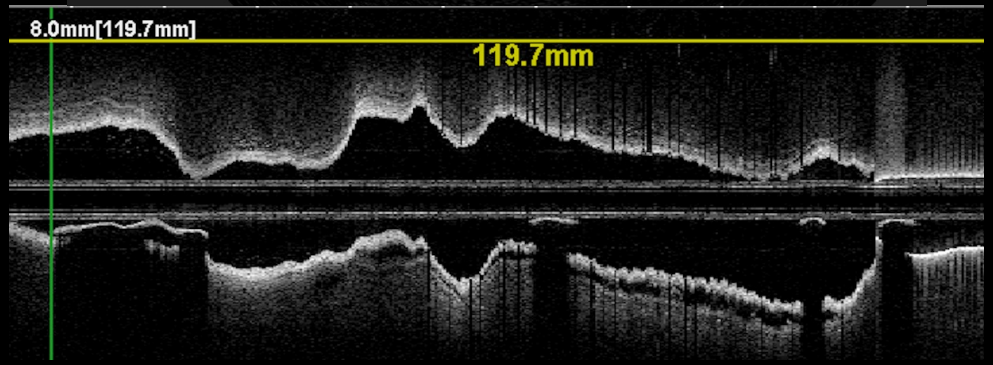



Mme Sophie. C, 55 ans

- Consultation Mai 2021 (à 9 mois)
- Evolution clinique excellente
- Dyspnée modérée, ECG normal, FEVG=60%
- Poursuite DAPT

Take home message

- Attention aux artères fragiles
- Dissection iatrogène redoutable
- Apport de l’imagerie pour éviter catastrophes

CLERMONT-FERRAND
CENTRE HOSPITALIER UNIVERSITAIRE

Mme D, âgée de 46 ans, admise pour NSTEMI

- 31 Décembre 2019, Hôpital Général Auvergnat
- Aucun ATCD médico-chirurgical
- Pas de FRCV

- Douleur thoracique prolongée, sus-décalage ST apical
- Coronarographie

CLERMONT-FERRAND
CENTRE HOSPITALIER UNIVERSITAIRE

Mme D, âgée de 46 ans, admise pour NSTEMI

31/12/2019

CLERMONT-FERRAND
CENTRE HOSPITALIER UNIVERSITAIRE

Mme D, âgée de 46 ans, admise pour NSTEMI

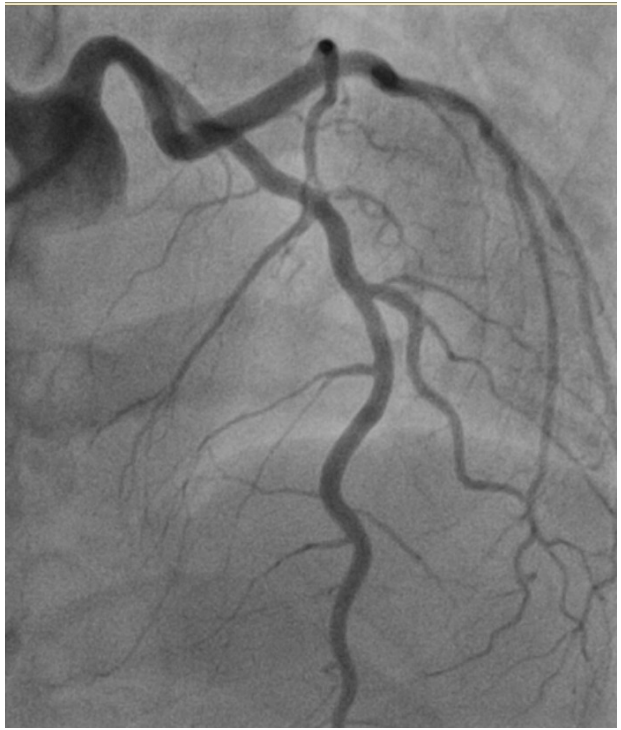

01/01/2020

CLERMONT-FERRAND
CENTRE HOSPITALIER UNIVERSITAIRE

Mme D, âgée de 46 ans, admise pour NSTEMI

- Récidives douloureuses subintrantes
- Adressée CHU Clermont pour imagerie +/- stenting
- Nouvelle Coro à J6

CLERMONT-FERRAND
CENTRE HOSPITALIER UNIVERSITAIRE

[redacted]
3059037
* 04/06/1974

06/01/2020
1 - 41/50

2.62 sec

H

AXIOM-Artis
R//////

R

512 x 512

RB 0%
DDO 50%

Coro +
A
D 196
LAO 28° / CAUD 28°

WC 1450 [C 127]
WW 2000 [W 255]

0.0 kV CARD
0.0 mA 15.0 l/s

A

Coro 7.5

Scopie - Card

Σ 000.0 min
0 mGy
0.00 µGym²

13%

00:00

Relecture

Sauvegarder référence

CLERMONT-FERRAND
CENTRE HOSPITALIER UNIVERSITAIRE

[redacted]
3059037
* 04/06/1974

06/01/2020
5 - 8/64

0.46 sec

H

AXIOM-Artis
R//////

R

0.0 kV CARD
0.0 mA 15.0 l/s

A

Coro 7.5

Scopie - Card

Σ 000.0 min
0 mGy
0.00 µGym²
11%

00:00

512 x 512

RB 0%
DDO 50%

Relecture

Coro +
A
D 197
RAO 5° / CRAN 34°

WC 1450 [C 127]
WW 2000 [W 255]

Sauvegarder référence

Hématome coronaire spontané
Extension de l'hématome?
Prise en charge?

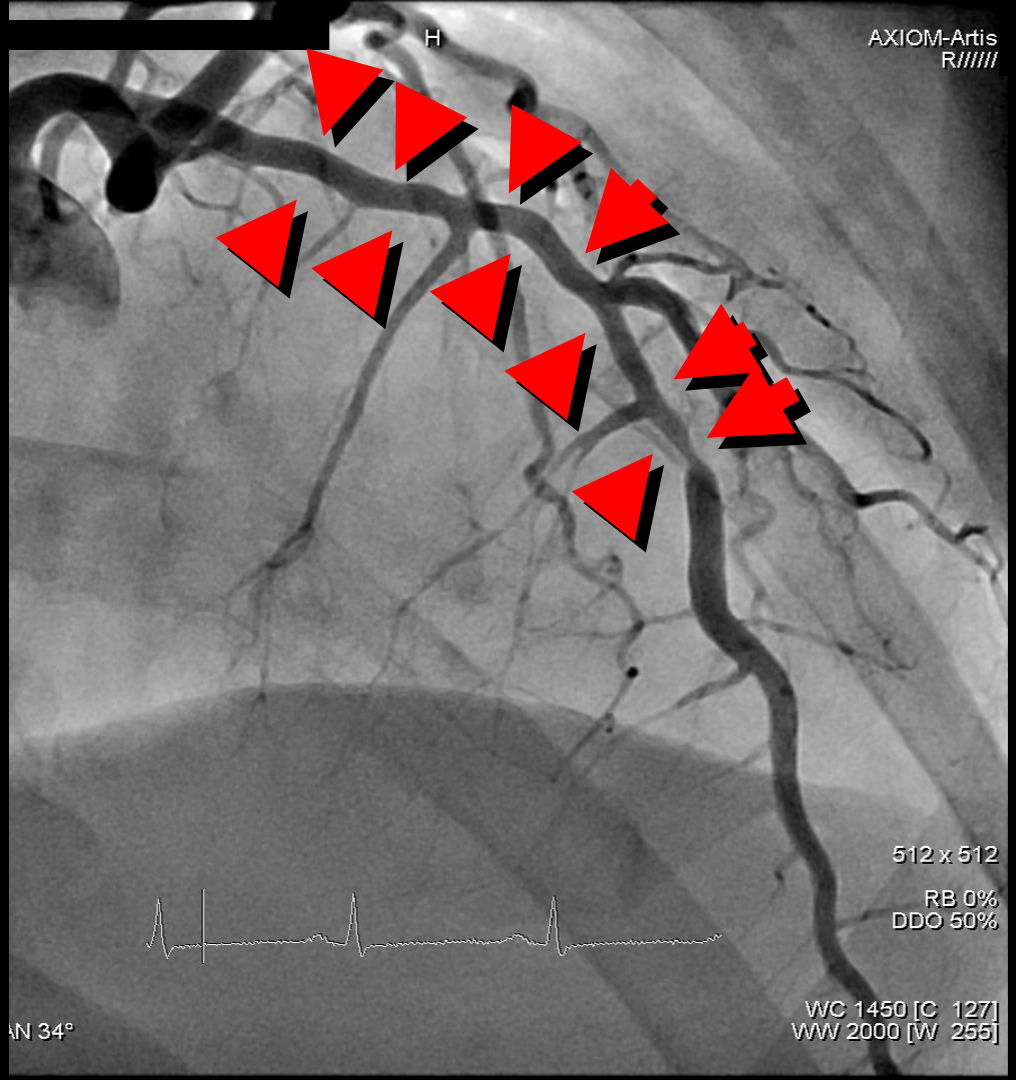

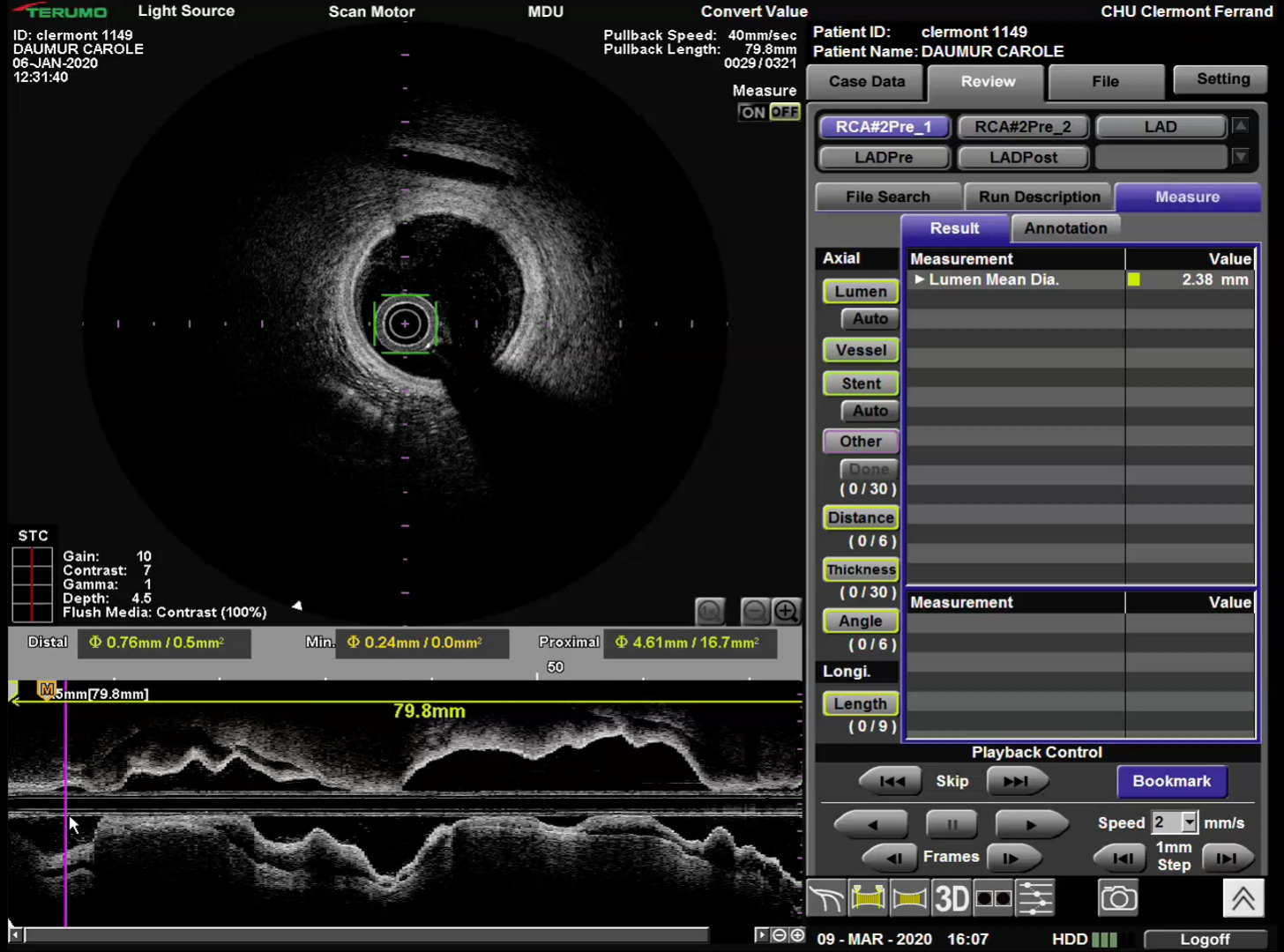
TERUMO
Light Source
Scan Motor
MDU
Convert Value
CHU Clermont Ferrand
ID: clermont 1149
DAUMUR CAROLE
06-JAN-2020
12:31:40
Pullback Speed: 40mm/sec
Pullback Length: 79.8mm
0029 / 0321
Patient ID: clermont 1149
Patient Name: DAUMUR CAROLE
Measure
ON OFF
Case Data
Review
File
Setting
RCA#2Pre_1
RCA#2Pre_2
LAD
LADPre
LADPost
File Search
Run Description
Measure
Result
Annotation
Axial
Lumen
Auto
Vessel
Stent
Auto
Other
Done
(0 / 30)
Distance
(0 / 6)
Thickness
(0 / 30)
Angle
(0 / 6)
Longi.
Length
(0 / 9)
Measurement
Value
Lumen Mean Dia.
2.38 mm
Measurement
Value
STC
Gain: 10
Contrast: 7
Gamma: 1
Depth: 4.5
Flush Media: Contrast (100%)
Distal
Φ 0.76mm / 0.5mm²
Min.
Φ 0.24mm / 0.0mm²
Proximal
Φ 4.61mm / 16.7mm²
50
M
5mm[79.8mm]
79.8mm
Playback Control
Skip
Bookmark
Speed 2 mm/s
Frames
1mm Step
3D
09 - MAR - 2020 16:07
HDD
Logoff

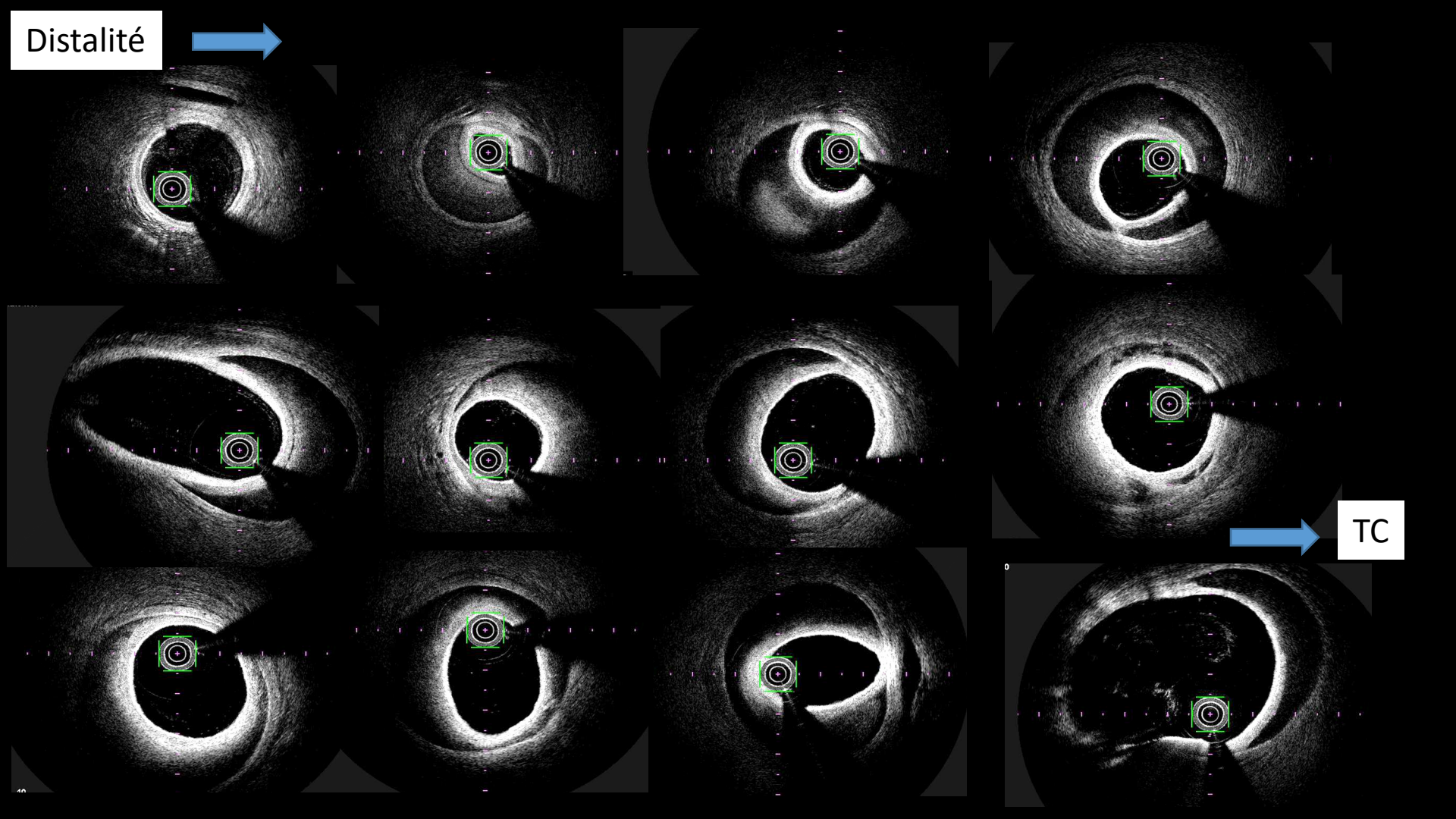
Distalité
TC

CLERMONT-FERRAND
CENTRE HOSPITALIER UNIVERSITAIRE

Patiente souffre
Instabilité clinique

Décision fenestration distale



Angiosculpt® Biotronik
3.0x15mm à 14 atm

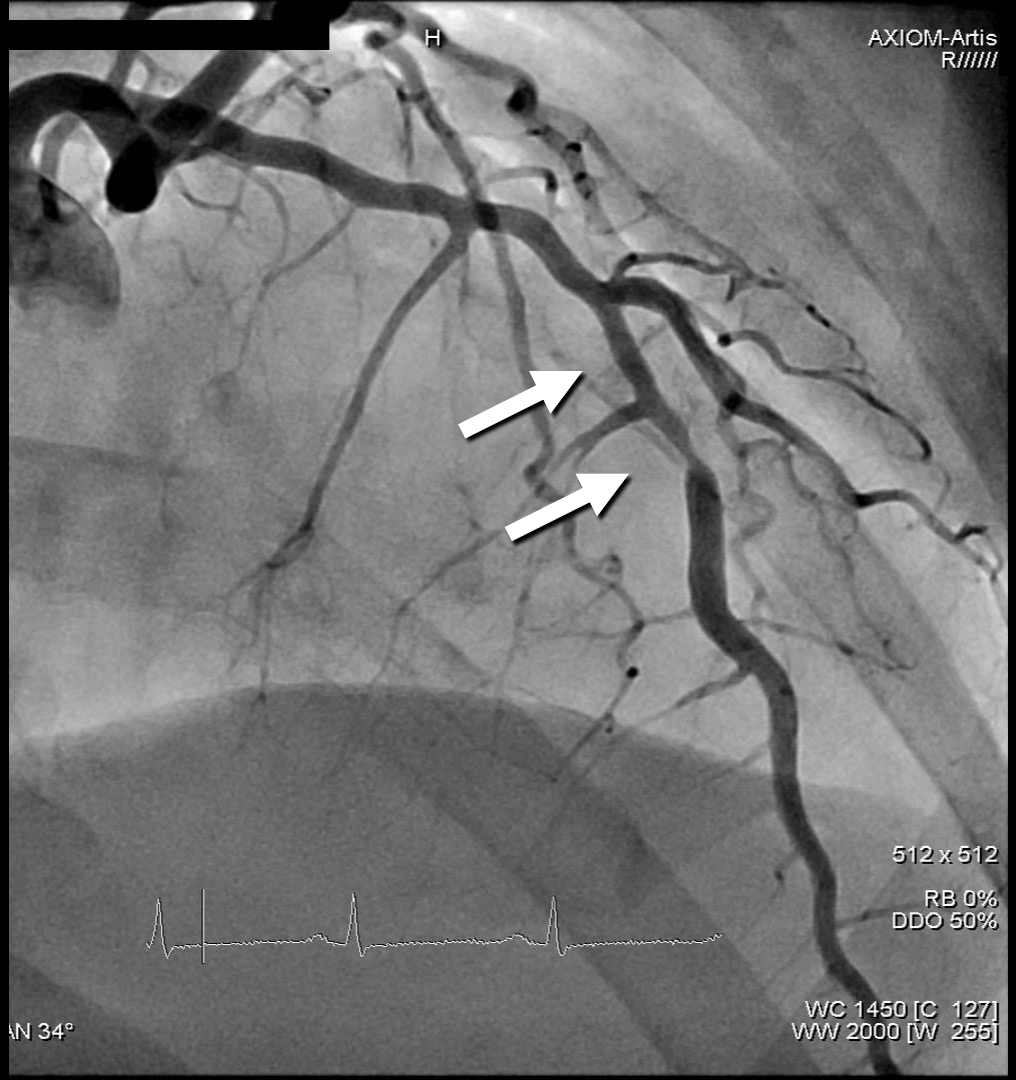

Fenestration distale

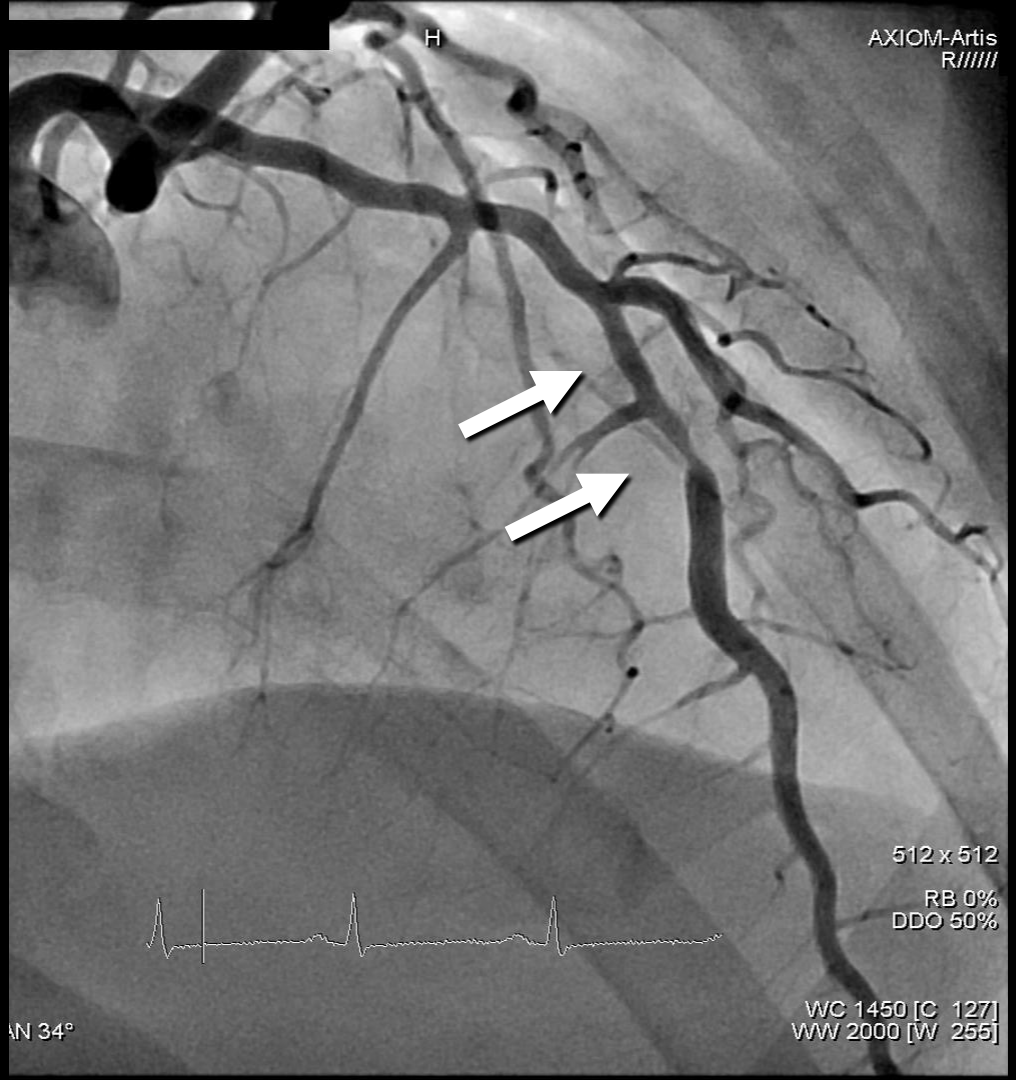

CLERMONT-FERRAND
CENTRE HOSPITALIER UNIVERSITAIRE

[redacted]
H
AXIOM-Artis
R//////

3059037
* 04/06/1974

06/01/2020
9 - 8/35

0.91 sec

R

0.0 kV CARD
0.0 mA 7.5 l/s
A
Coro 7.5

Scopie - Card

Σ 000.0 min
0 mGy
0.00 µGym²
10%
00:00

512 x 512

RB 0%
DDO 50%

Relecture

Coro 7.5
A
D 169
RAO 22° / CRAN 31°

WC 1450 [C 127]
WW 2000 [W 255]

Sauvegarder référence

CLERMONT-FERRAND
CENTRE HOSPITALIER UNIVERSITAIRE

Fenestrations étagées

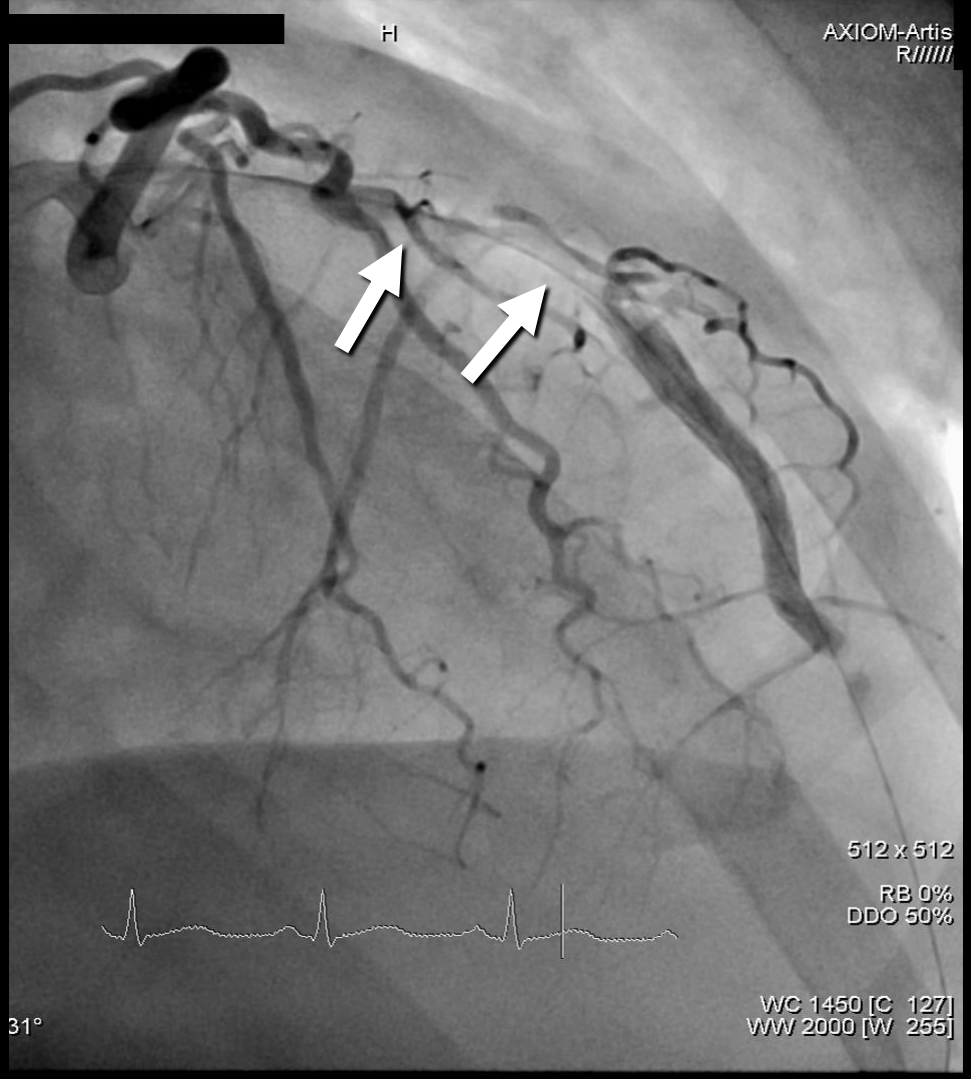

CLERMONT-FERRAND
CENTRE HOSPITALIER UNIVERSITAIRE

[redacted]
3059037
* 04/06/1974
06/01/2020
11 - 21/28
2.58 sec

H

AXIOM-Artis
R//////

R

0.0 kV CARD
0.0 mA 7.5 l/s
A
Coro 7.5
Scopie - Card
Σ 000.0 min
0 mGy
0.00 µGym²
9%
00:00

512 x 512
RB 0%
DDO 50%

Relecture

Coro 7.5
A
D 167
RAO 22° / CRAN 31°

WC 1450 [C 127]
WW 2000 [W 255]

Sauvegarder référence

CLERMONT-FERRAND
CENTRE HOSPITALIER UNIVERSITAIRE

Fenestrations étagées

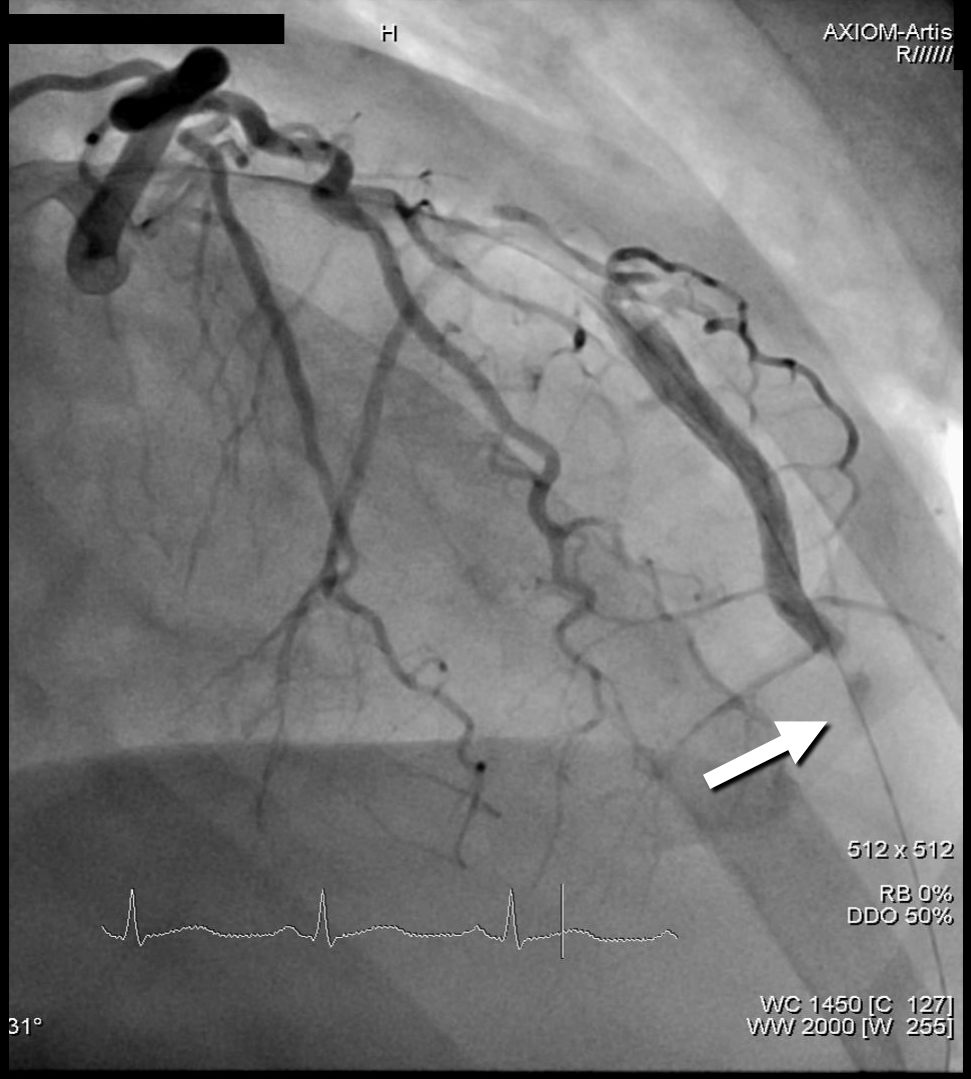

CLERMONT-FERRAND
CENTRE HOSPITALIER UNIVERSITAIRE

[redacted]
3059037
* 04/06/1974

06/01/2020
12 - 12/37

1.43 sec

H

AXIOM-Artis
R//////

R

0.0 kV CARD
0.0 mA 7.5 l/s

A

Coro 7.5

Scopie - Card

Σ 000.0 min
0 mGy
0.00 µGym²

8%

00:00

512 x 512

RB 0%
DDO 50%

Relecture

Coro 7.5
A
D 171
RAO 22° / CRAN 31°

WC 1450 [C 127]
WW 2000 [W 255]

Sauvegarder référence

CLERMONT-FERRAND
CENTRE HOSPITALIER UNIVERSITAIRE

[redacted]
3059037
* 04/06/1974

06/01/2020
13 - 12/25

1.41 sec

H

AXIOM-Artis
R//////

R

512 x 512

RB 0%
DDO 50%

Coro 7.5
A
D 166
RAO 12° / CAUD 25°

WC 1450 [C 127]
WW 2000 [W 255]

0.0 kV CARD
0.0 mA 7.5 l/s

A

Coro 7.5

Scopie - Card

Σ 000.0 min
0 mGy
0.00 µGym²

8%

00:00

Relecture

Sauvegarder référence

CLERMONT-FERRAND
CENTRE HOSPITALIER UNIVERSITAIRE

Stenting IVA proximale
Protection Cx

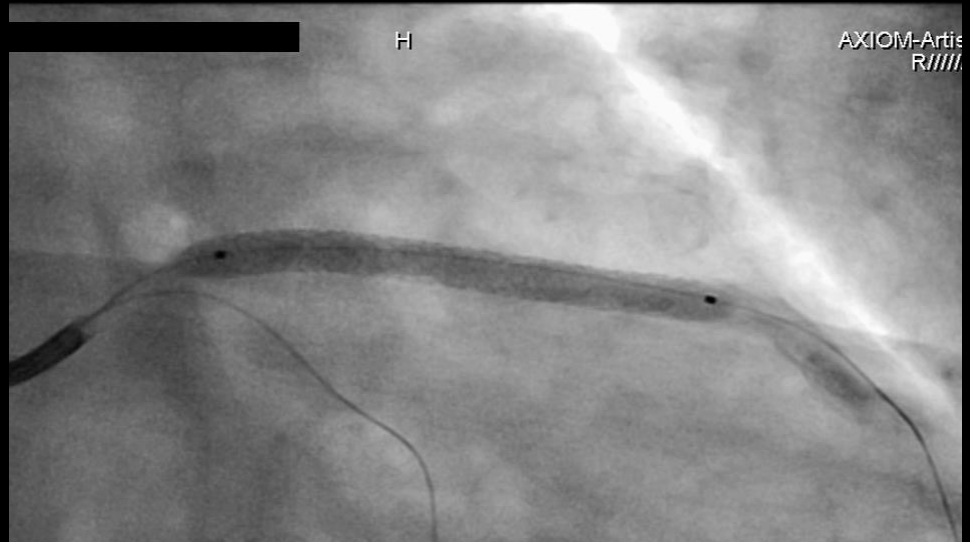

CLERMONT-FERRAND
CENTRE HOSPITALIER UNIVERSITAIRE

[redacted]
3059037
* 04/06/1974

06/01/2020
15 - 2/27

0.13 sec

H

AXIOM-Artis
R//////

R

512 x 512

RB 0%
DDO 50%

Coro 7.5
A
D 168
RAO 12° / CAUD 25°

WC 1450 [C 127]
WW 2000 [W 255]

0.0 kV CARD
0.0 mA 7.5 l/s

A

Coro 7.5

Scopie - Card

Σ 000.0 min
0 mGy
0.00 µGym²

7%

00:00

Relecture

Sauvegarder référence

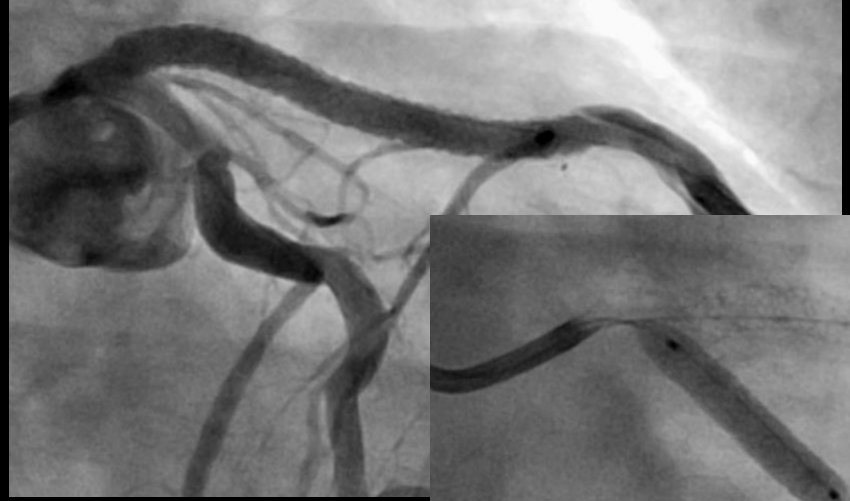

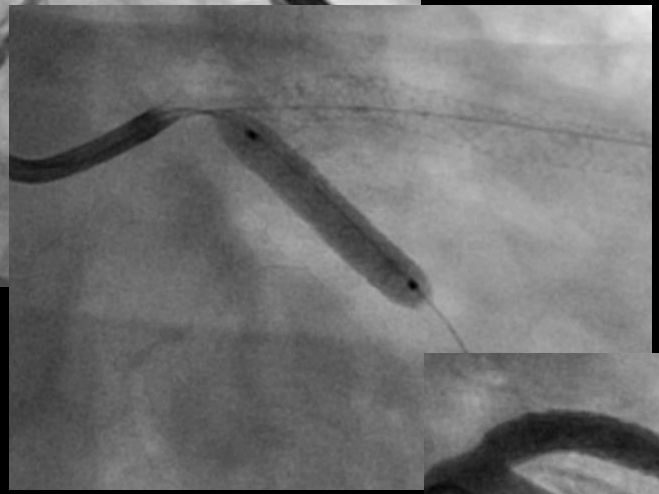

Hématome Cx

Stenting Cx

CLERMONT-FERRAND
CENTRE HOSPITALIER UNIVERSITAIRE

[redacted]
3059037
* 04/06/1974

06/01/2020
20 - 11/25

1.28 sec

H

AXIOM-Artis
R//////

R

512 x 512

RB 0%
DDO 50%

Coro 7.5
A
D 169
RAO 10° / CAUD 25°

WC 1450 [C 127]
WW 2000 [W 255]

0.0 kV CARD
0.0 mA 7.5 l/s

A

Coro 7.5

Scopie - Card

Σ 000.0 min
0 mGy
0.00 µGym²

6%

00:00

Relecture

Sauvegarder référence

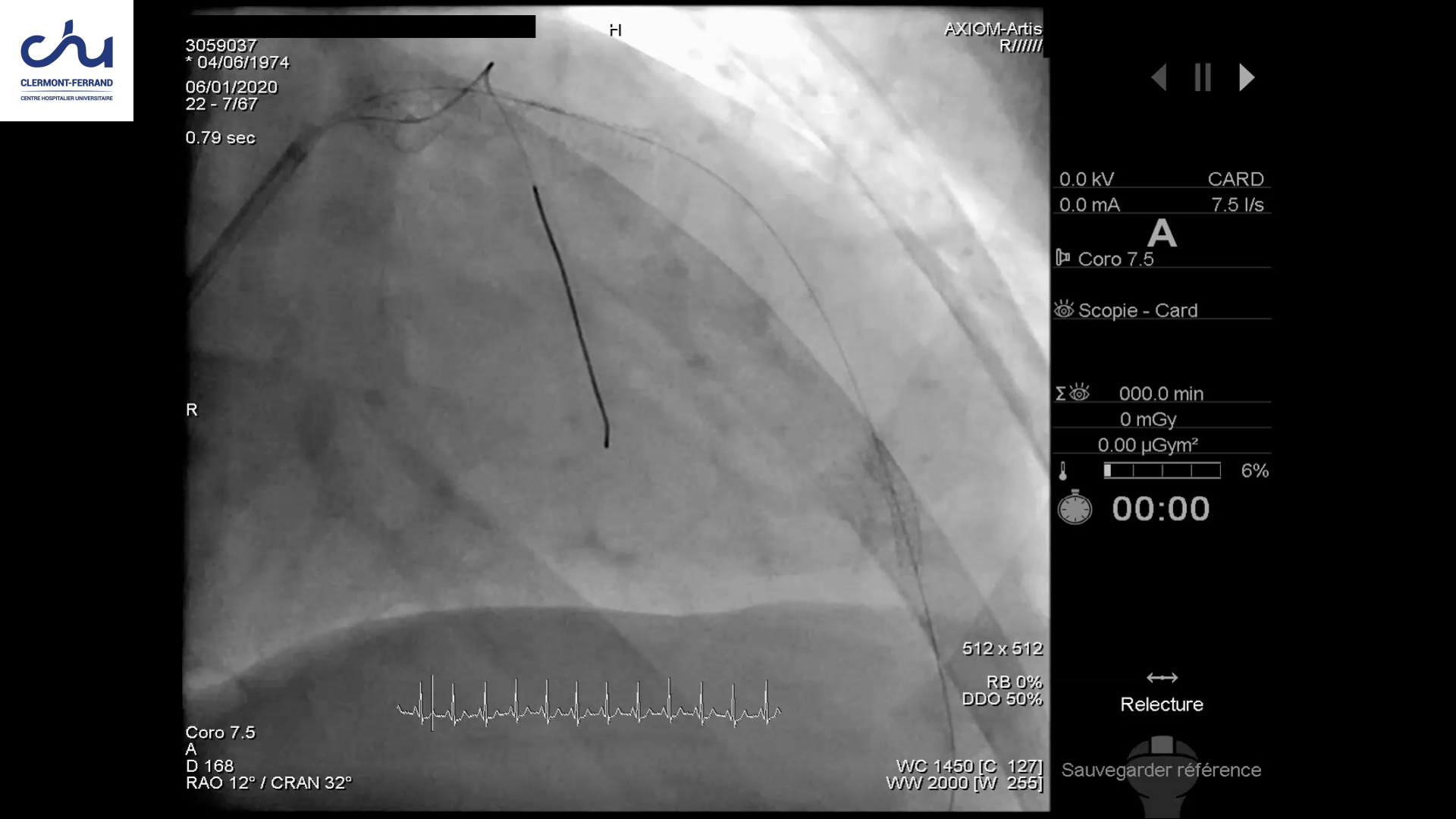
CLERMONT-FERRAND
CENTRE HOSPITALIER UNIVERSITAIRE
[redacted]
H
AXIOM-Artis
R//////
3059037
* 04/06/1974
06/01/2020
22 - 7/67
0.79 sec
R
0.0 kV
CARD
0.0 mA
7.5 l/s
A
Coro 7.5
Scopie - Card
000.0 min
0 mGy
0.00 µGym²
6%
00:00
512 x 512
RB 0%
DDO 50%
Relecture
Coro 7.5
A
D 168
RAO 12° / CRAN 32°
WC 1450 [C 127]
WW 2000 [W 255]
Sauvegarder référence

CLERMONT-FERRAND
CENTRE HOSPITALIER UNIVERSITAIRE

[redacted]
3059037
* 04/06/1974
06/01/2020
23 - 18/76
2.24 sec

H

AXIOM-Artis
R//////

R

0.0 kV CARD
0.0 mA 7.5 l/s
A
Coro 7.5
Scopie - Card
Σ 000.0 min
0 mGy
0.00 µGym²
5%
00:00

512 x 512
RB 0%
DDO 50%

Relecture

Coro 7.5
A
D 168
RAO 12° / CRAN 32°

WC 1450 [C 127]
WW 2000 [W 255]

Sauvegarder référence

CLERMONT-FERRAND
CENTRE HOSPITALIER UNIVERSITAIRE

Mme D, âgée de 46 ans

- Bonne évolution
- FEVG=55%
- Récidives douloureuses
- Contrôle à J4

CLERMONT-FERRAND
CENTRE HOSPITALIER UNIVERSITAIRE

[redacted]
3059037
* 04/06/1974

10/01/2020
5 - 11/49

1.31 sec

H

AXIOM-Artis
R//////

R

0.0 kV CARD
0.0 mA 7.5 l/s

A

Coro 7.5

Scopie - Card

Σ 000.0 min
0 mGy
0.00 µGym²

4%

00:00

512 x 512

RB 0%
DDO 50%

Relecture

Coro 7.5
A
D 167
RAO 10° / CAUD 25°

WC 1450 [C 127]
WW 2000 [W 255]

Sauvegarder référence

CLERMONT-FERRAND
CENTRE HOSPITALIER UNIVERSITAIRE

[redacted]
3059037
* 04/06/1974
10/01/2020
6 - 25/73
1.58 sec

H

AXIOM-Artis
R//////

R

0.0 kV CARD
0.0 mA 15.0 l/s
A
Coro 7.5
Scopie - Card
Σ 000.0 min
0 mGy
0.00 µGym²
4%
00:00

512 x 512
RB 0%
DDO 50%

Relecture

Coro 7.5
A
D 170
RAO 13° / CRAN 25°

WC 1450 [C 127]
WW 2000 [W 255]

Sauvegarder référence

CLERMONT-FERRAND
CENTRE HOSPITALIER UNIVERSITAIRE

[redacted]
3059037
* 04/06/1974

10/01/2020
4 - 26/32

3.24 sec

H

AXIOM-Artis
R//////

R

512 x 512

RB 0%
DDO 50%

Coro 7.5
A
D 167
LAO 26° / CAUD 31°

WC 1450 [C 127]
WW 2000 [W 255]

0.0 kV CARD
0.0 mA 7.5 l/s

A

Coro 7.5

Scopie - Card

Σ 000.0 min
0 mGy
0.00 µGym²

4%

00:00

Relecture

Sauvegarder référence

CLERMONT-FERRAND
CENTRE HOSPITALIER UNIVERSITAIRE

TERUMO | Light Source | Scan Motor | MDU | Convert Value | CHU Clermont Ferrand

ID: clermont 1151
DAUMUR Carole
10-JAN-2020
11:38:19

Pullback Speed: 40mm/sec
Pullback Length: 119.8mm
0033 / 0478

Measure
ON OFF

Patient ID: clermont 1151
Patient Name: DAUMUR Carole

Case Data | Review | File | Setting

RCA#2Pre_1 | RCA#2Pre_2 | LAD
LADPre | LADPost

File Search | Run Description | Measure

Run Description

Target Lesion: LAD | LCX | RCA | LMT | Other
Segment
Pre/Post: Pre | Post
Run No.
Comments

LAD | OK

STC
Gain: 10
Contrast: 7
Gamma: 1
Depth: 4.5
Flush Media: Contrast (100%)

Distal Φ 1.01mm / 0.8mm² | Min. Φ 0.28mm / 0.1mm² | Proximal Φ 1.75mm / 2.4mm²

50 | 100

6.6mm[119.8mm]
119.8mm

Playback Control

Skip | Bookmark
Speed 2 mm/s
Frames | 1mm Step

3D

09 - MAR - 2020 15:57 HDD Logoff

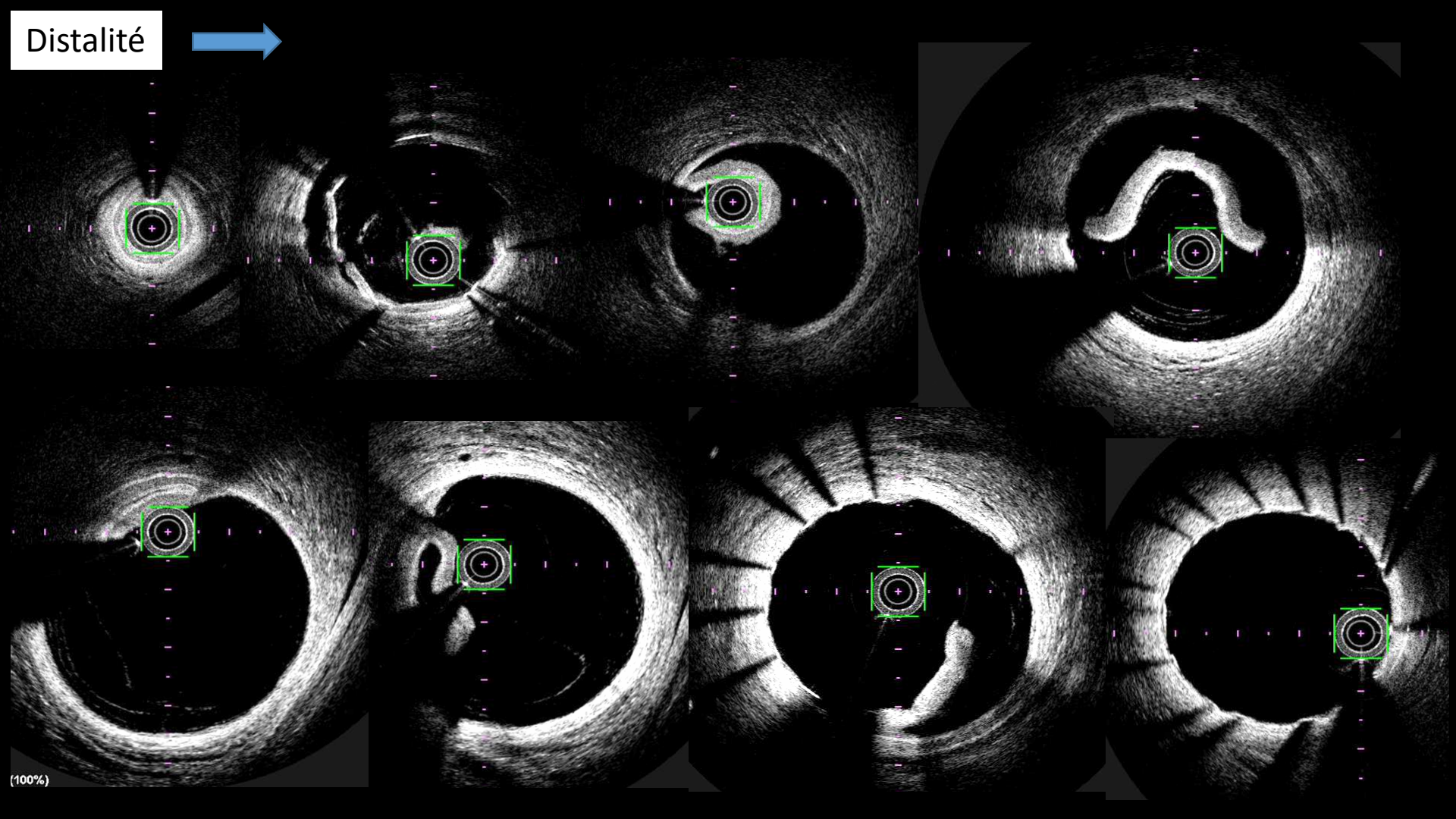
Distalité
(100%)

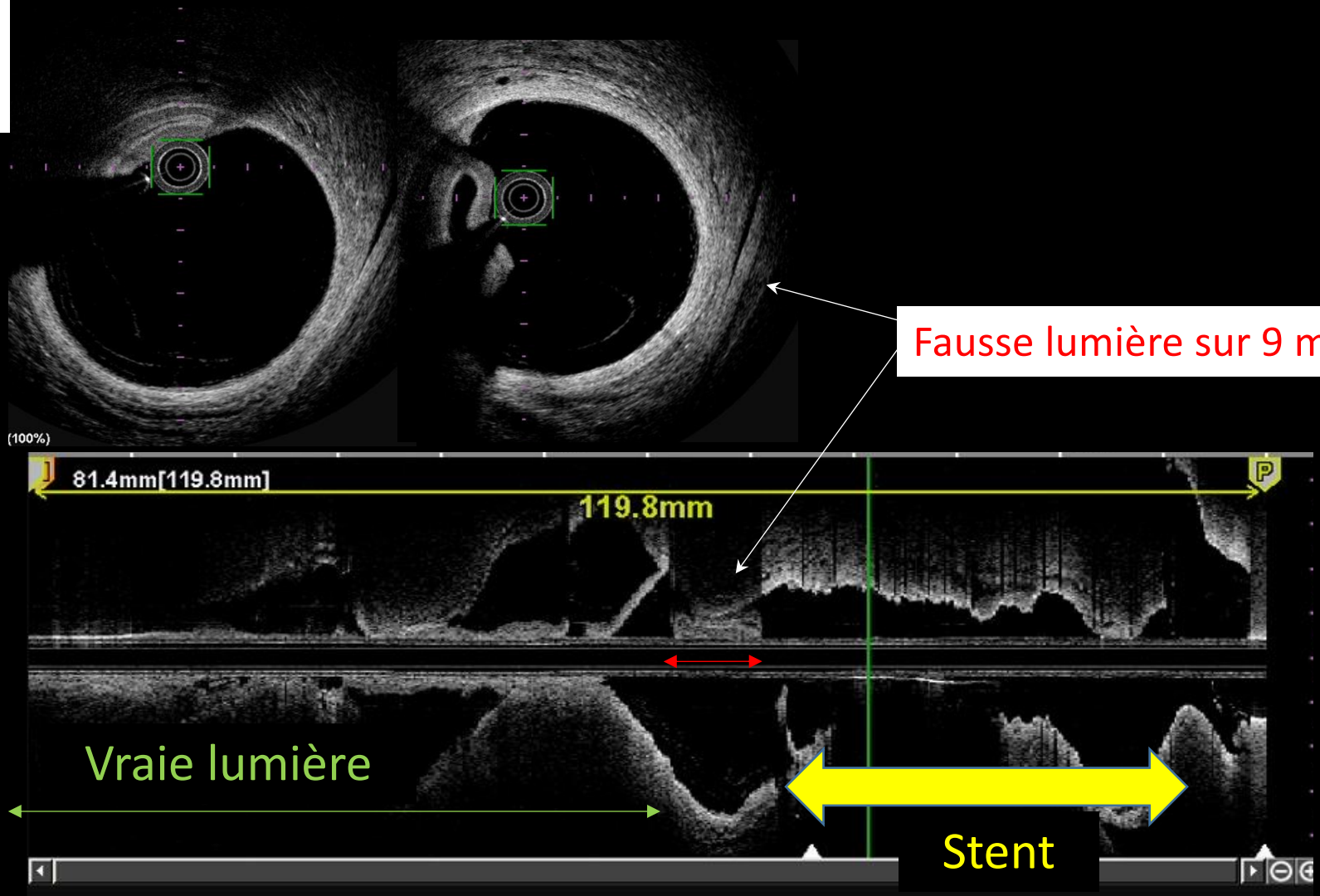
(100%)
81.4mm[119.8mm]
119.8mm
Fausse lumière sur 9 mm
Vraie lumière
Stent

CLERMONT-FERRAND
CENTRE HOSPITALIER UNIVERSITAIRE

Stenting IVA moyenne POT

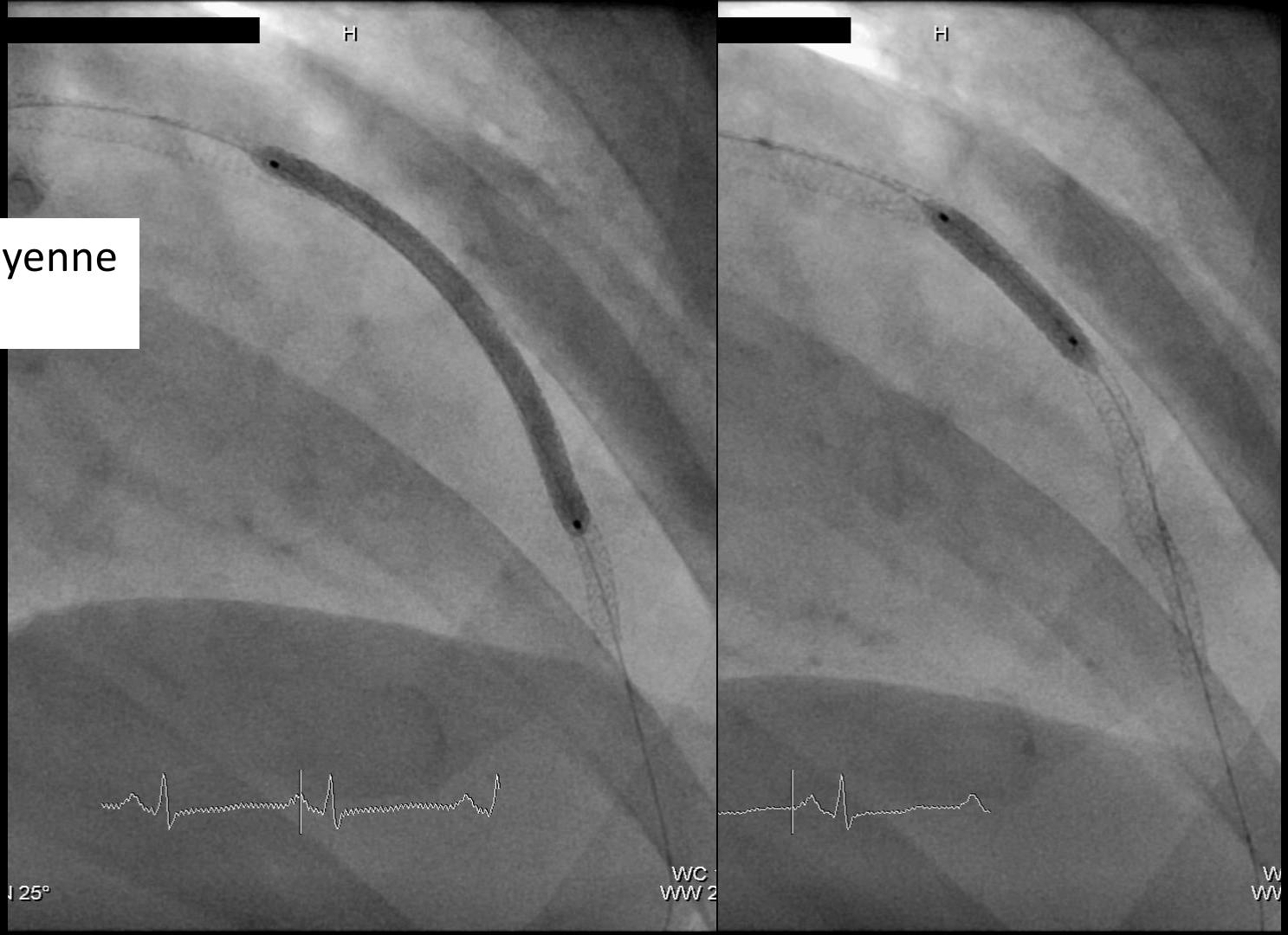

CLERMONT-FERRAND
CENTRE HOSPITALIER UNIVERSITAIRE

[redacted]
3059037
* 04/06/1974
10/01/2020
11 - 36/59
2.30 sec

H

AXIOM-Artis
R//////

R

0.0 kV FL
0.0 mA 15.0 l/s
A
Coro 7.5
Scopie - Card
0 1.0
Gy
000.0 min
0 mGy
0.00 µGym²
3%
00:00

512 x 512
RB 0%
DDO 50%

Relecture

Coro 7.5
A
D 169
RAO 13° / CRAN 25°

WC 1450 [C 127]
WW 2000 [W 255]

Sauvegarder référence

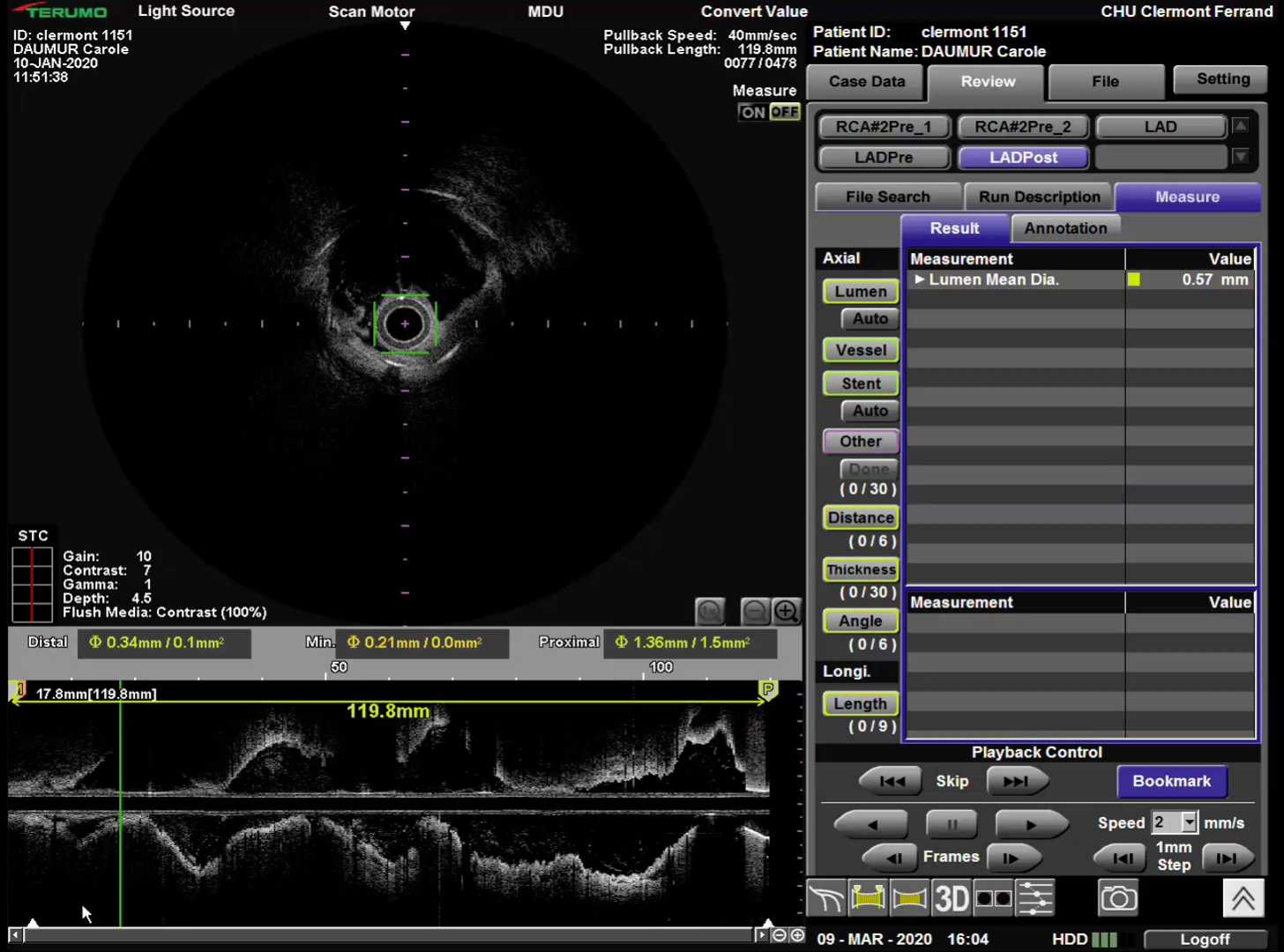
TERUMO
Light Source
Scan Motor
MDU
Convert Value
CHU Clermont Ferrand
ID: clermont 1151
DAUMUR Carole
10-JAN-2020
11:51:38
Pullback Speed: 40mm/sec
Pullback Length: 119.8mm
0077 / 0478
Patient ID: clermont 1151
Patient Name: DAUMUR Carole
Measure
ON OFF
Case Data
Review
File
Setting
RCA#2Pre_1
RCA#2Pre_2
LAD
LADPre
LADPost
File Search
Run Description
Measure
Result
Annotation
Axial
Lumen
Auto
Vessel
Stent
Auto
Other
Done
(0 / 30)
Distance
(0 / 6)
Thickness
(0 / 30)
Angle
(0 / 6)
Longi.
Length
(0 / 9)
Measurement
Value
Lumen Mean Dia.
0.57 mm
STC
Gain: 10
Contrast: 7
Gamma: 1
Depth: 4.5
Flush Media: Contrast (100%)
Distal
Φ 0.34mm / 0.1mm²
Min.
Φ 0.21mm / 0.0mm²
Proximal
Φ 1.36mm / 1.5mm²
50
100
17.8mm[119.8mm]
119.8mm
Playback Control
Skip
Bookmark
Speed 2 mm/s
Frames
1mm Step
3D
09 - MAR - 2020 16:04
HDD
Logoff

CLERMONT-FERRAND
CENTRE HOSPITALIER UNIVERSITAIRE

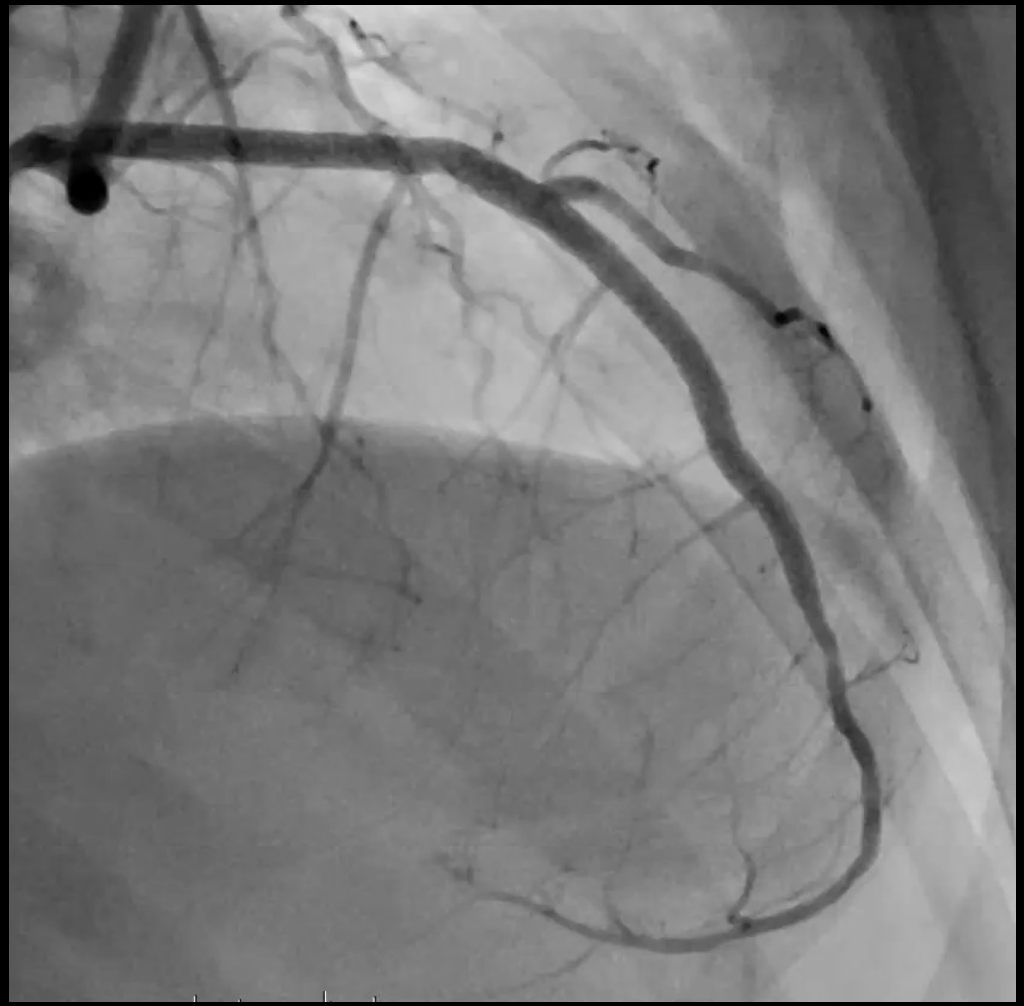

CLERMONT-FERRAND
CENTRE HOSPITALIER UNIVERSITAIRE

Mme D, âgée de 46 ans

- Contrôle angio réalisé à 4 mois
- Toujours asymptomatique, FEVG =60%
- DFM sur deux artères rénales
- Excellente évolution clinique à 20 mois

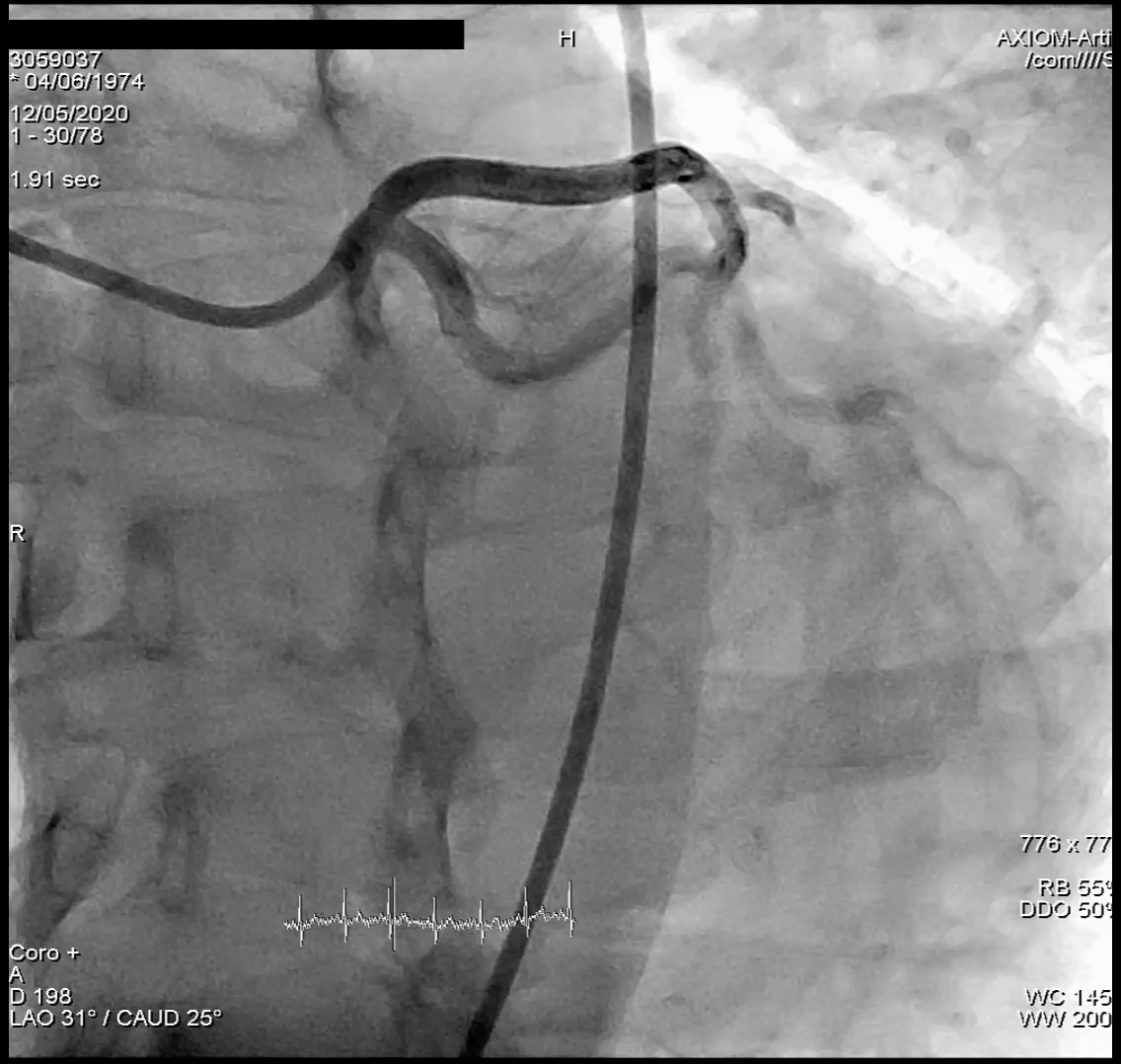
[redacted]
H
AXIOM-Arti
/com////S
3059037
* 04/06/1974
12/05/2020
1 - 30/78
1.91 sec
R
776 x 77
RB 55
DDO 50
Coro +
A
D 198
LAO 31° / CAUD 25°
WC 145
WW 200

CLERMONT-FERRAND
CENTRE HOSPITALIER UNIVERSITAIRE

Take Home Message

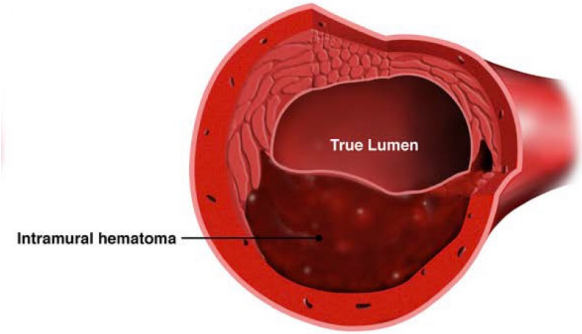

SCAD

- Y penser ne suffit pas…
- Resister à la tentation interventionnelle
- Ca peut faire mal...plusieurs jours
- Stenting après fenestration ?

CLERMONT-FERRAND
CENTRE HOSPITALIER UNIVERSITAIRE

Miss B., 37 years old

No CVRF

Admitted in secondary hospital for **NSTEMI**

troponines +, anterior severe hypokinesia, 40% LVEF, inconstant ST elevation (aVR)

Angiography : **chest pain and hemodynamic instability** during left main catheterism

Spontaneous coronary angiography suspected :

↓

transfer to University hospital of Clermont-Ferrand

Spontaneous Coronary Artery Dissection

Miss B., 37 years old

No pain, better LV function (EF=50%)

New angiography

Spontaneous Coronary Artery Dissection

CLERMONT-FERRAND
CENTRE HOSPITALIER UNIVERSITAIRE

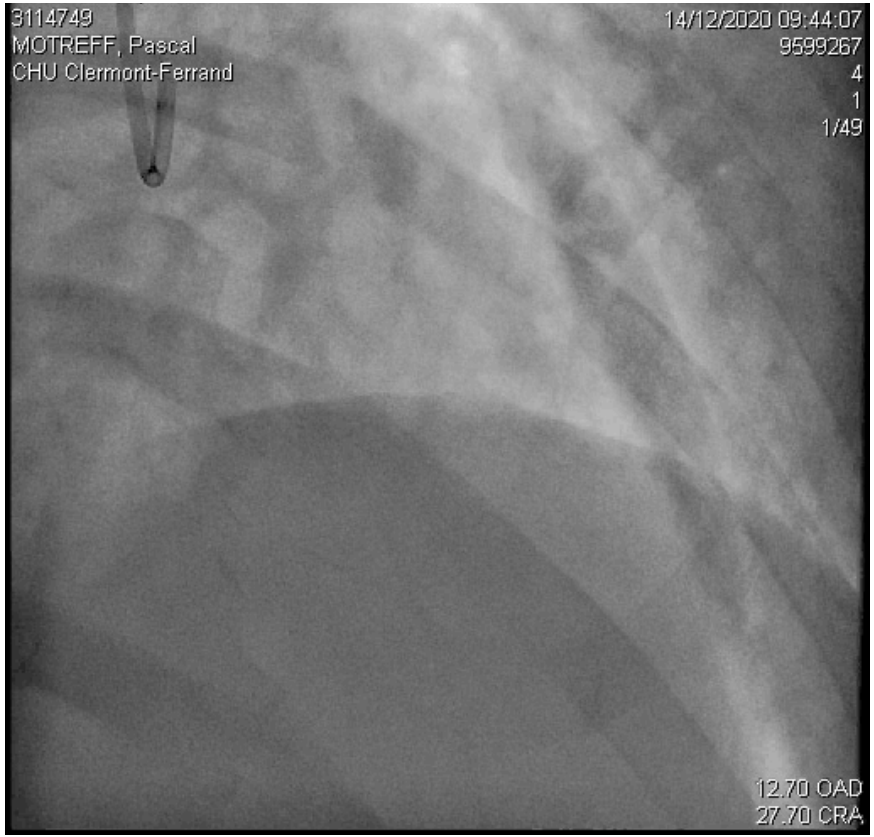

Spontaneous Coronary Artery Dissection

CLERMONT-FERRAND
CENTRE HOSPITALIER UNIVERSITAIRE

Diagnostic ambiguity ?

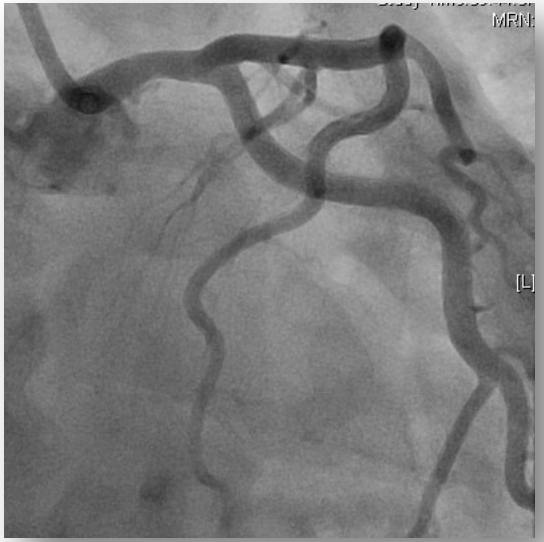

Spontaneous Coronary Artery Dissection

CLERMONT-FERRAND

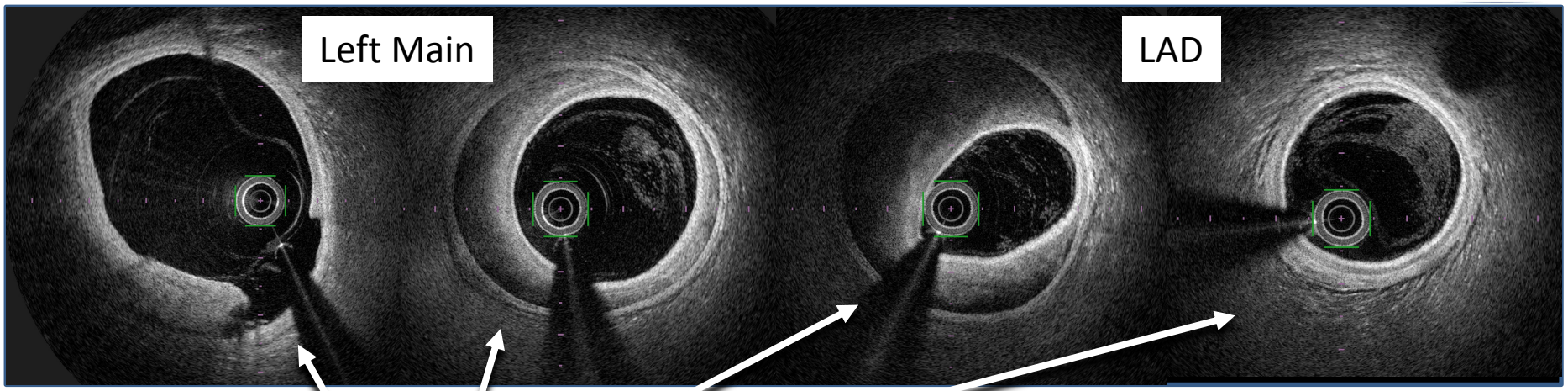

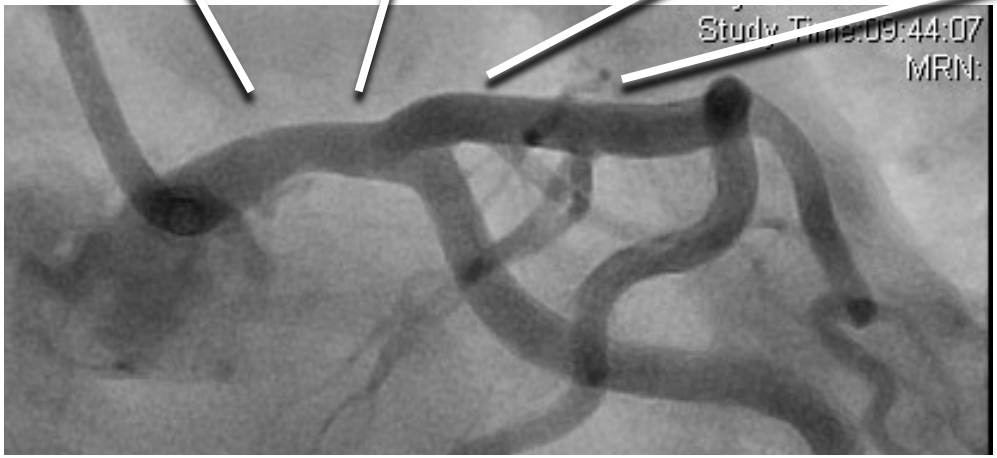

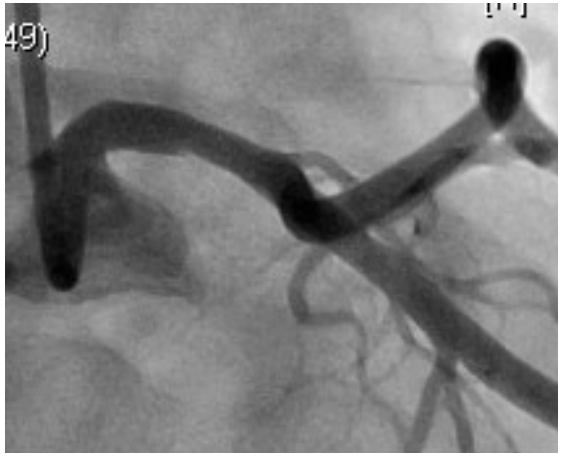

Spontaneous Coronary Artery Dissection

Conservative therapy : Betablocker + Aspirine

Spontaneous Coronary Artery Dissection

CLERMONT-FERRAND
CENTRE HOSPITALIER UNIVERSITAIRE

Miss B., 37 years old

12h later….middle of the night 😱

Intense Chest Pain, Cardiogenic schock, LVEF=20%

Emergent angiography

Spontaneous Coronary Artery Dissection

Miss B., 37 years old

12h later….middle of the night 😱

Intense Chest Pain, Cardiogenic schock

Emergent angiography

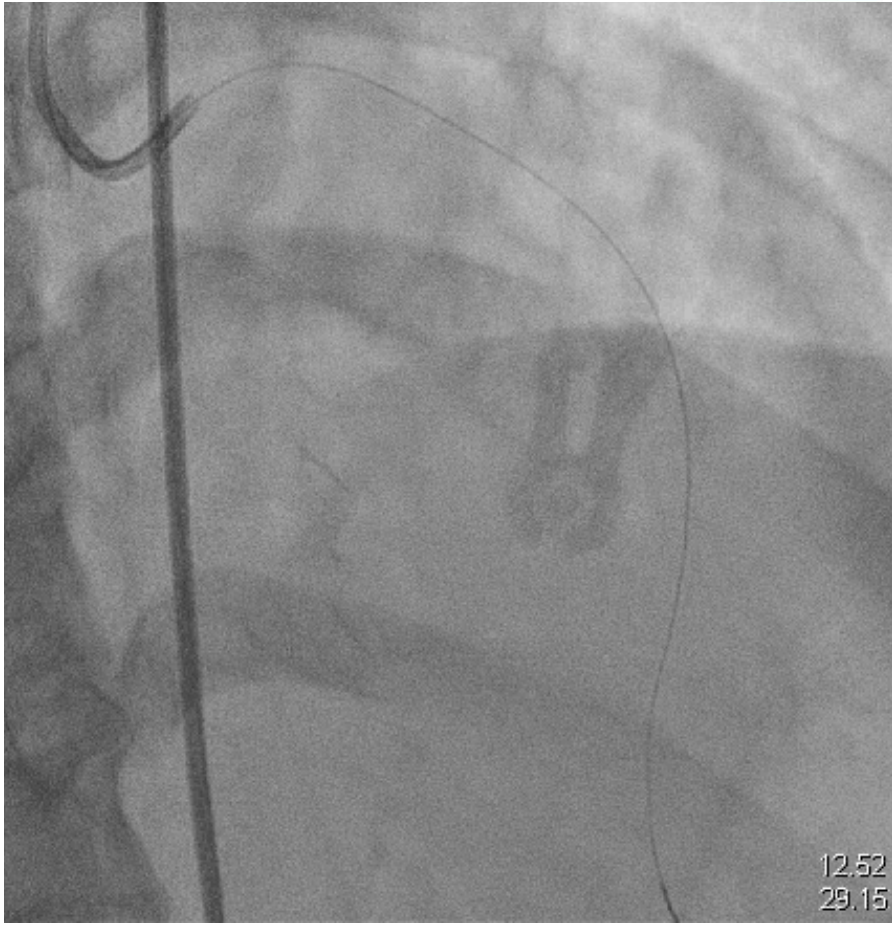

Spontaneous Coronary Artery Dissection

CLERMONT-FERRAND
CENTRE HOSPITALIER UNIVERSITAIRE

Miss B., 37 years old

12h later….middle of the night 😱

Intense Chest Pain, Cardiogenic schock

➡ **Rescue PCI**

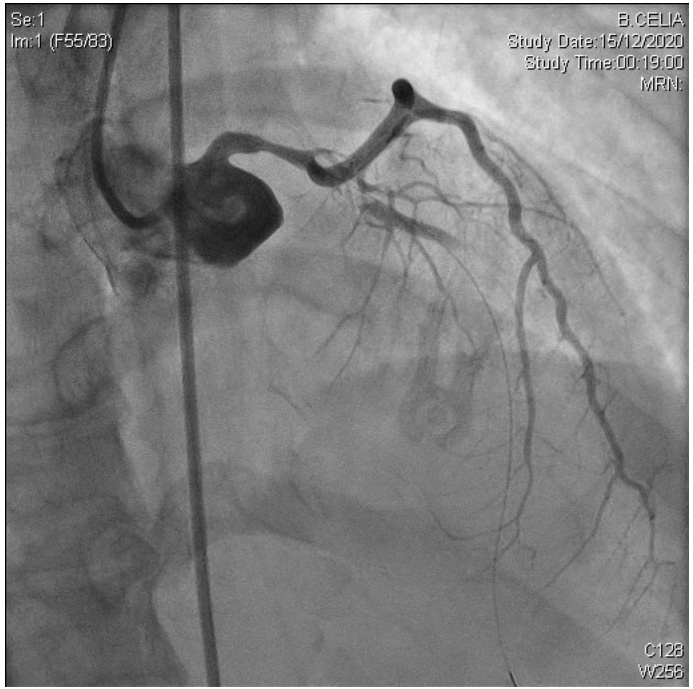

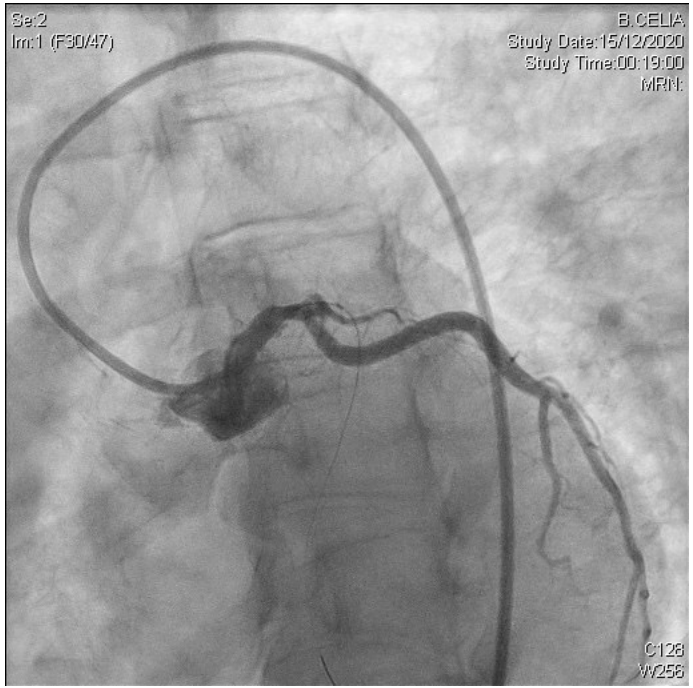

Spontaneous Coronary Artery Dissection

CLERMONT-FERRAND
CENTRE HOSPITALIER UNIVERSITAIRE

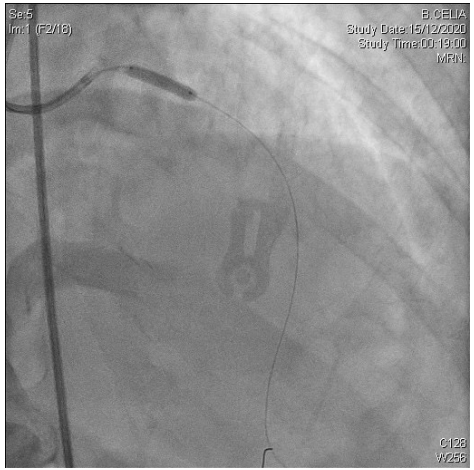

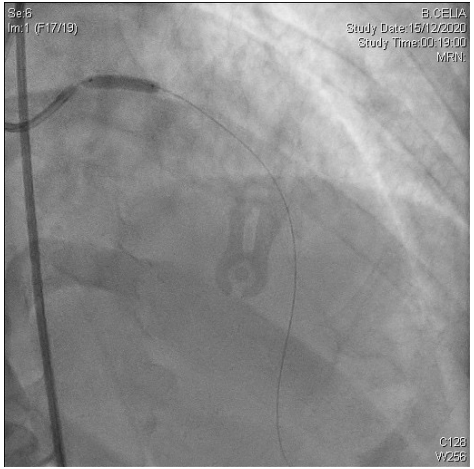

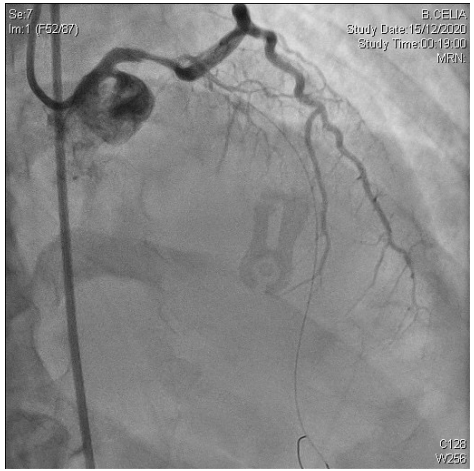

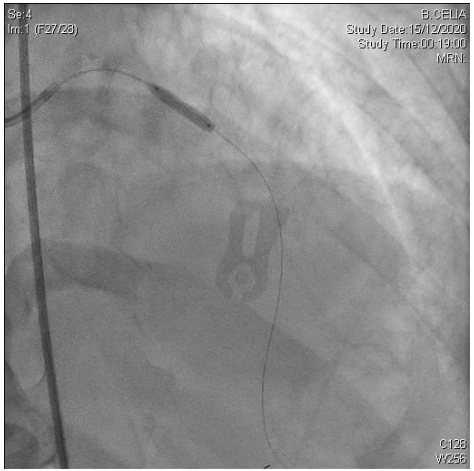

LAD and LM fenestrations

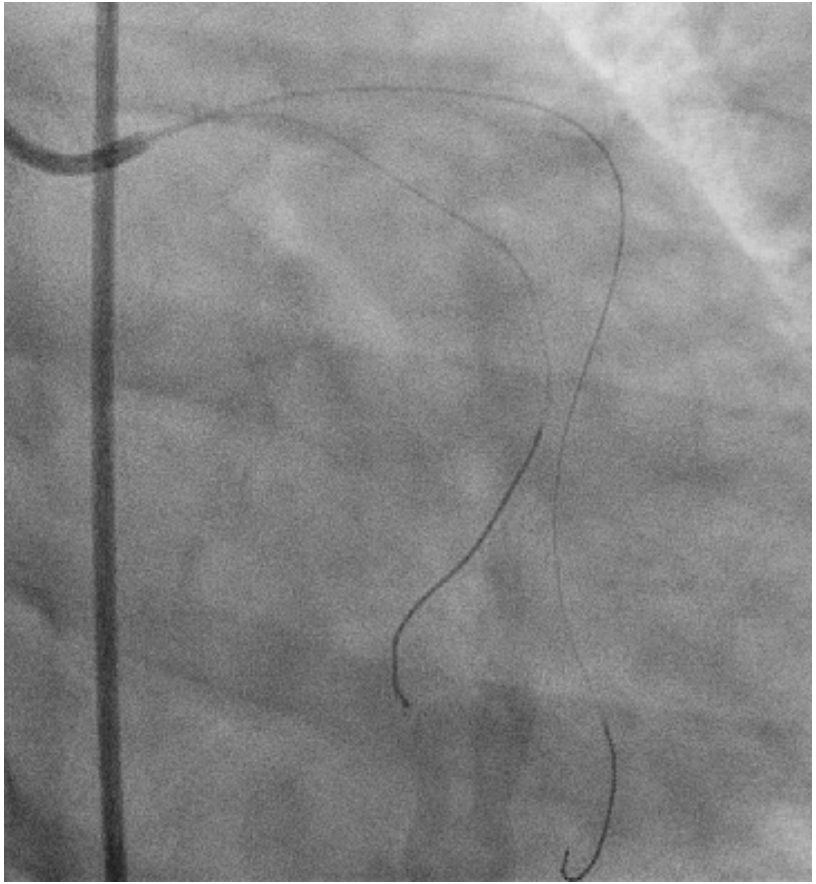

Spontaneous Coronary Artery Dissection

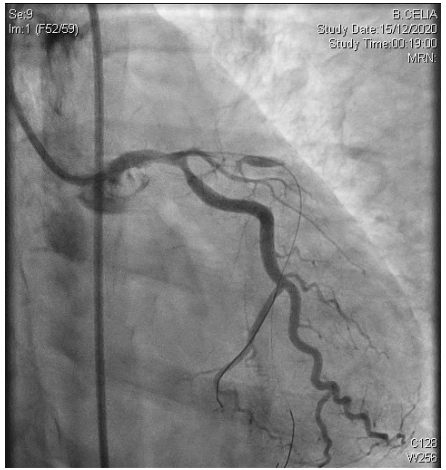

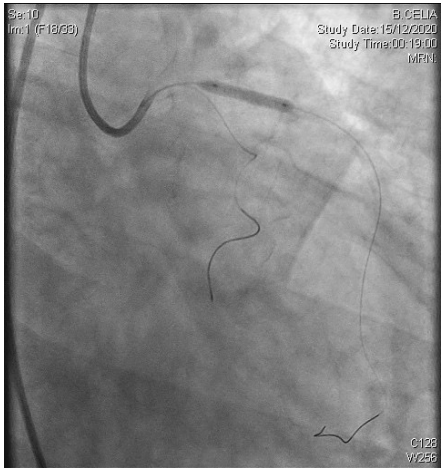

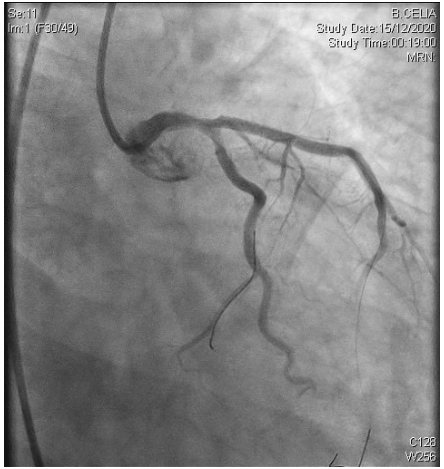

Stenting of Proximal LAD

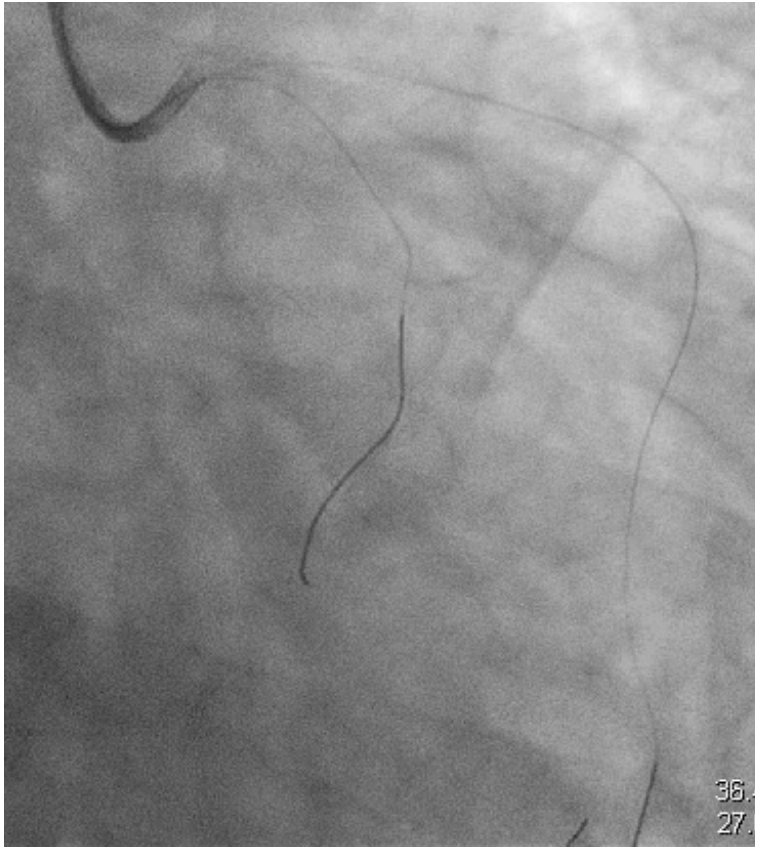

Spontaneous Coronary Artery Dissection

CLERMONT-FERRAND
CENTRE HOSPITALIER UNIVERSITAIRE

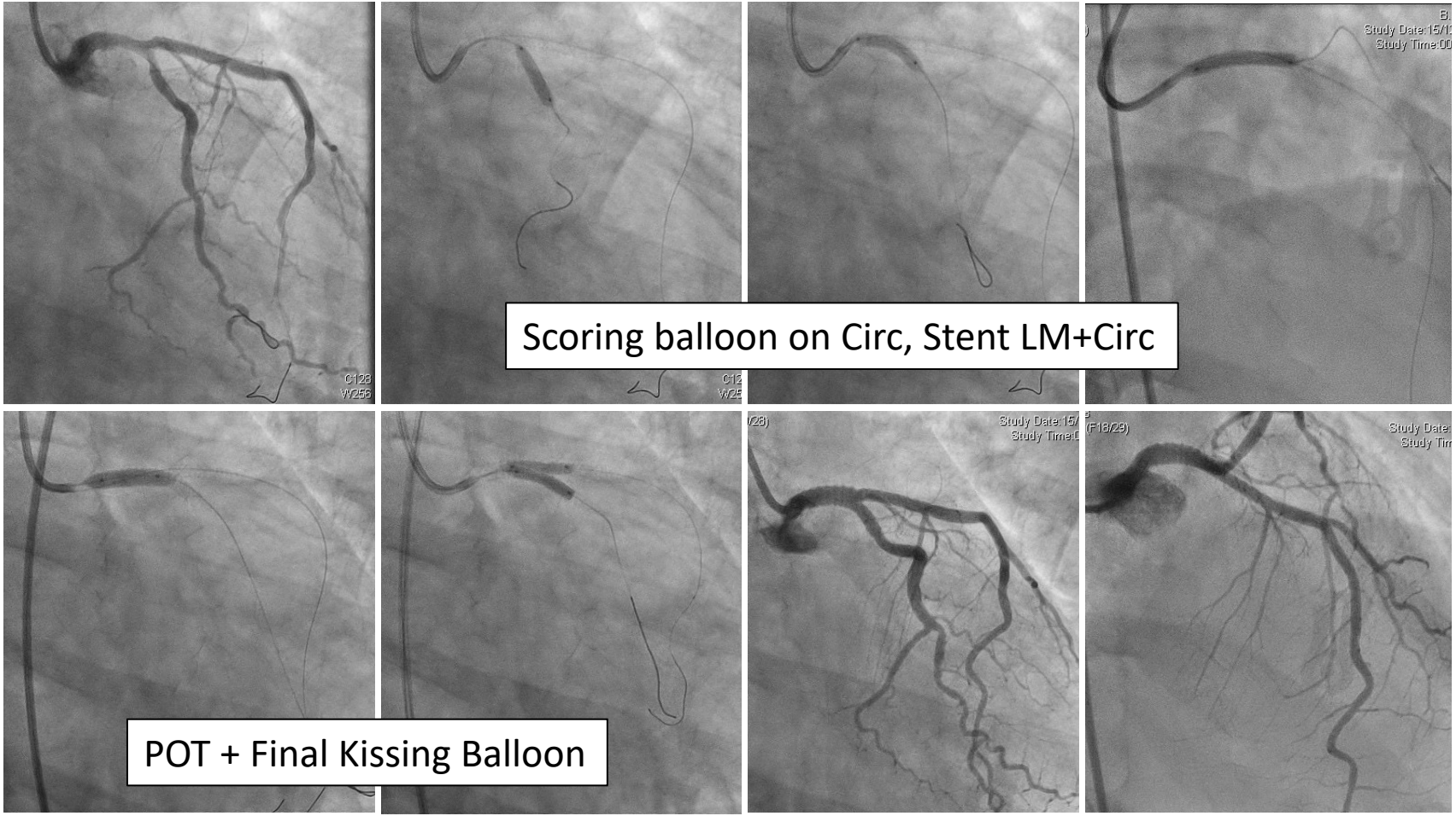

Spontaneous Coronary Artery Dissection

CLERMONT-FERRAND
CENTRE HOSPITALIER UNIVERSITAIRE

Final result

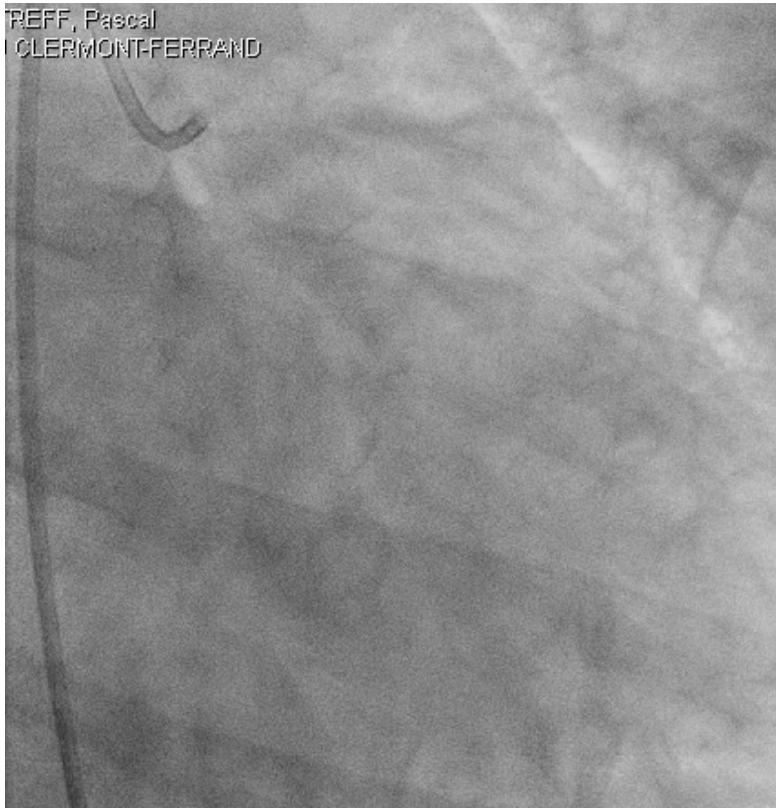

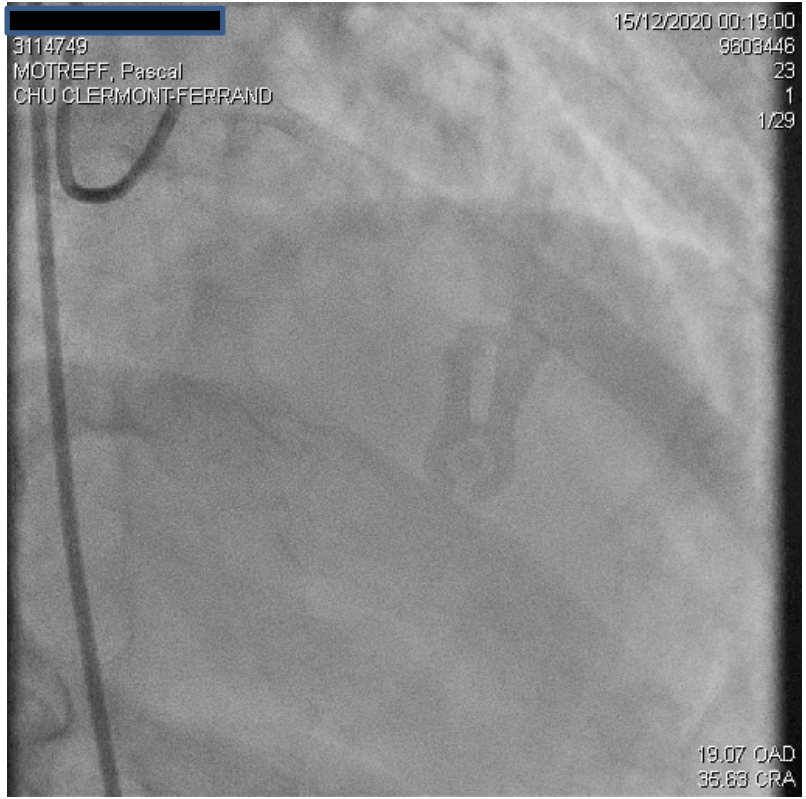

Spontaneous Coronary Artery Dissection

CLERMONT-FERRAND
CENTRE HOSPITALIER UNIVERSITAIRE

Miss B., 37 years old

Excellent evolution, asymptomatic, LVEF=55%

3 months later 😊

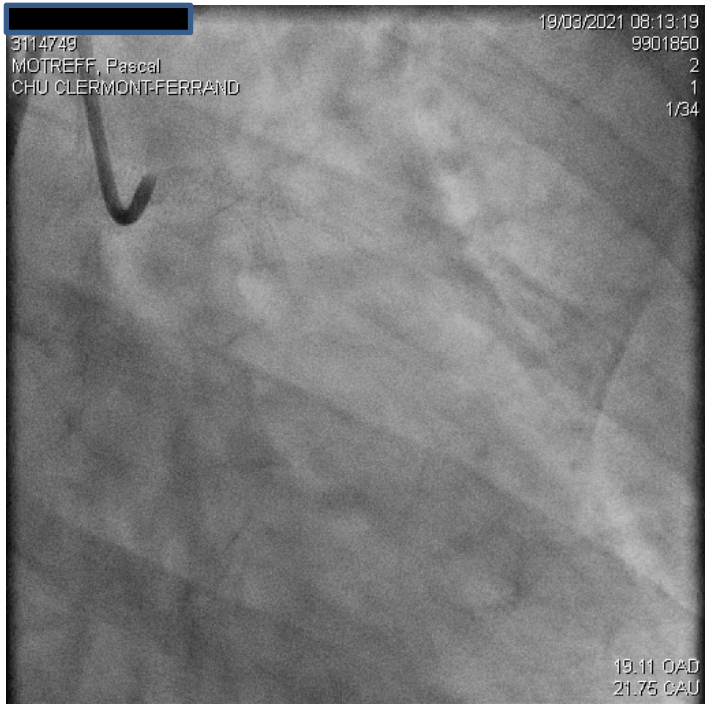

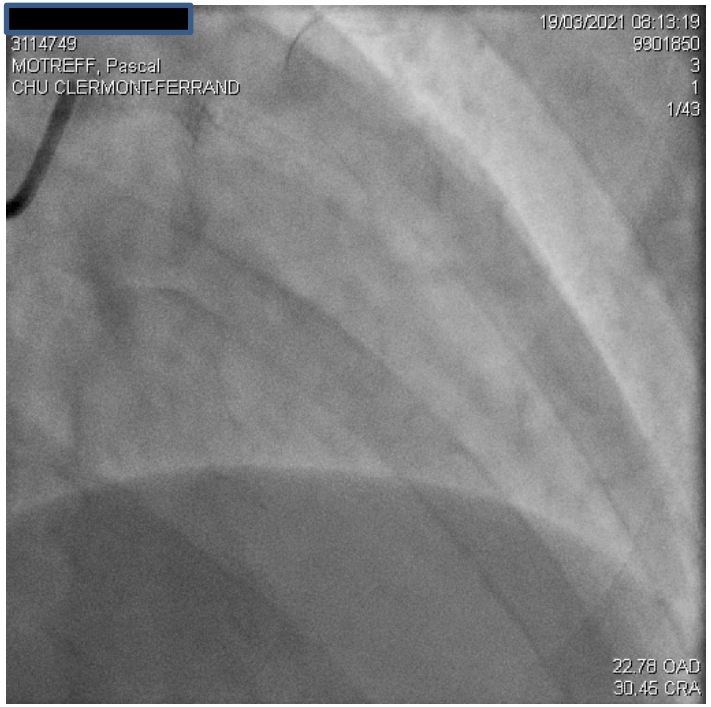

OFDI follow-up @ 3 months

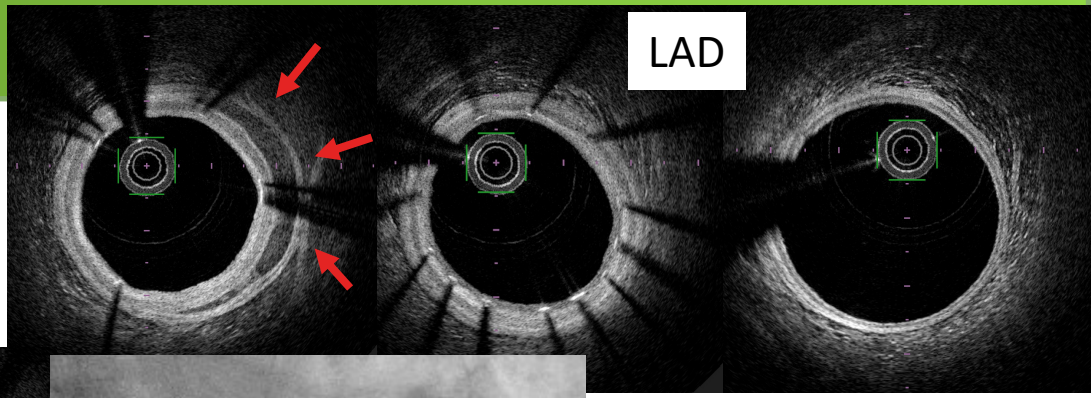

Left Main

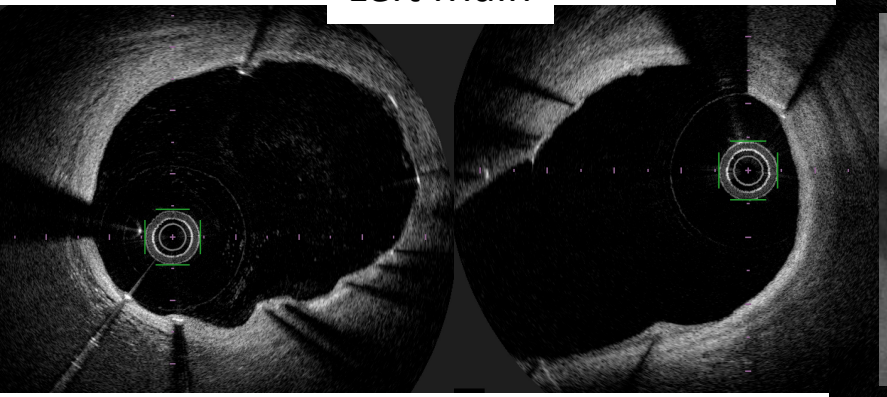

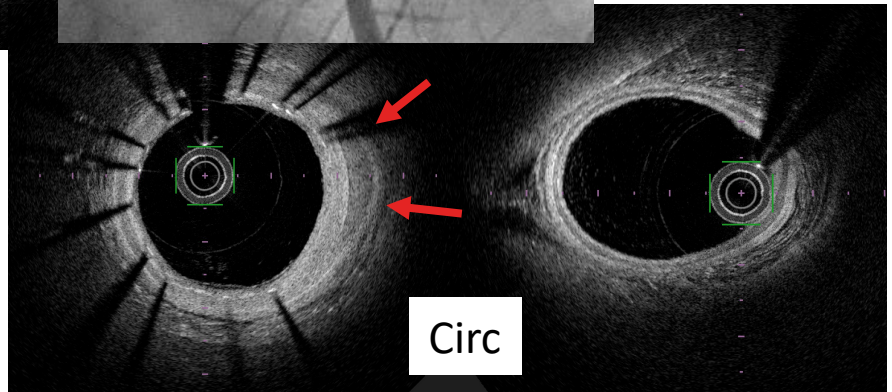

CLERMONT-FERRAND
CENTRE HOSPITALIER UNIVERSITAIRE

Take Home Message

- Non exceptionnal cause of ACS, severe prognosis
- Underestimated prevalence, cases increasing
- **French registry « DISCO » study confirms :**
  - Profile of patients
  - Good prognosis with conservative management
  - Association SCAD & Fibromuscular Dysplasia

- **Rescue fenestration in some situations can save lives**

pmotreff@chu-clermontferrand.fr