13ÈME CARDIO RUN 2021

CONGRÈS DE PATHOLOGIE CARDIO-VASCULAIRE

29-30 SEPTEMBRE & 1 OCTOBRE 2021

HÔTEL SAINT ALEXIS - ÎLE DE LA RÉUNION, FRANCE

Embolie pulmonaire hémodynamiquement instable

Frédéric Lapostolle
SAMU 93, UF Recherche
Hôpital Avicenne &
Université Paris 13, Bobigny

Hôpitaux Universitaires
Avicenne Jean-Verdier René-Muret
Paris-Seine Saint-Denis

Disclosures

- **Conferences**

Astra-Zeneca, Bayer, BMS, Boehringer-Ingelheim, Medtronic,

Merck-Serono, Mundipharma, Novartis, Pfizer, Serb, Teleflex

- **Investigator – Researsh**

Astra-Zeneca, Boehringer-Ingelheim,

Merck-Serono, Mundipharma, Novartis, Teleflex





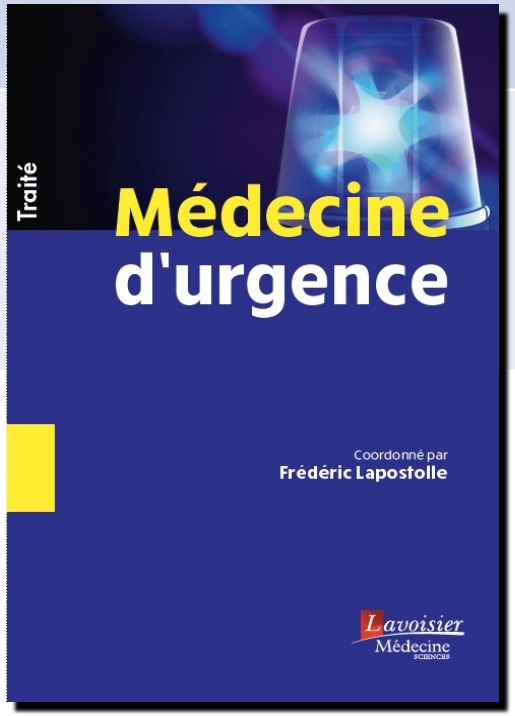

Dr House

08:00 - Premier patient

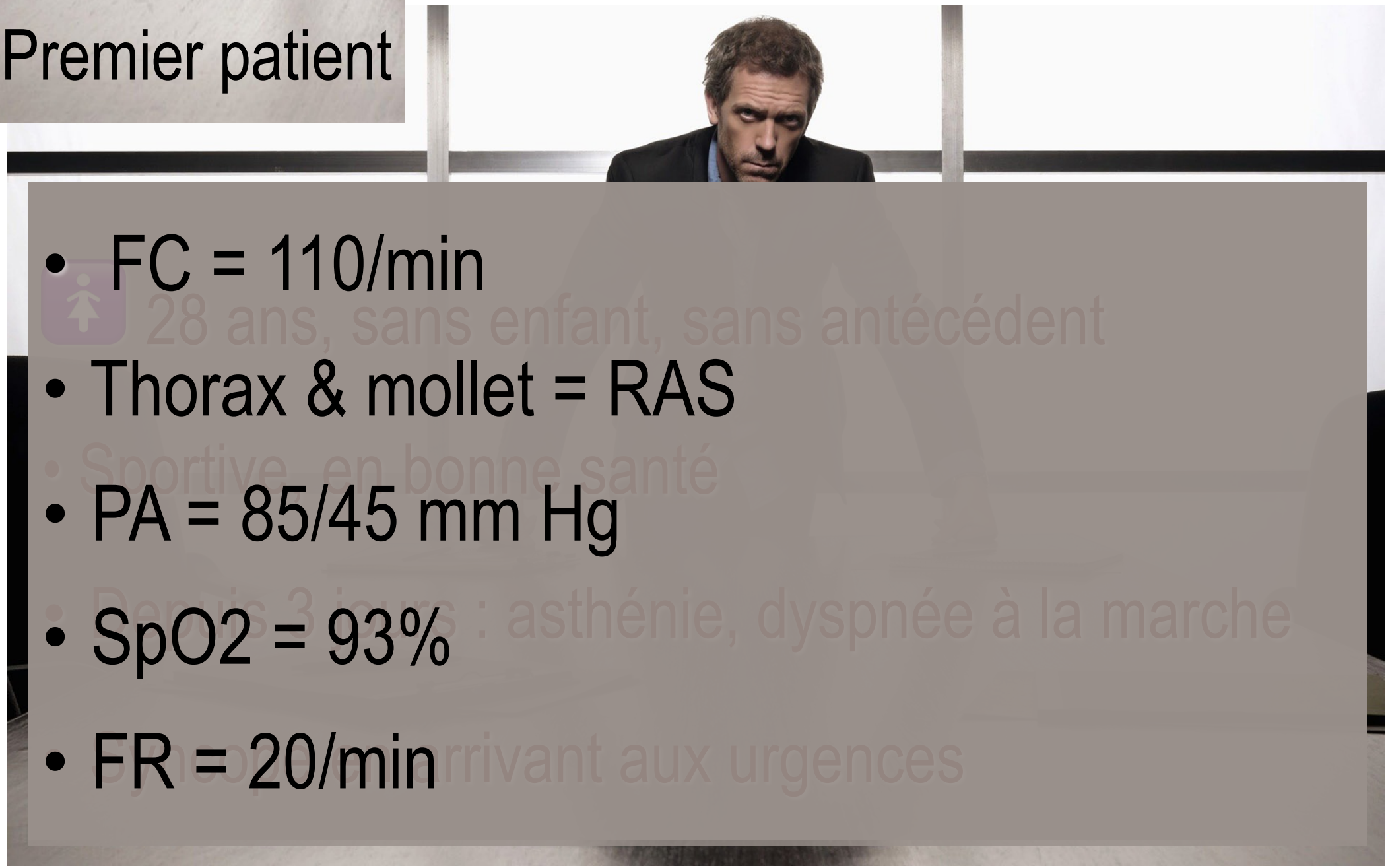

- FC = 110/min
- 28 ans, sans enfant, sans antécédent
- Thorax & mollet = RAS
- Sportive, en bonne santé
- PA = 85/45 mm Hg
- Depuis 3 jours : asthénie, dyspnée à la marche
- SpO2 = 93%
- Syncope arrivant aux urgences
- FR = 20/min

Alors, grave ou pas grave ?

Gravité de l’embolie pulmonaire ?

Jaff, *Circulation*, 2011

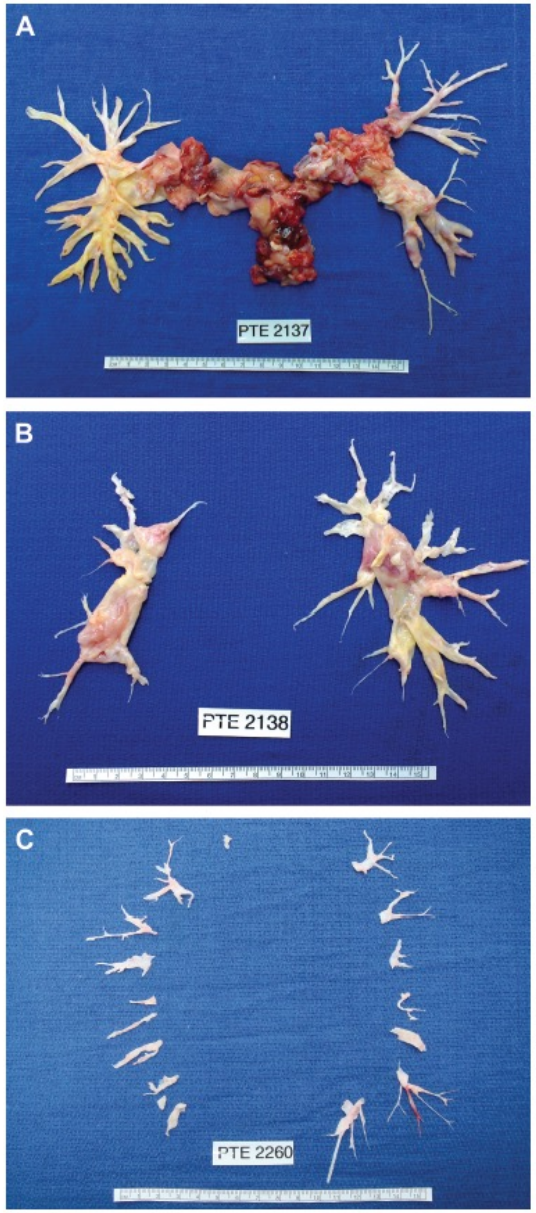

Stratification anatomique

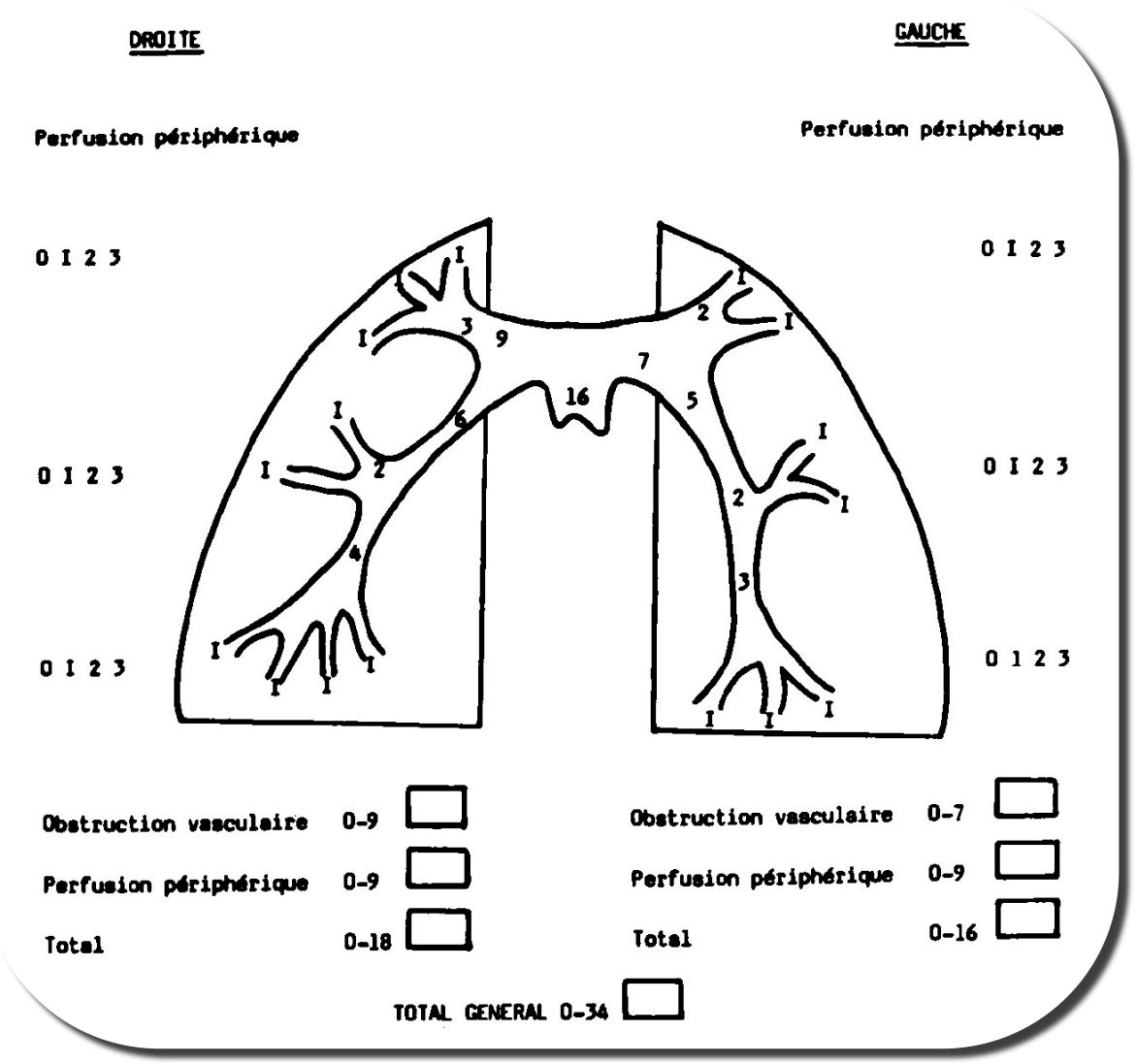

Relation between artery obstruction & pulmonary vascular resistance

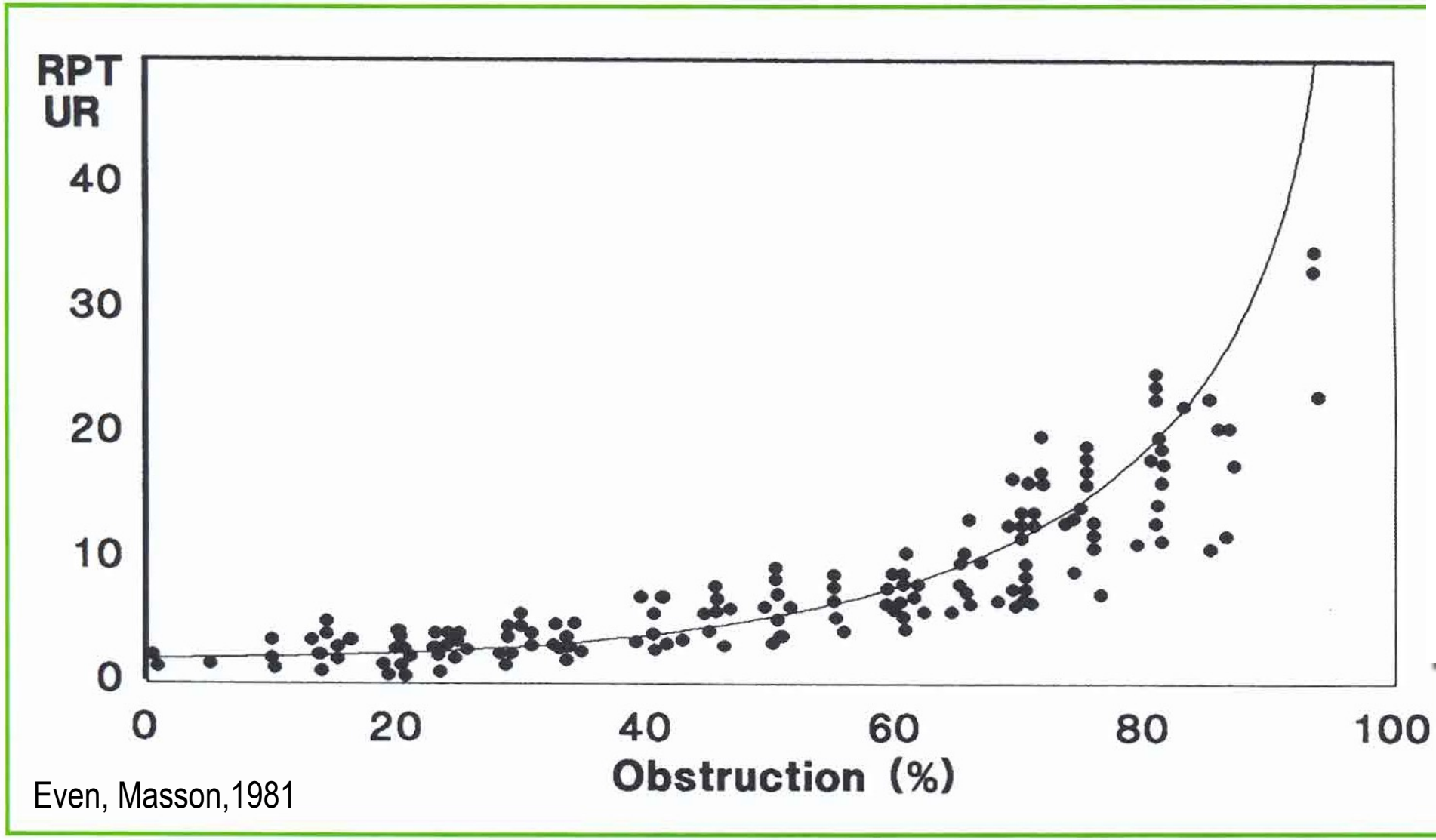

Even, Masson,1981

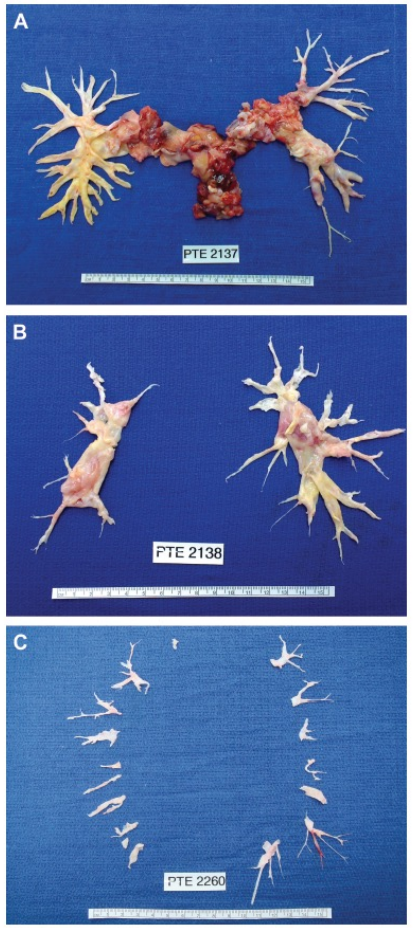

Jaff, Circulation, 2011

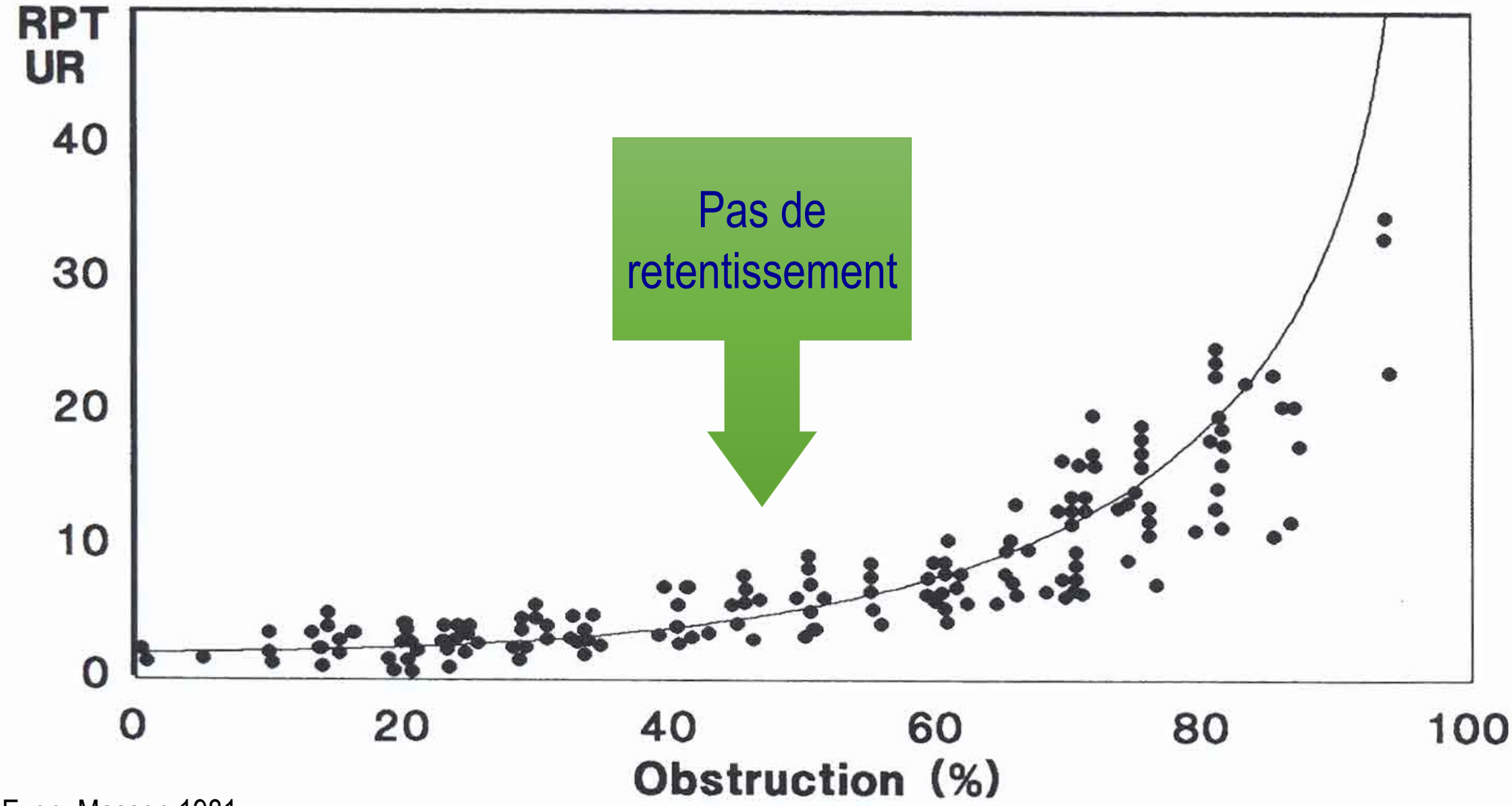

Even, Masson,1981

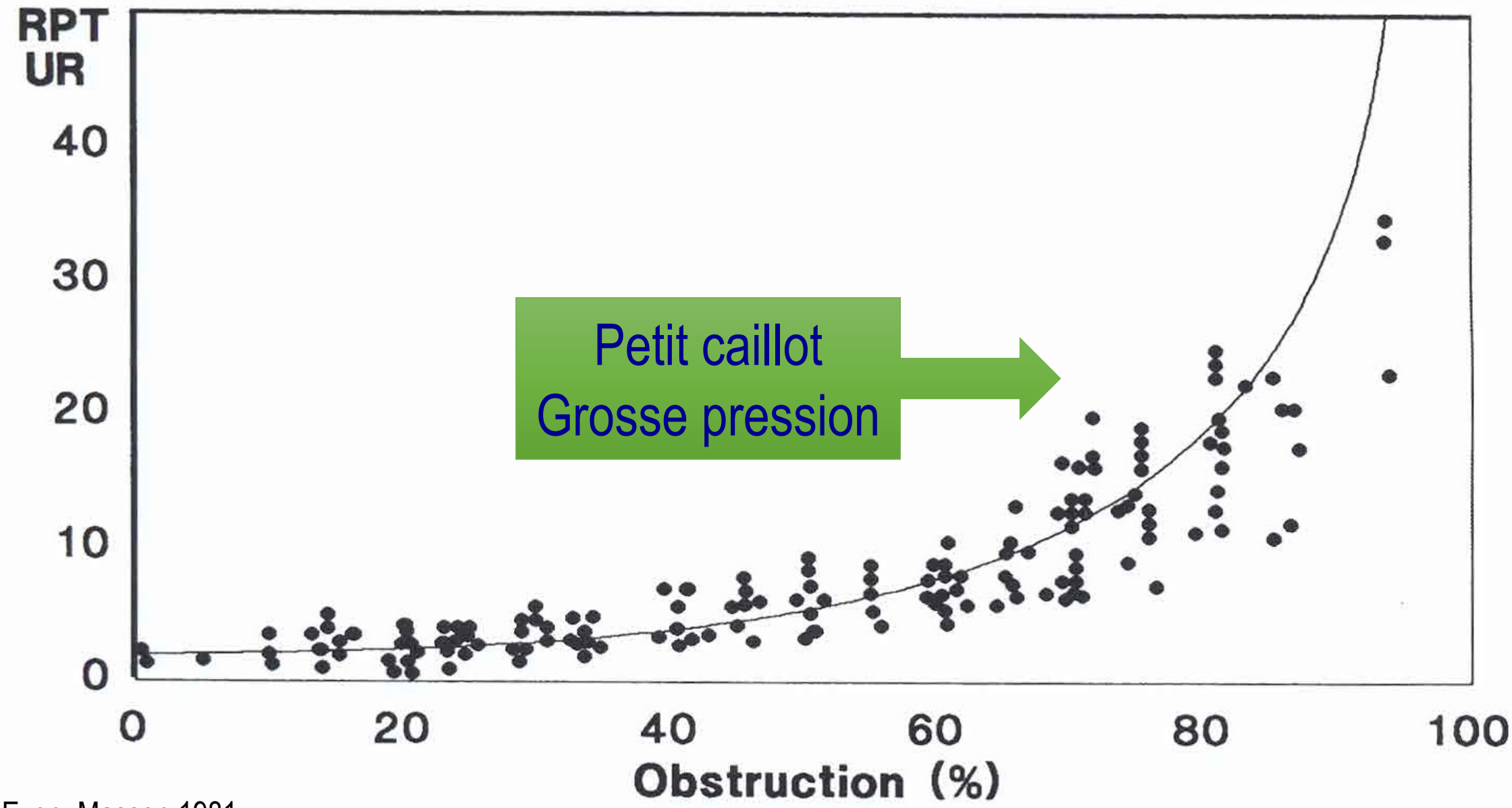

Even, Masson,1981

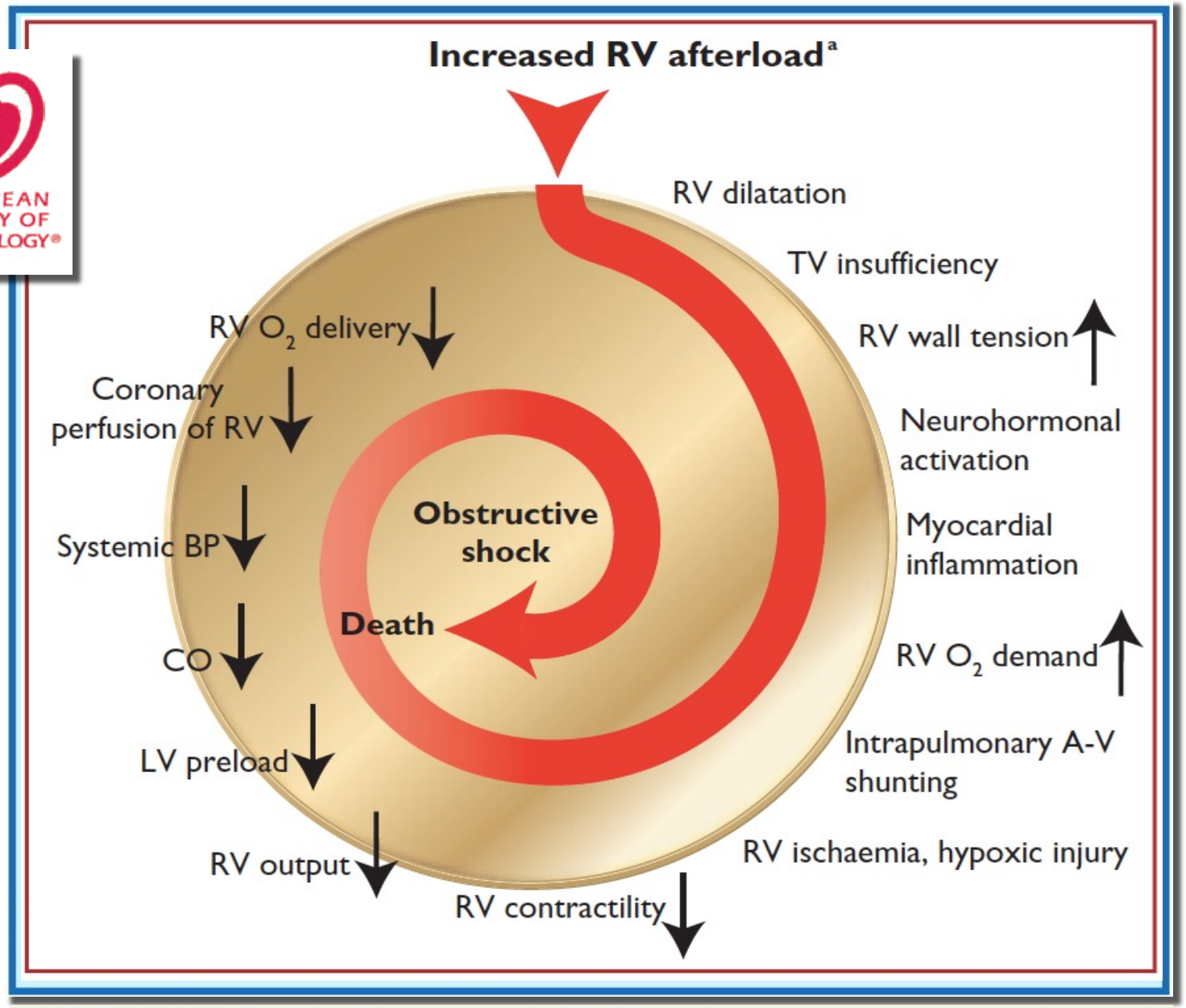

Figure 1 Key factors contributing to haemodynamic collapse in acute pulmonary embolism

Konstantinides, *Eur Heart J*, 2014 & 2019

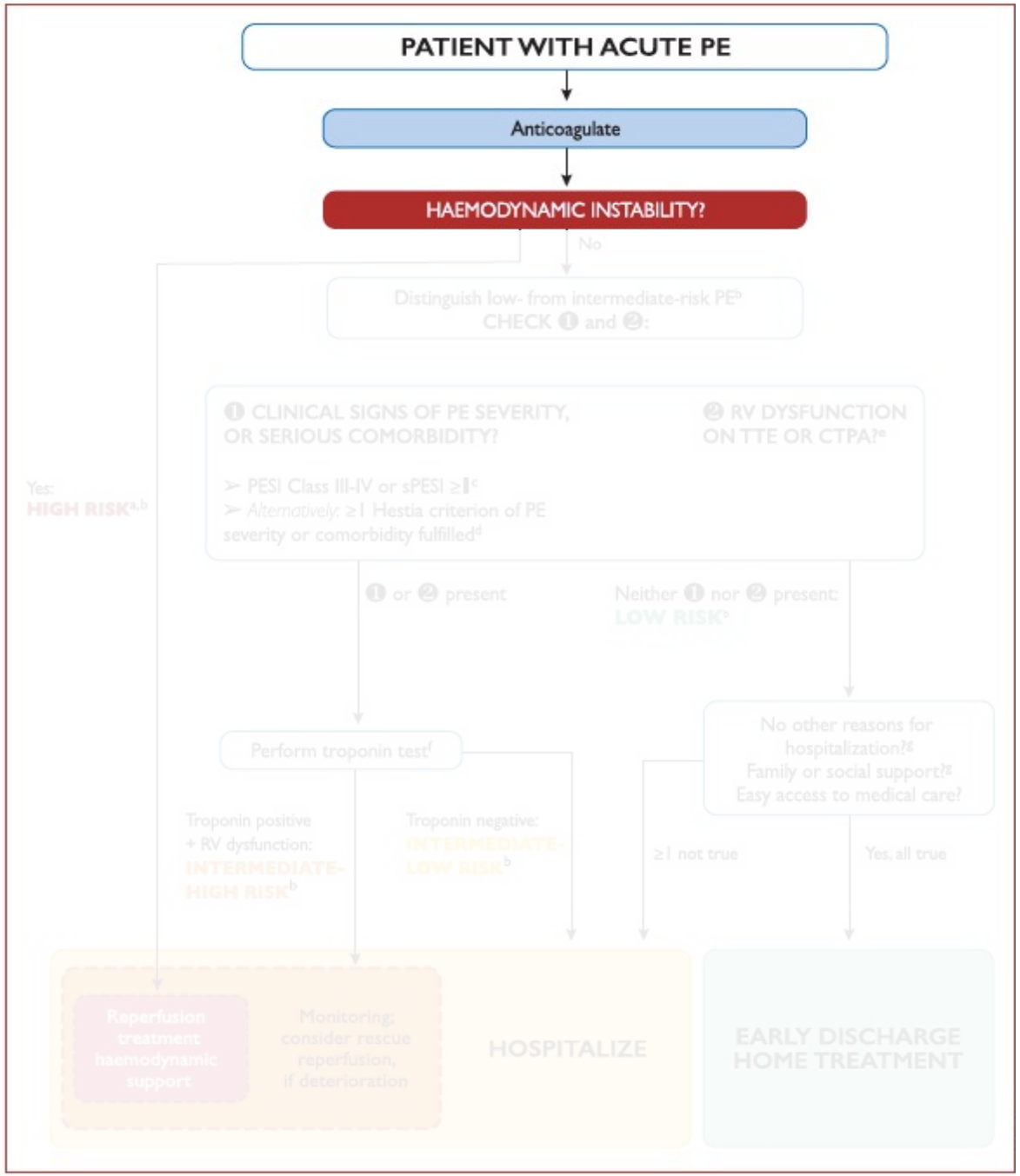

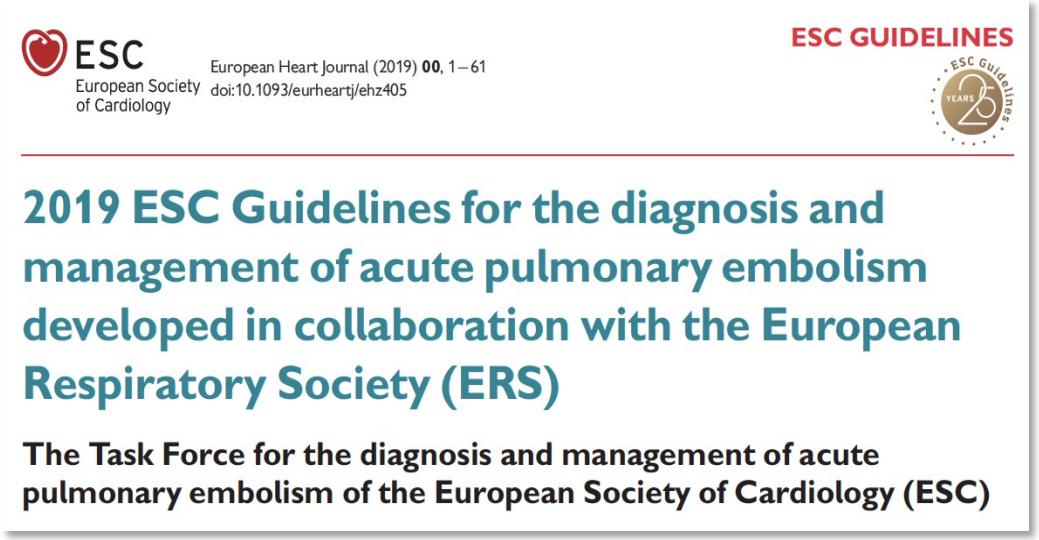
ESC European Society of Cardiology
European Heart Journal (2019) 00, 1–61
doi:10.1093/eurheartj/ehz405
ESC GUIDELINES

2019 ESC Guidelines for the diagnosis and management of acute pulmonary embolism developed in collaboration with the European Respiratory Society (ERS)

The Task Force for the diagnosis and management of acute pulmonary embolism of the European Society of Cardiology (ESC)

ESC, *Eur Heart J*, 2019

Stratégie diagnostique spécifique

20minutes.fr

Go

Metalyse®
10,000 U
Boehringer
Ingelheim
Solvent for parenteral use
10 ml water

Metalyse®
Powder for solution for injection.
10,000 U tenecteplase per vial
For intravenous use after
Do not store above 30°C. Keep
Read the package leaflet
before use
Boehringer
Ingelheim

(1) Cardiac arrest	(2) Obstructive shock[68–70]	(3) Persistent hypotension
Need for cardiopulmonary resuscitation	Systolic BP < 90 mmHg or vasopressors required to achieve a BP ≥90 mmHg despite adequate filling status	Systolic BP < 90 mmHg or systolic BP drop ≥40 mmHg, lasting longer than 15 min and not caused by new-onset arrhythmia, hypovolaemia, or sepsis
	And	
	End-organ hypoperfusion (altered mental status; cold, clammy skin; oliguria/anuria; increased serum lactate)	

Arrêt cardiaque

Choc

Thrombolyse/embolectomie

08:05 - Premier patient

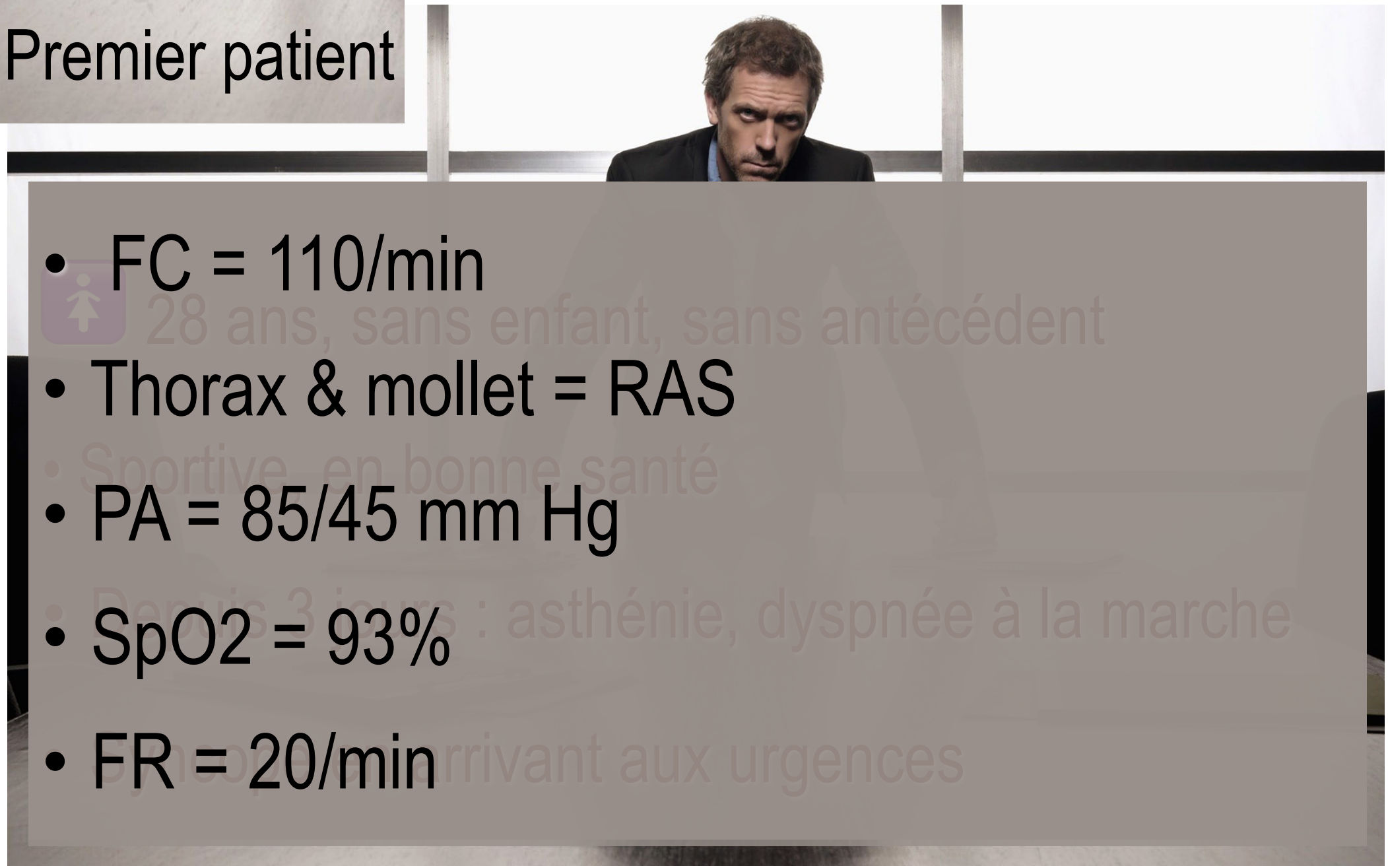

- FC = 110/min
- Thorax & mollet = RAS
- PA = 85/45 mm Hg
- SpO2 = 93%
- FR = 20/min

28 ans, sans enfant, sans antécédent

Sportive, en bonne santé

Depuis 3 jours : asthénie, dyspnée à la marche

Syncope arrivant aux urgences

Examen 1ère intention ?

Examen de référence ?

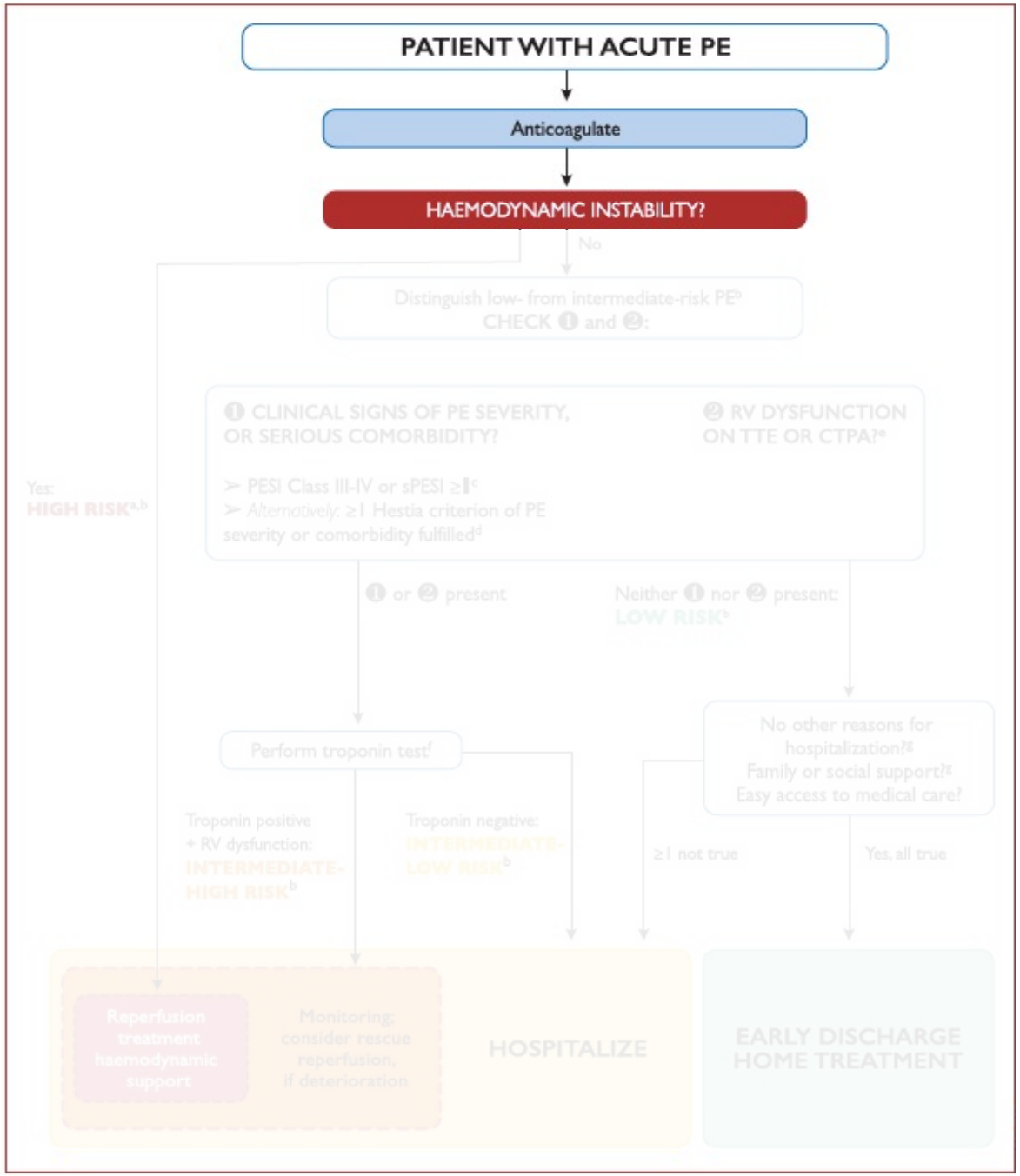

ESC European Society of Cardiology
European Heart Journal (2019) **00**, 1–61
doi:10.1093/eurheartj/ehz405

ESC GUIDELINES

2019 ESC Guidelines for the diagnosis and management of acute pulmonary embolism developed in collaboration with the European Respiratory Society (ERS)

The Task Force for the diagnosis and management of acute pulmonary embolism of the European Society of Cardiology (ESC)

GE Healthcare
Vscan

Optima

Suspected PE in a patient with haemodynamic instability[a]

Treatment of high-risk PE[a]

Info
Intox
Affirme le diagnostic d'EP
Pas de gros VD
TVP à écho 4 points

Lower-limb CUS		
It is recommended to accept the diagnosis of VTE (and PE) if a CUS shows a proximal DVT in a patient with clinical suspicion of PE.[164,165]	I	A
If CUS shows only a distal DVT, further testing should be considered to confirm PE.[177]	IIa	B
If a positive proximal CUS is used to confirm PE, assessment of PE severity should be considered to permit risk-adjusted management.[178,179]	IIa	C

D-dimer		
Plasma D-dimer measurement, preferably using a highly sensitive assay, is recommended in outpatients/emergency department patients with low or intermediate clinical probability, or those that are PE-unlikely, to reduce the need for unnecessary imaging and irradiation.[101–103,122,164,171,173,174]	I	A
As an alternative to the fixed D-dimer cut-off, a negative D-dimer test using an age-adjusted cut-off (age × 10 μg/L, in patients aged >50 years) should be considered for excluding PE in patients with low or intermediate clinical probability, or those that are PE-unlikely.[106]	IIa	B
As an alternative to the fixed or age-adjusted D-dimer cut-off, D-dimer levels adapted to clinical probability[c] should be considered to exclude PE.[107]	IIa	B
D-dimer measurement is not recommended in patients with high clinical probability, as a normal result does not safely exclude PE, even when using a highly sensitive assay.[175,176]	III	A

ESC, *Eur Heart J*, 2019

08:25 - Premier patient



- FC = 105/min
- PA = 95/45 mm Hg
- SpO2 = 93%
- FR = 20/min
- TDM : EP avec **VD/VG > 1**

Agnelli, 2010

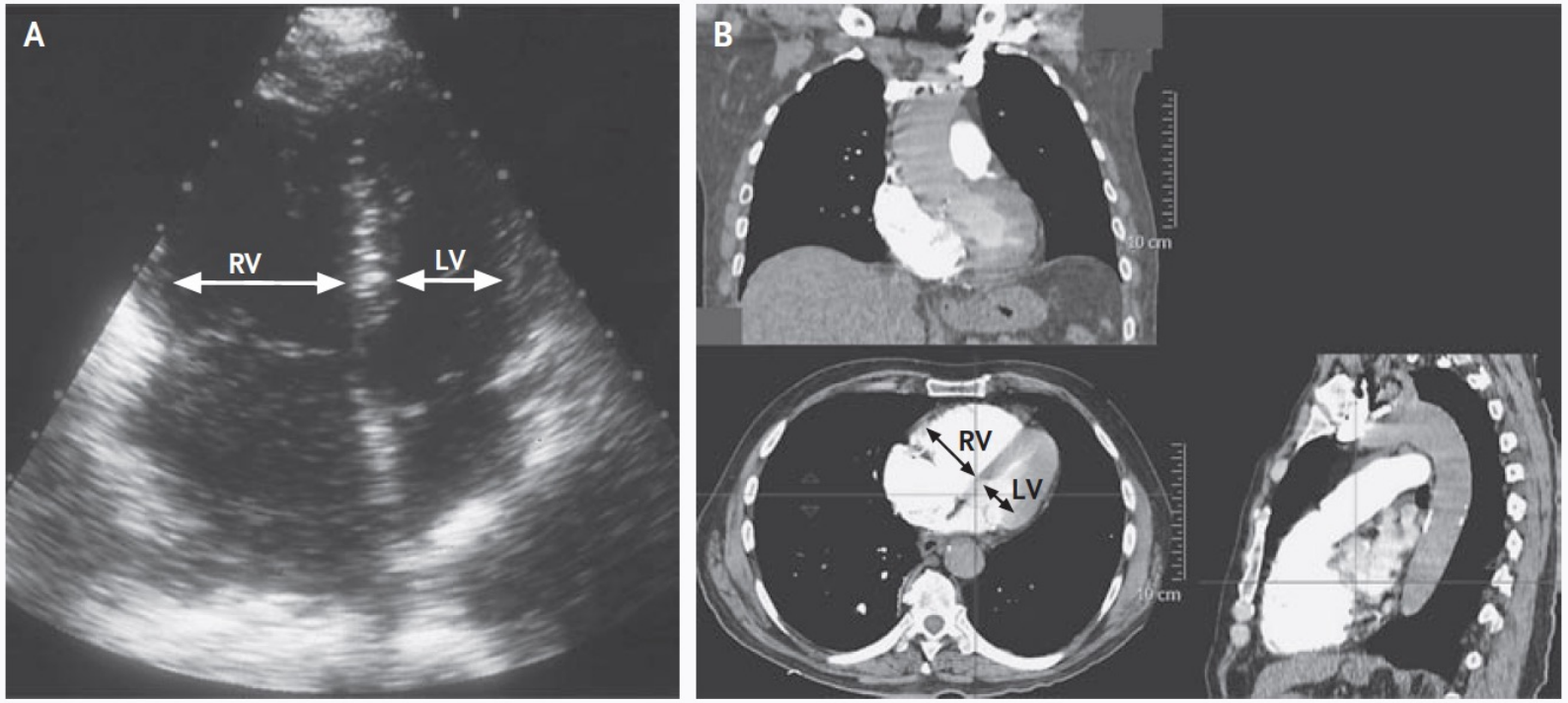

Figure 3. Right Ventricular Dilatation.

Right ventricular hypokinesis and dilatation have been shown to be independent predictors of 30-day mortality among hemodynamically stable patients with pulmonary embolism. In Panel A, right ventricular dilatation is clearly visible on echocardiography. In Panel B, images obtained on multiplanar reconstruction of multidetector CT angiography show the right and left heart chambers in the coronal view (at upper left), in the axial view (at lower left), and in the sagittal view (at lower right). Images obtained on multiplanar reconstruction at the valvular plane in the axial view allow the measurement of the diameter of the right ventricle (RV) and the left ventricle (LV) (at lower left). A ratio of more than 1.0 for the diameter of the right ventricle to that of the left ventricle indicates right ventricular dysfunction.

Critères de thrombolyse ?

The NEW ENGLAND JOURNAL of MEDICINE

ORIGINAL ARTICLE

Fibrinolysis for Patients with Intermediate-Risk Pulmonary Embolism

Guy Meyer, M.D., Eric Vicaut, M.D., Thierry Danays, M.D., Giancarlo Agnelli, M.D., Cecilia Becattini, M.D., Jan Beyer-Westendorf, M.D., Erich Bluhmki, M.D., Ph.D., Helene Bouvaist, M.D., Benjamin Brenner, M.D., Francis Couturaud, M.D., Ph.D., Claudia Dellas, M.D., Klaus Empen, M.D., Ana Franca, M.D., Nazzareno Galiè, M.D., Annette Geibel, M.D., Samuel Z. Goldhaber, M.D., David Jimenez, M.D., Ph.D., Matija Kozak, M.D., Christian Kupatt, M.D., Nils Kucher, M.D., Irene M. Lang, M.D., Mareike Lankeit, M.D., Nicolas Meneveau, M.D., Ph.D., Gerard Pacouret, M.D., Massimiliano Palazzini, M.D., Antoniu Petris, M.D., Ph.D., Piotr Pruszczyk, M.D., Matteo Rugolotto, M.D., Aldo Salvi, M.D., Sebastian Schellong, M.D., Mustapha Sebbane, M.D., Bozena Sobkowicz, M.D., Branislav S. Stefanovic, M.D., Ph.D., Holger Thiele, M.D., Adam Torbicki, M.D., Franck Verschuren, M.D., Ph.D., and Stavros V. Konstantinides, M.D., for the PEITHO Investigators*

10 Avril 2014

HEPARIN PLUS ALTEPLASE COMPARED WITH HEPARIN ALONE IN PATIENTS WITH SUBMASSIVE PULMONARY EMBOLISM

STAVROS KONSTANTINIDES, M.D., ANNETTE GEIBEL, M.D., GERHARD HEUSEL, PH.D., FRITZ HEINRICH, M.D., AND WOLFGANG KASPER, M.D., FOR THE MANAGEMENT STRATEGIES AND PROGNOSIS OF PULMONARY EMBOLISM-3 TRIAL INVESTIGATORS*

EVENT	HEPARIN PLUS ALTEPLASE (N=118)	HEPARIN PLUS PLACEBO (N=138)	P VALUE†
	no. (%)		
Primary end point	13 (11.0)	34 (24.6)	0.006
Death from all causes	4 (3.4)	3 (2.2)	0.71
Escalation of treatment	12 (10.2)	34 (24.6)	0.004
Catecholamine infusion (for persistent hypotension or shock)	3 (2.5)	8 (5.8)	0.33
Secondary thrombolysis	9 (7.6)	32 (23.2)	0.001
Endotracheal intubation	3 (2.5)	3 (2.2)	0.85
Cardiopulmonary resuscitation	0	1 (0.7)	1.0
Embolectomy or thrombus fragmentation	0	1 (0.7)	1.0
Secondary end points			
Recurrent pulmonary embolism‡	4 (3.4)	4 (2.9)	0.89
Major bleeding§	1 (0.8)	5 (3.6)	0.29
Fatal bleeding	0	1 (0.7)	1.0
Hemorrhagic stroke¶	0	0	—
Ischemic stroke¶	0	1 (0.7)	1.0

Konstantinides, *New Engl J Med*, 2002

The NEW ENGLAND JOURNAL of MEDICINE

ORIGINAL ARTICLE

Fibrinolysis for Patients with Intermediate-Risk Pulmonary Embolism

Guy Meyer, M.D., Eric Vicaut, M.D., Thierry Danays, M.D., Giancarlo Agnelli, M.D., Cecilia Becattini, M.D., Jan Beyer-Westendorf, M.D., Erich Bluhmki, M.D., Ph.D., Helene Bouvaist, M.D., Benjamin Brenner, M.D., Francis Couturaud, M.D., Ph.D., Claudia Dellas, M.D., Klaus Empen, M.D., Ana Franca, M.D., Nazzareno Galiè, M.D., Annette Geibel, M.D., Samuel Z. Goldhaber, M.D., David Jimenez, M.D., Ph.D., Matija Kozak, M.D., Christian Kupatt, M.D., Nils Kucher, M.D., Irene M. Lang, M.D., Mareike Lankeit, M.D., Nicolas Meneveau, M.D., Ph.D., Gerard Pacouret, M.D., Massimiliano Palazzini, M.D., Antoniu Petris, M.D., Ph.D., Piotr Pruszczyk, M.D., Matteo Rugolotto, M.D., Aldo Salvi, M.D., Sebastian Schellong, M.D., Mustapha Sebbane, M.D., Bozena Sobkowicz, M.D., Branislav S. Stefanovic, M.D., Ph.D., Holger Thiele, M.D., Adam Torbicki, M.D., Franck Verschuren, M.D., Ph.D., and Stavros V. Konstantinides, M.D., for the PEITHO Investigators*

10 Avril 2014

Outcome	Tenecteplase (N=506)	Placebo (N=499)	Odds Ratio (95% CI)	P Value
Primary outcome — no. (%)	13 (2.6)	28 (5.6)	0.44 (0.23–0.87)	0.02
Death from any cause	6 (1.2)	9 (1.8)	0.65 (0.23–1.85)	0.42
Hemodynamic decompensation	8 (1.6)	25 (5.0)	0.30 (0.14–0.68)	0.002

Table 4. Safety Outcomes in the Intention-to-Treat Population.*

Outcome	Tenecteplase (N=506)	Placebo (N=499)	Odds Ratio (95% CI)	P Value
	no. (%)			
Bleeding between randomization and day 7				
Major extracranial bleeding	32 (6.3)	6 (1.2)	5.55 (2.3–13.39)	<0.001
Minor bleeding	165 (32.6)	43 (8.6)		
Major bleeding†	58 (11.5)	12 (2.4)		
Stroke between randomization and day 7	12 (2.4)	1 (0.2)	12.10 (1.57–93.39)	0.003
Ischemic stroke	2 (0.4)	0		
Hemorrhagic stroke‡	10 (2.0)	1 (0.2)		
Serious adverse events between randomization and day 30	55 (10.9)	59 (11.8)	0.91 (0.62–1.34)	0.63

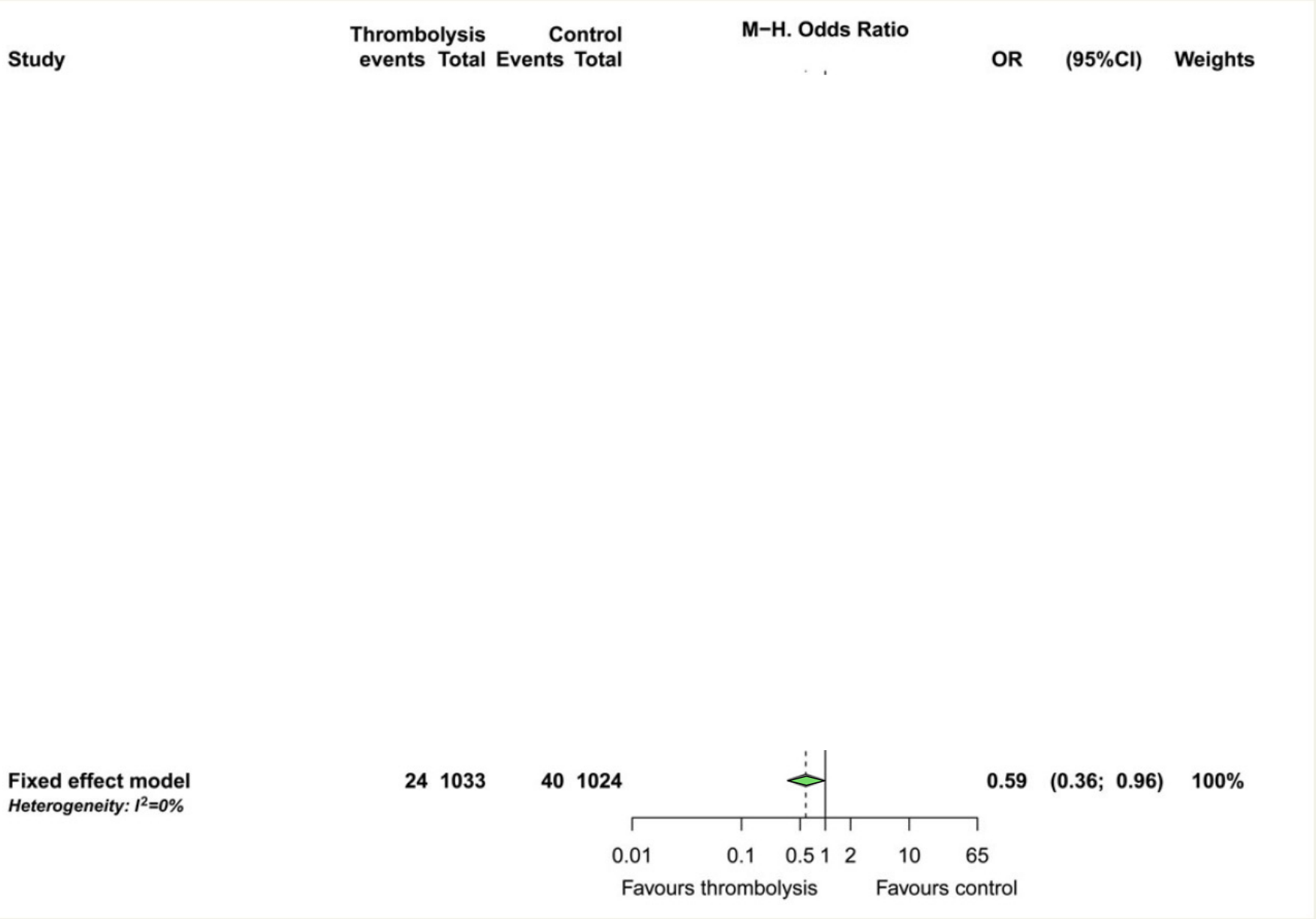

Figure 2 Early mortality by pulmonary embolism severity, Forest plot.

Konstantinides, *Eur Heart J*, 2014

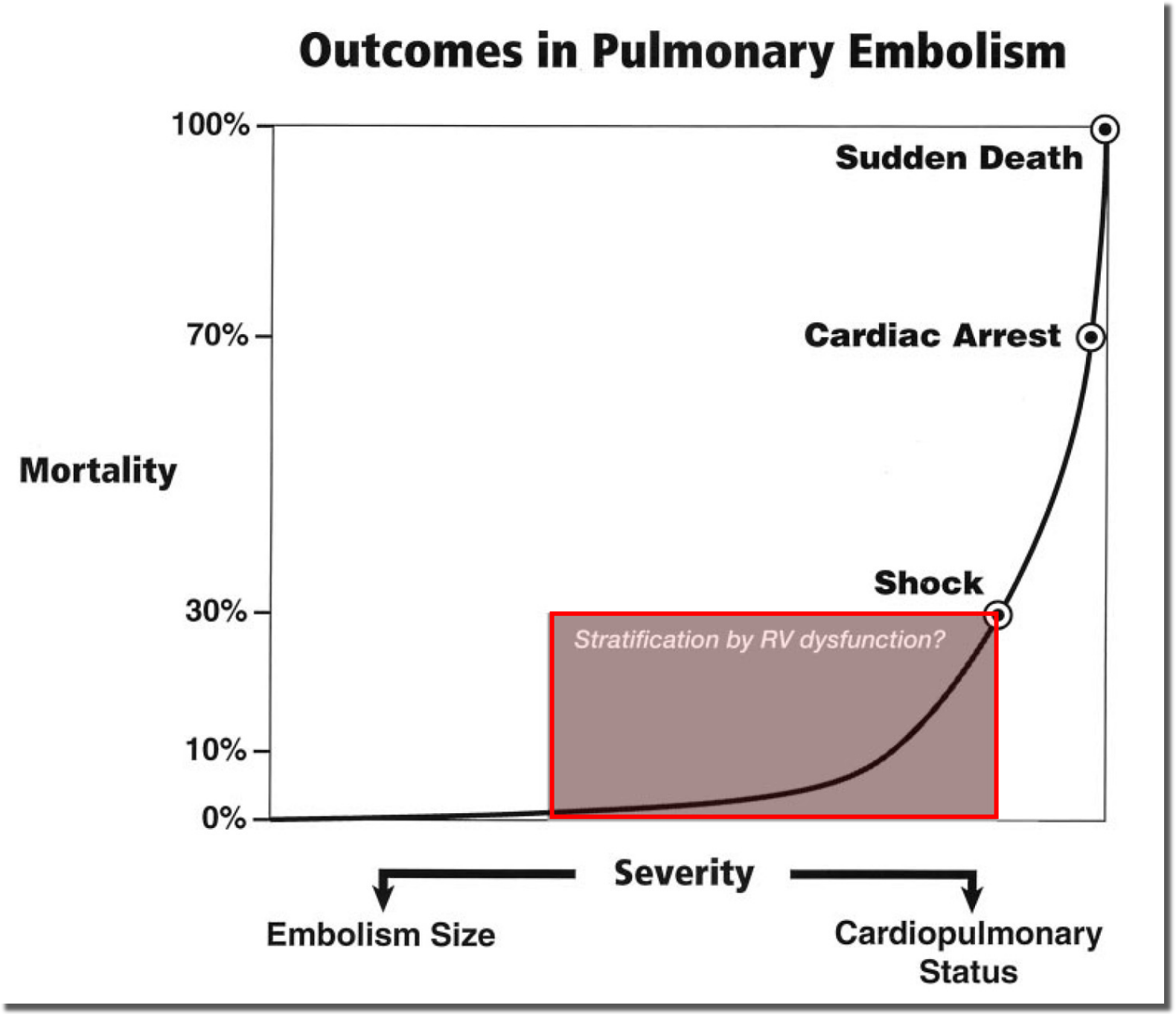

Wood, *Chest*, 2002

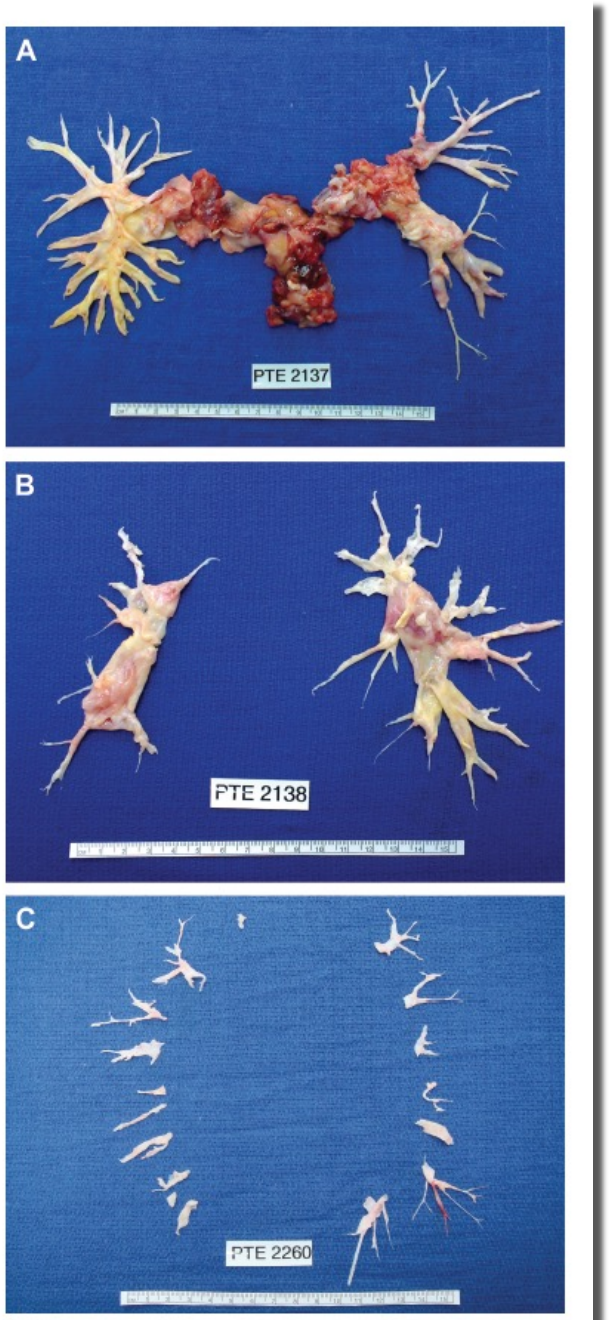

Jaff, Circulation, 2011

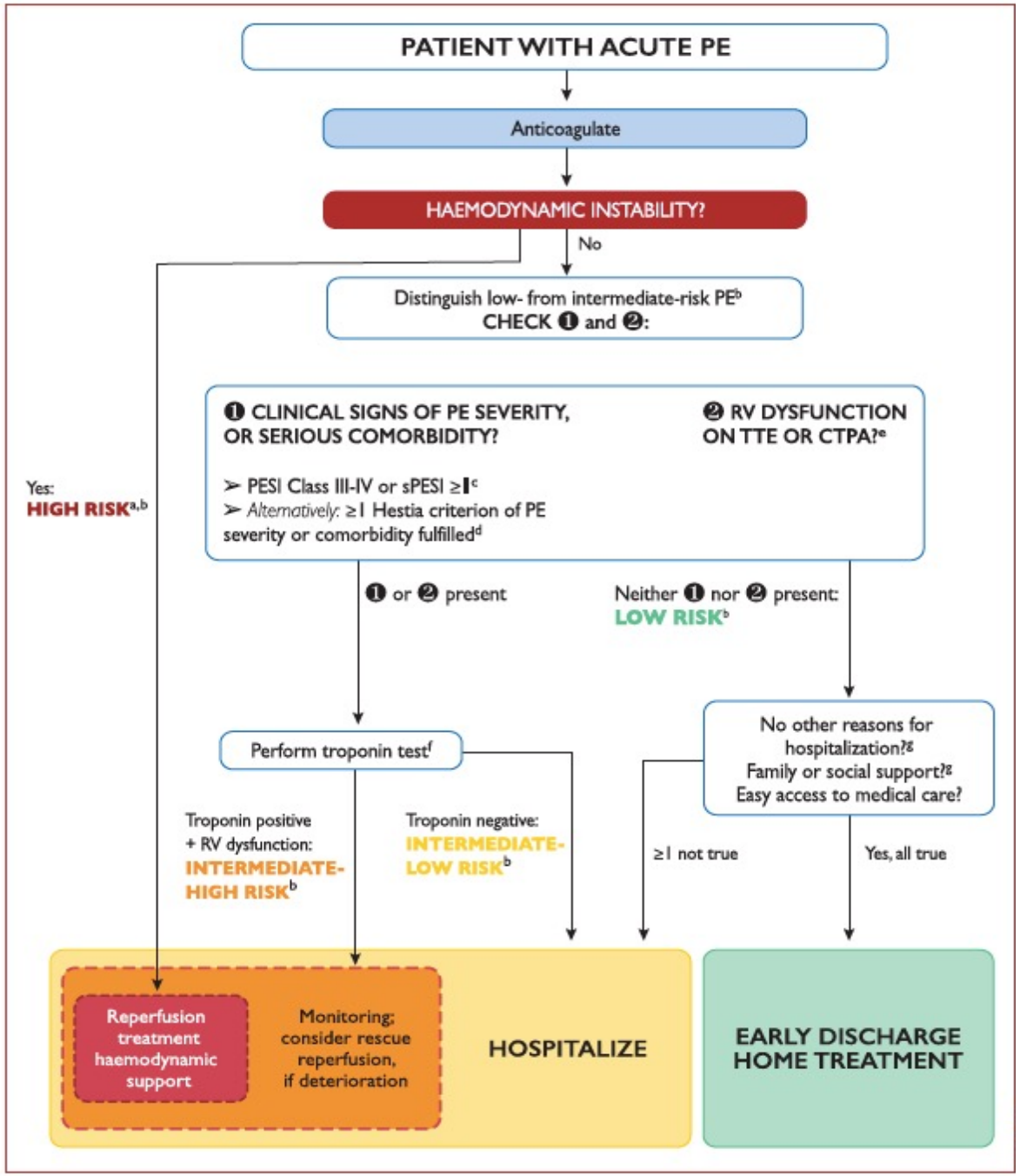

ESC European Society of Cardiology
European Heart Journal (2019) **00**, 1–61
doi:10.1093/eurheartj/ehz405
ESC GUIDELINES

2019 ESC Guidelines for the diagnosis and management of acute pulmonary embolism developed in collaboration with the European Respiratory Society (ERS)

The Task Force for the diagnosis and management of acute pulmonary embolism of the European Society of Cardiology (ESC)

Foto FLapo SAMU 93
SAMU
SAMU 93
SAMU 93
ASSISTANCE PUBLIQUE HÔPITAUX DE PARIS
SAMU
15
DL 957 HT
@fredlapo93
frederic.lapostolle@aphp.fr

Cardiac
MI: 0.8
TI: 0.6
GE Healthcare
Vscan

Consolidations alvéolaires

352 patients avec suspicion d'embolie pulmonaire

Echographie	Probabilité
> 2 lésions à base pleurale	VPP : 99%
1 lésion + épanchement pleural	Probable
1 lésion < 5 mm ou épanchement pleural	Possible
Normal	Nulle

Mathis, *Chest*, 2005

Consolidations alvéolaires

352 patients avec suspicion d'embolie pulmonaire

Echographie	Probabilité
Embolie pulmonaire	**194 (55%)**
Lésion à base pleurale 333 lésions de : 15,5 x 12,4 mm	144 (74%) 2,3 par patient
Epanchement pleural	95 (49%)

Mathis, *Chest*, 2005

Table 4. Diagnostic accuracy of US diagnosis

	Sens % (95% CI)	Spec % (95% CI)	PPV % (95% CI)	NPV % (95% CI)	+LR (95% CI)	-LR (95% CI)
Heart failure	88% (85.1-90.6)	96% (95-96.8)	85.8% (82.8-88.5)	96.6% (95.8-97.4)	21.73 (17.61-26.82)	0.12 (0.10-0.16)
Acute coronary syndrome	47.6% (32-63.6)	99.6% (99.2-99.8)	62.5% (43.7-78.9)	99.2% (98.8-99.5)	104.8 (54.85-200.26)	0.53 (0.39-0.70)
Pneumonia	88.5% (86.4-90.3)	91.6% (90.1-92.9)	87.7% (85.6-89.6)	92.1% (90.7-93.4)	10.47 (8.90-12.32)	0.13 (0.11-0.15)
Pleural effusion	77.6% (68-85.4)	99.2% (98.8-99.5)	78.4% (68.8-86.1)	99.2% (98.7-99.5)	95.46 (61.54-148.09)	0.23 (0.16-0.33)
Pericardial effusion	86.4% (72.7-94.8)	99.7% (99.5-99.9)	84.4% (70.5-93.5)	99.8% (99.5-99.9)	325.59 (153.94-688.65)	0.14 (0.06-0.29)
COPD/asthma	86.8% (84.2-89.2)	96.1% (95.1-96.9)	89.7% (87.2-91.8)	94.9% (93.8-95.8)	21.98 (17.60-27.45)	0.14 (0.11-0.16)
Pulmonary embolism	40% (30.1-50.6)	99.9% (99.7-100)	92.7% (80.1-98.5)	97.8% (97.2-98.4)	345.07 (108.45-1097.94)	0.60 (0.51-0.71)
Pneumothorax	87.8% (75.2-94.5)	100% (99.8-100)	98.8% (89.1-99.9)	99.8% (99.5-99.9)	4634.67 (289.35-74236.28)	0.12 (0.06-0.27)
ARDS	43.8% (19.8-70.1)	99.5% (99.2-99.7)	35% (15.4-59.2)	99.7% (99.4-99.9)	89.75 (41.29-195.09)	0.57 (0.37-0.87)
Other causes	45.5% (36.4-54.8)	98.8% (98.3-99.2)	64% (52.9-74)	97.5% (96.8-98)	37.57 (25.16-56.08)	0.55 (0.47-0.65)

ALI: Acute Lung Injury, **ARDS**: Acute Respiratory Distress Syndrome, **COPD**: Chronic Obstructive Lung Disease, **NPV**: Negative Predictive Value, **PPV**: Positive Predictive Value, **Sens**: Sensitivity, **Spec**: Specificity, **+LR**: Positive Likelihood Ratio, **-LR**: Negative Likelihood Ratio, **95% CI**: 95% Confidence Interval

ACCEPTED MANUSCRIPT

3.487 patients with dyspnea

Zanobetti, *Chest*, 2017

Cardiac
MI: 0.8
TI: 0.6
GE Healthcare
Vscan

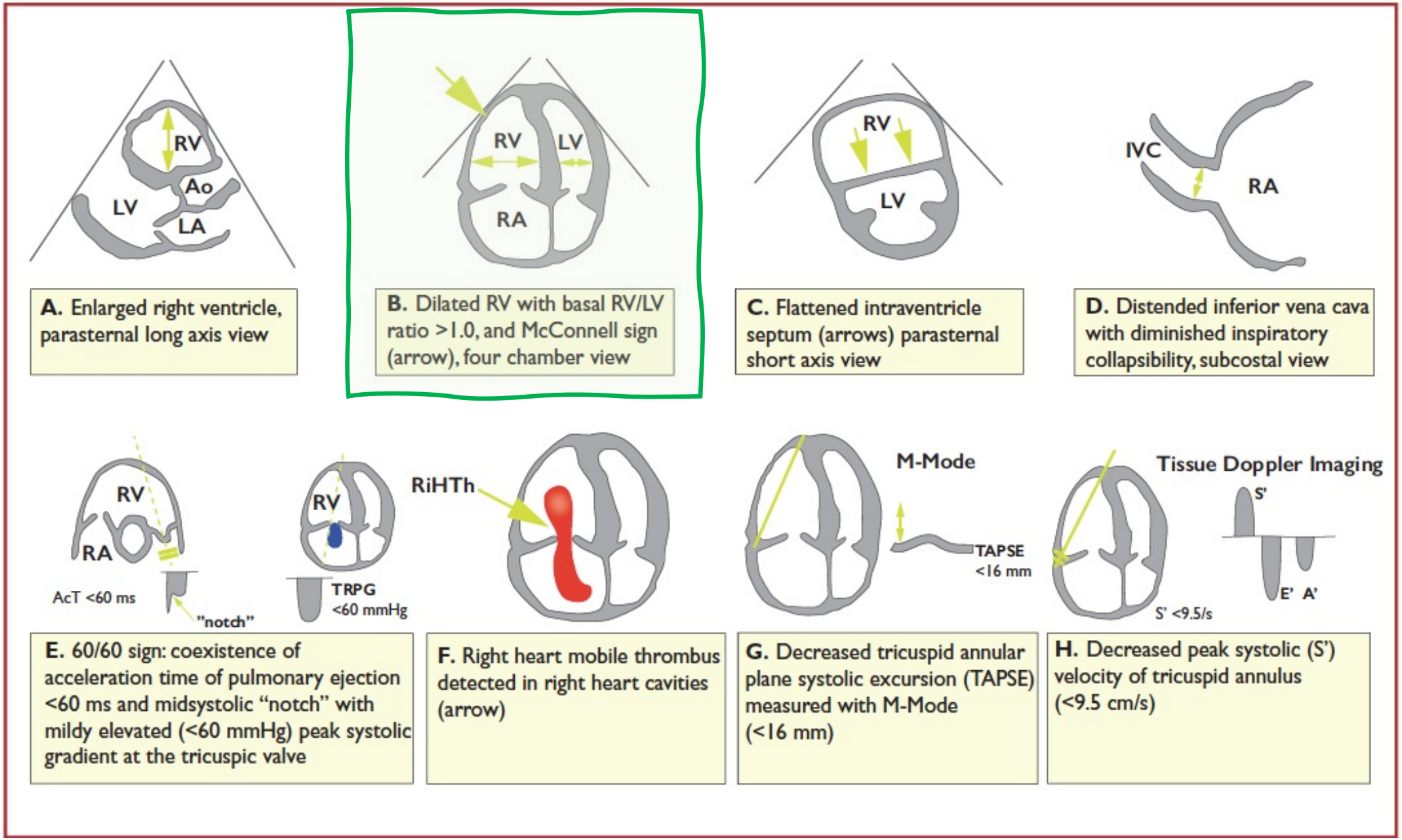

A. Enlarged right ventricle, parasternal long axis view

B. Dilated RV with basal RV/LV ratio >1.0, and McConnell sign (arrow), four chamber view

C. Flattened intraventricle septum (arrows) parasternal short axis view

D. Distended inferior vena cava with diminished inspiratory collapsibility, subcostal view

E. 60/60 sign: coexistence of acceleration time of pulmonary ejection <60 ms and midsystolic "notch" with mildy elevated (<60 mmHg) peak systolic gradient at the tricuspic valve

F. Right heart mobile thrombus detected in right heart cavities (arrow)

G. Decreased tricuspid annular plane systolic excursion (TAPSE) measured with M-Mode (<16 mm)

H. Decreased peak systolic (S') velocity of tricuspid annulus (<9.5 cm/s)

ESC, *Eur Heart J*, 2019

Cardiac
MI: 0.8
TI: 0.6
GE Healthcare
Vscan

Place pour écho - TVP ?

TVP ilio-fémorale

TVP poplitée

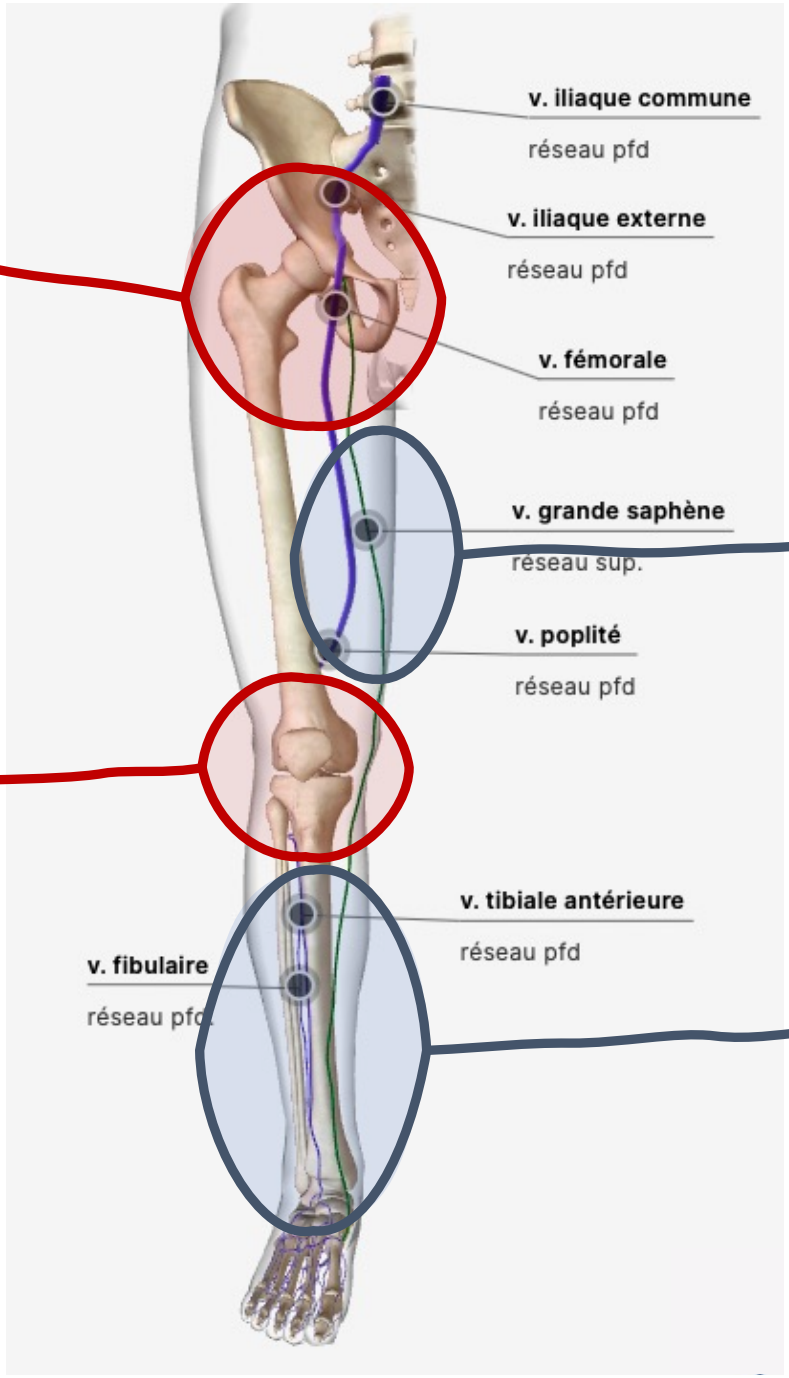

Réseau superficiel

Réseau périphérique

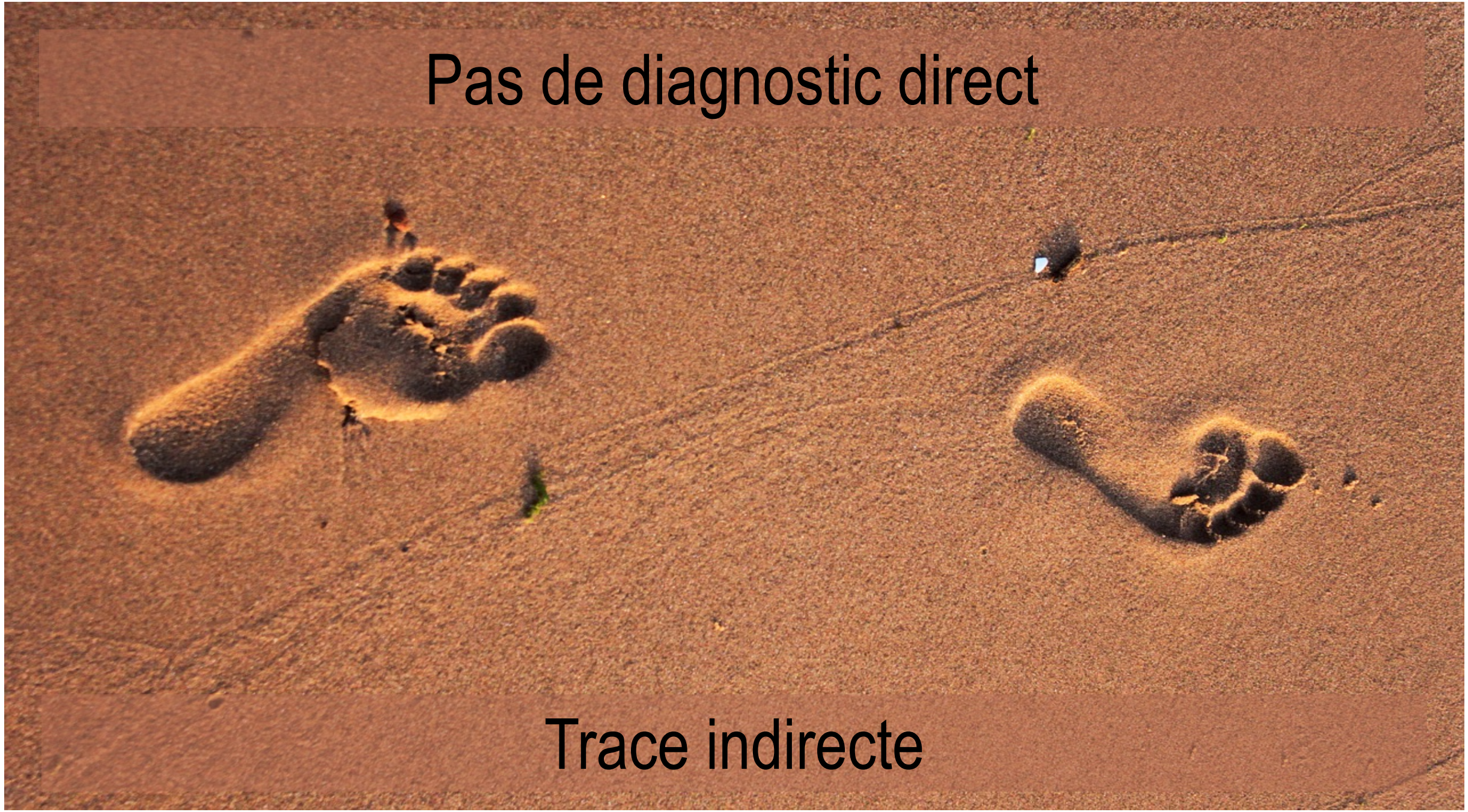
Pas de diagnostic direct
Trace indirecte

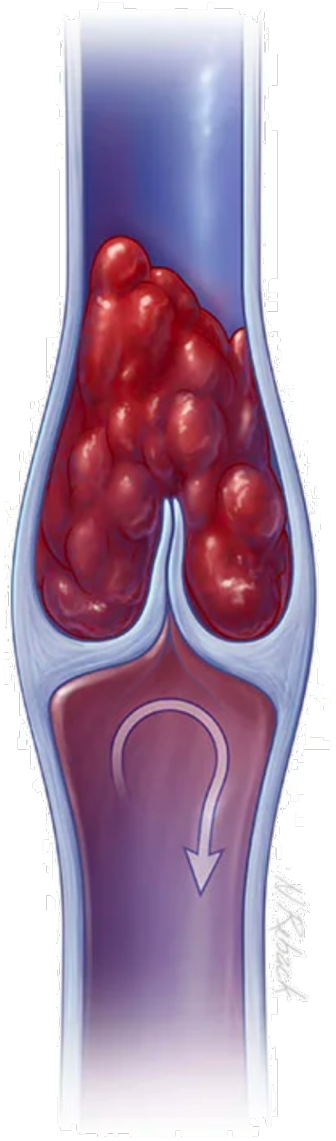

Repérage de la veine

Pression optimale

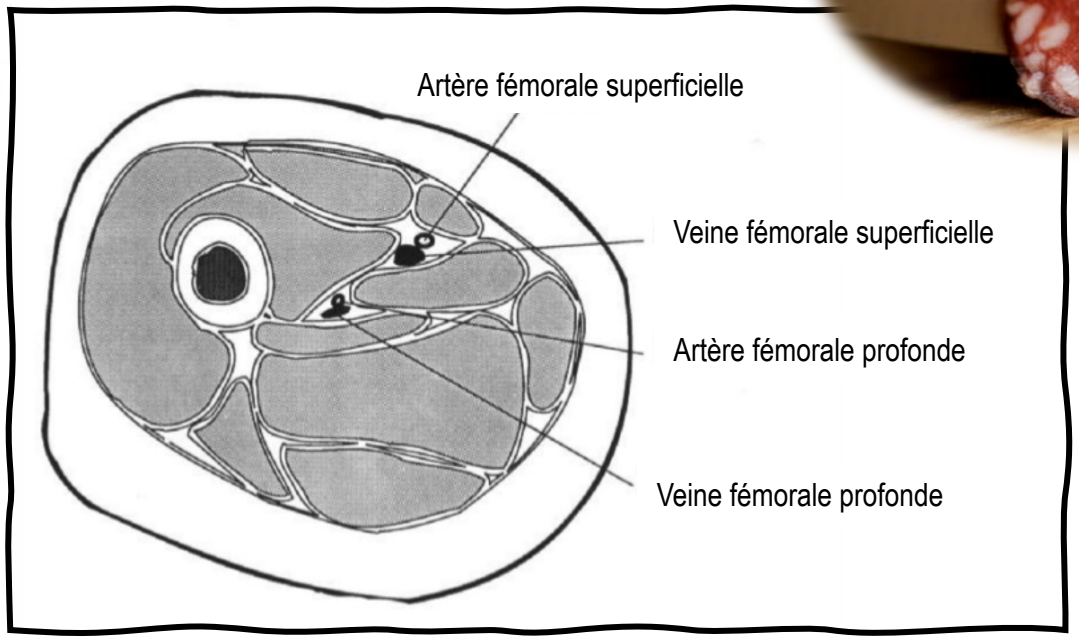
Artère fémorale superficielle
Veine fémorale superficielle
Artère fémorale profonde
Veine fémorale profonde

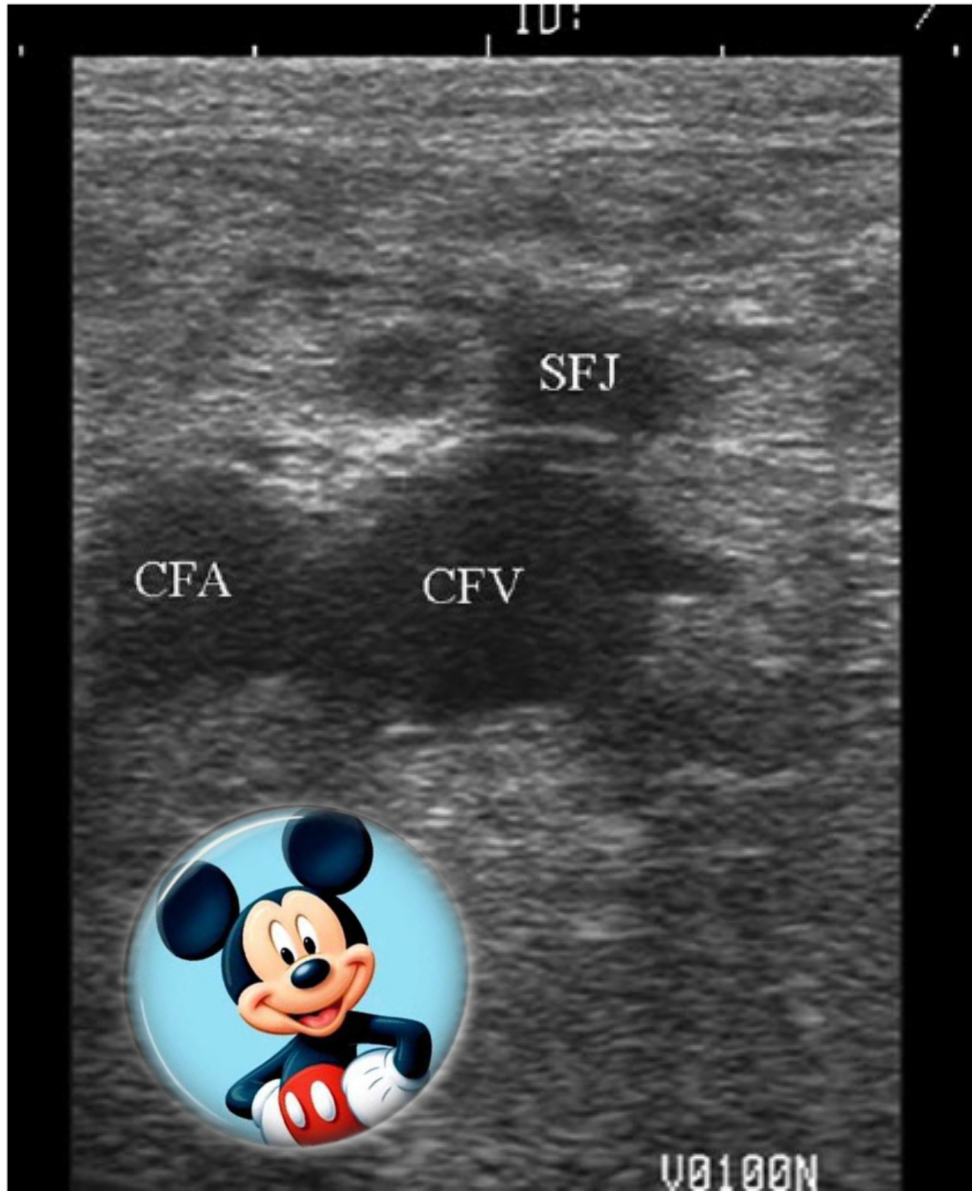
SFJ
CFA
CFV
V0100N

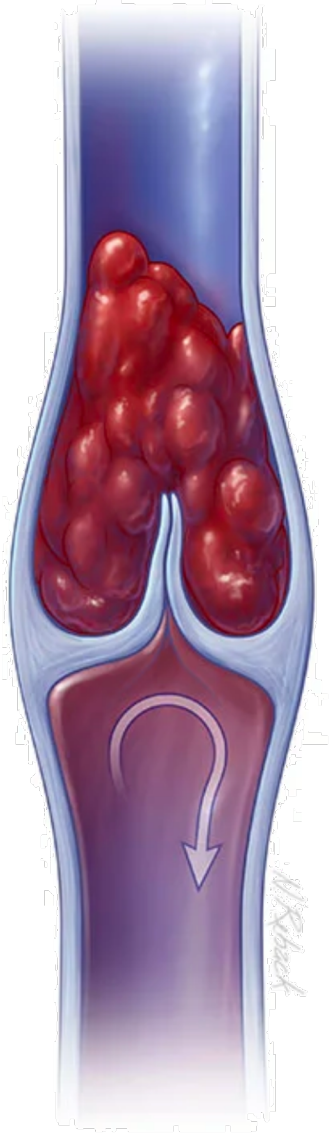

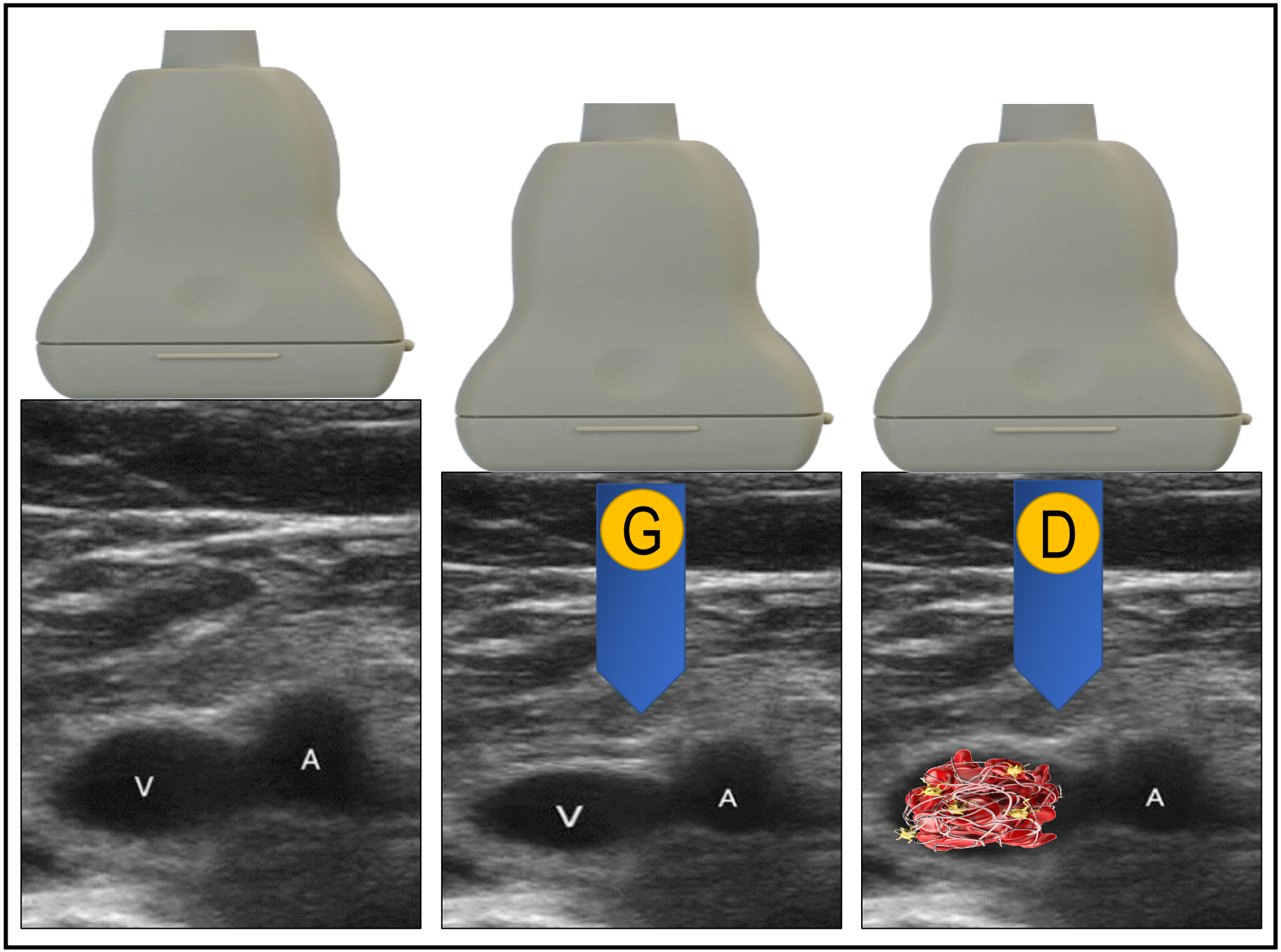
V
A
G
V
A
D
A

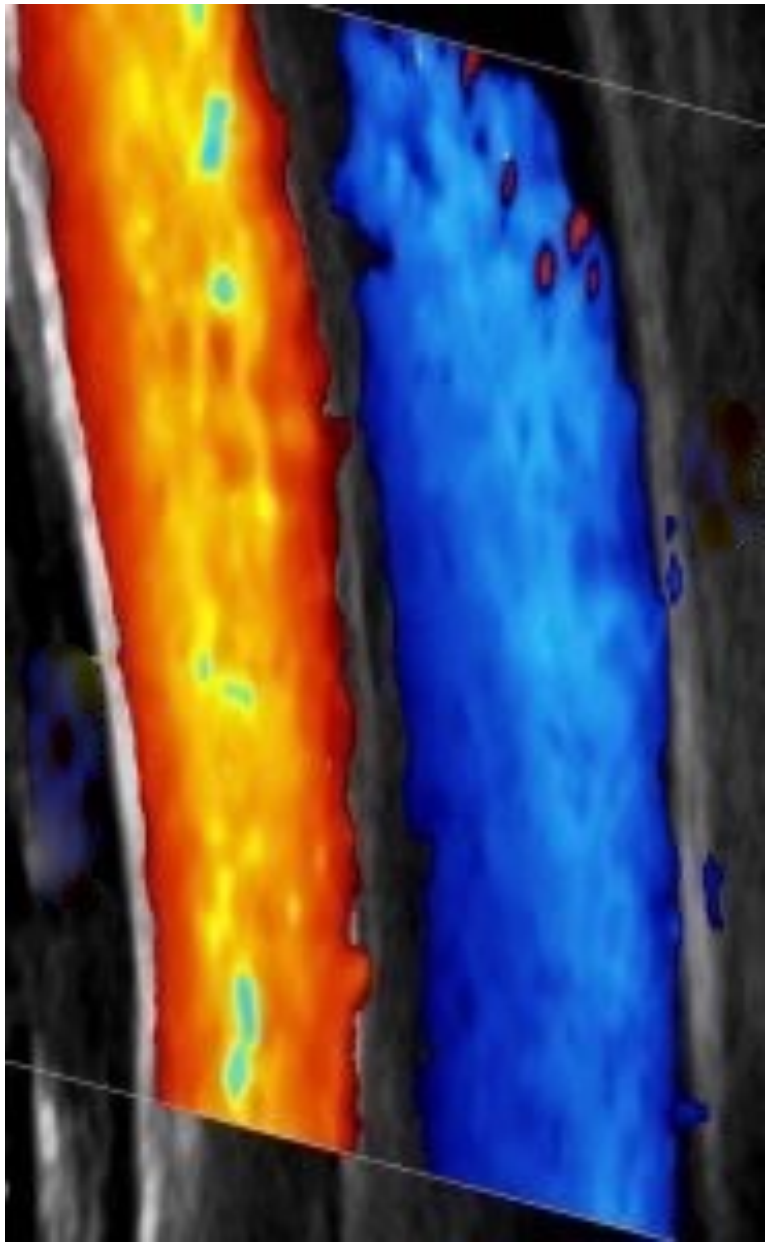



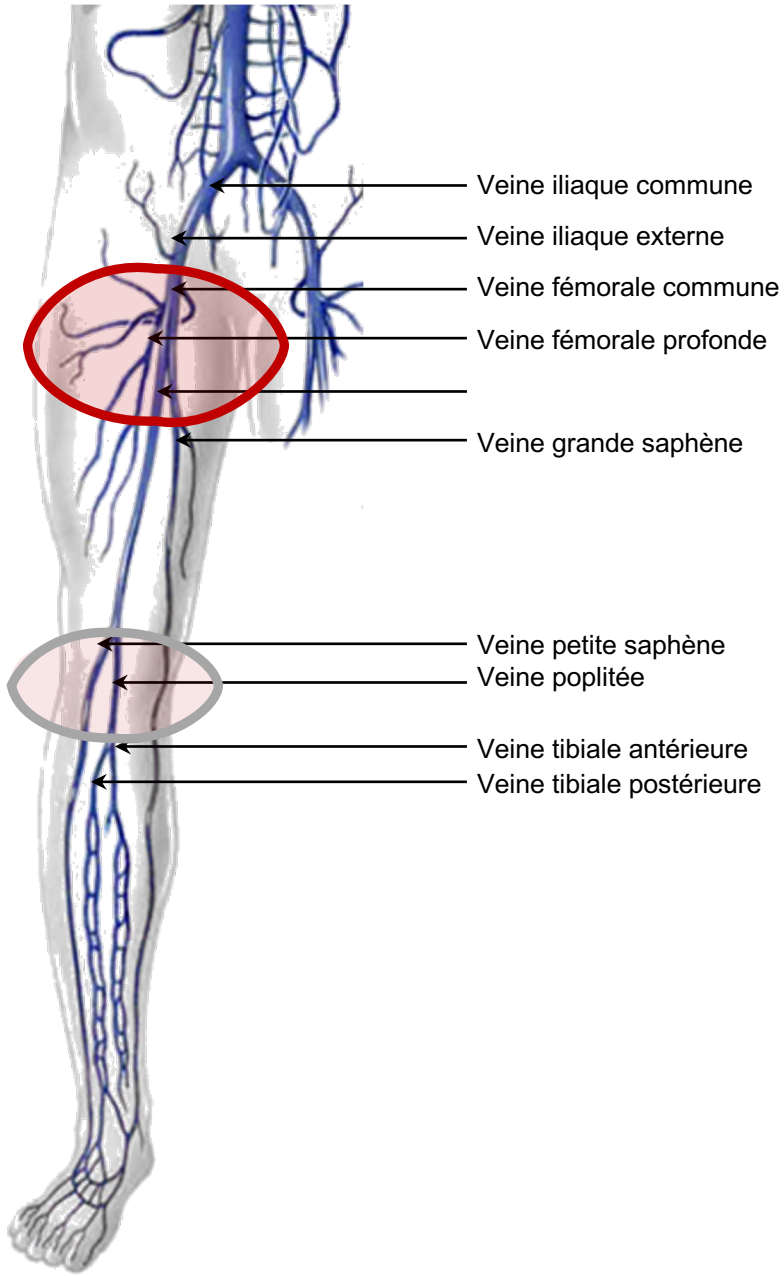
Veine iliaque commune
Veine iliaque externe
Veine fémorale commune
Veine fémorale profonde
Veine grande saphène
Veine petite saphène
Veine poplitée
Veine tibiale antérieure
Veine tibiale postérieure


ÉCHOGRAPHIE D'URGENCE

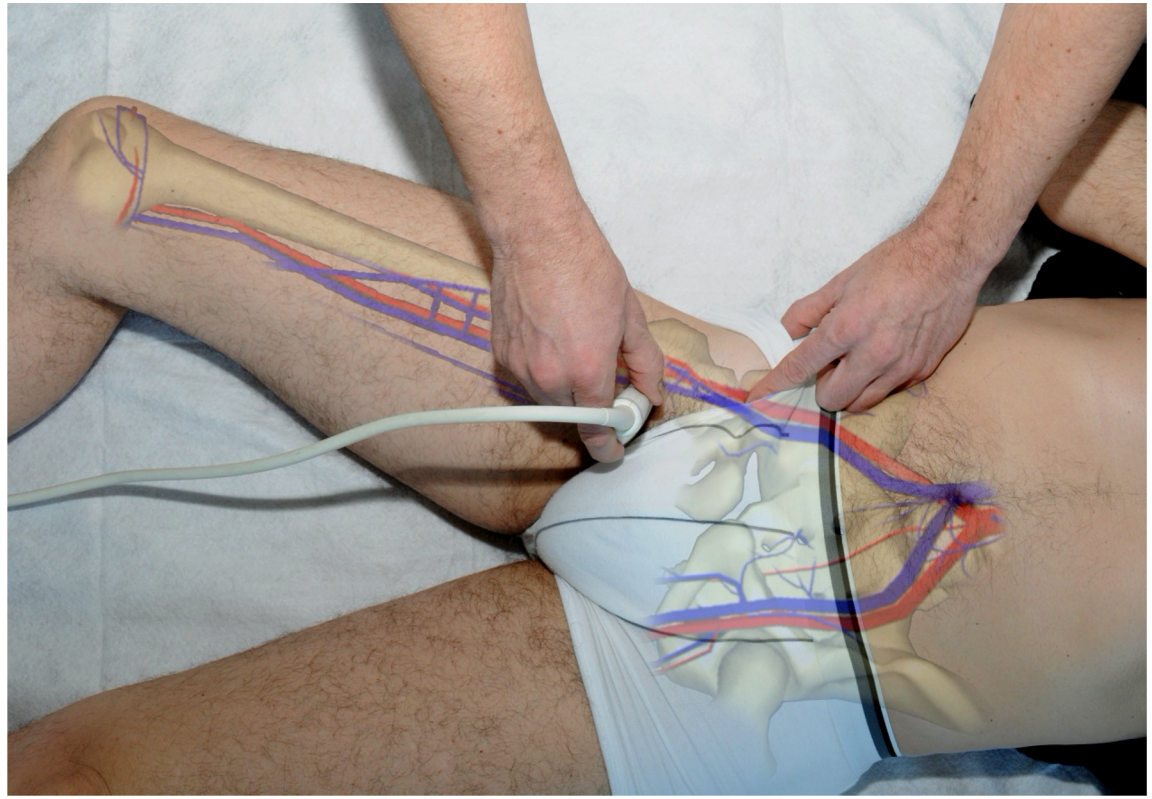

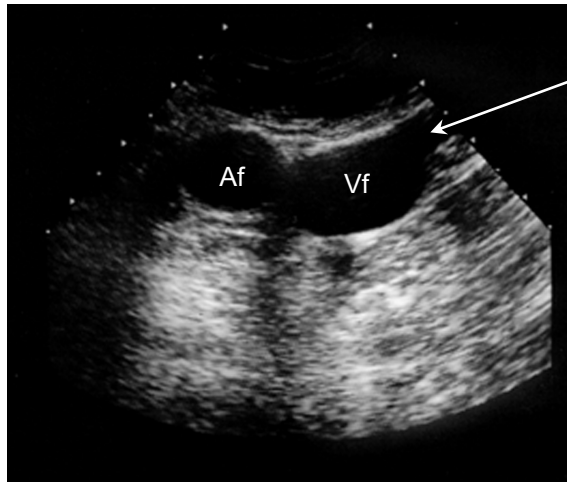
Af
Vf

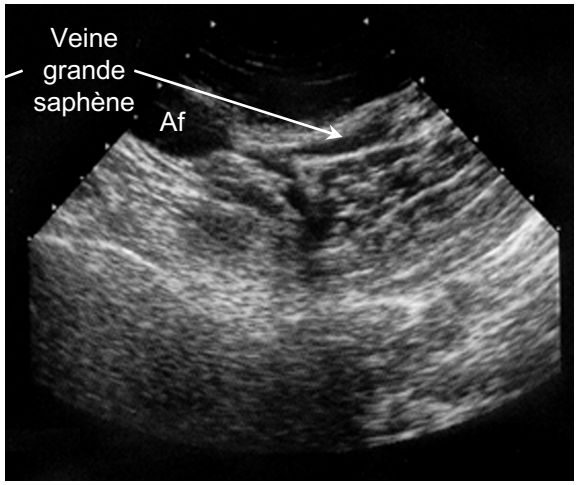
Veine grande saphène
Af

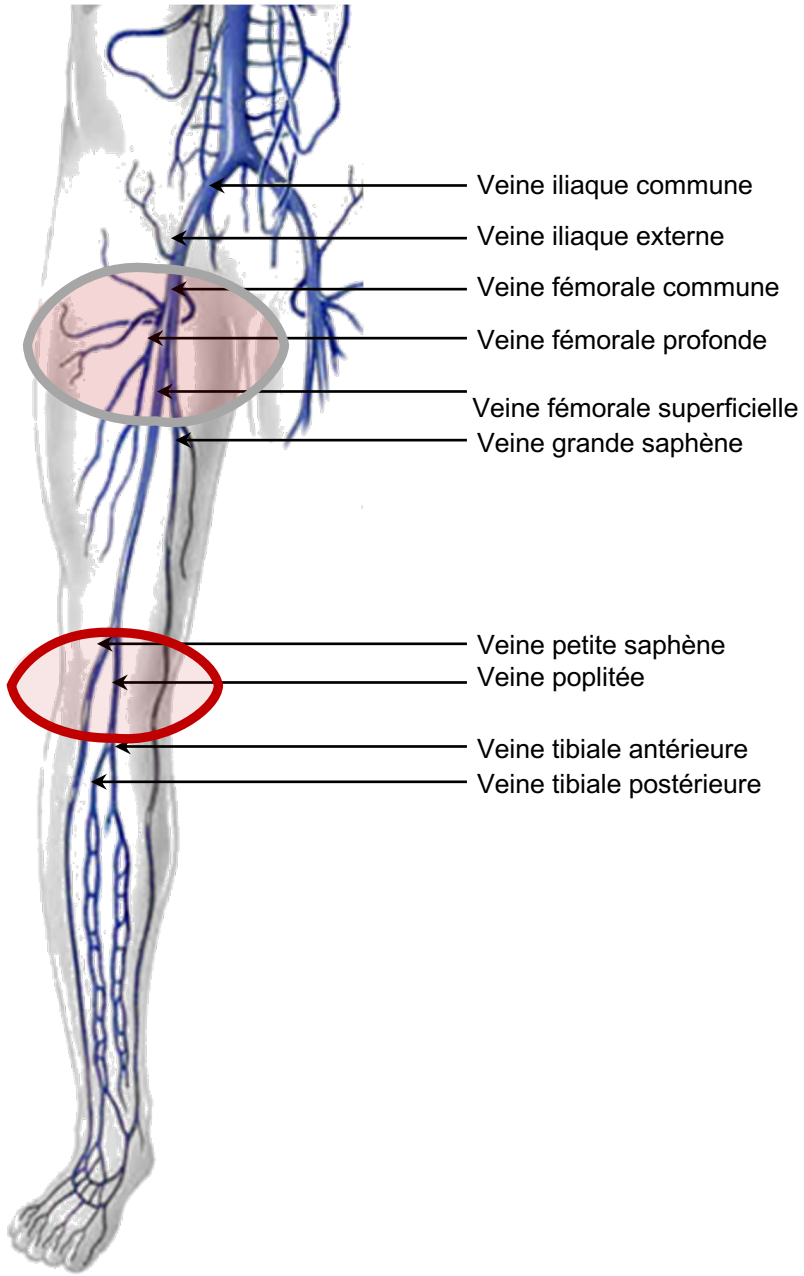
Veine iliaque commune
Veine iliaque externe
Veine fémorale commune
Veine fémorale profonde
Veine fémorale superficielle
Veine grande saphène
Veine petite saphène
Veine poplitée
Veine tibiale antérieure
Veine tibiale postérieure


ÉCHOGRAPHIE D'URGENCE

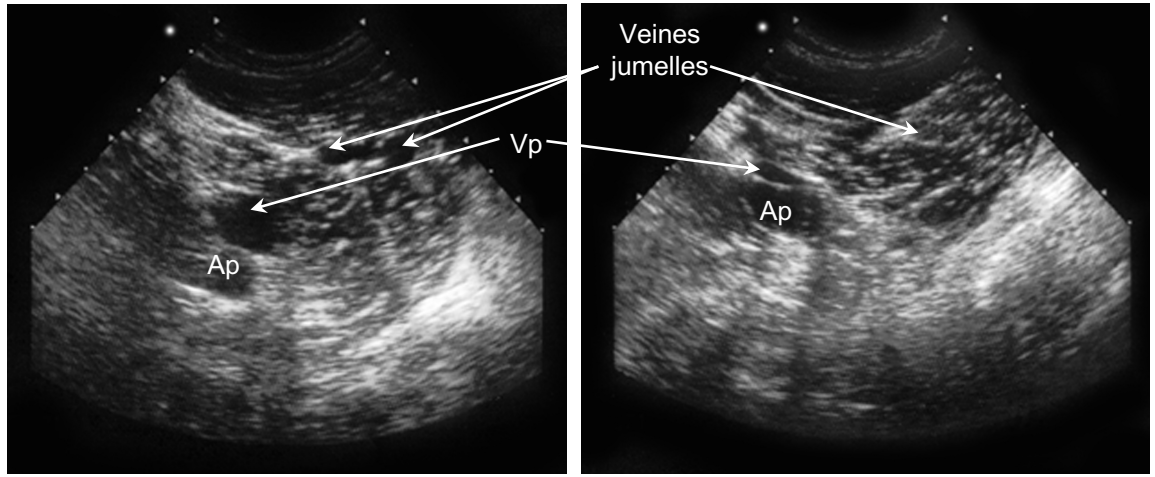
Veines jumelles
Vp
Ap
Ap

Ma, *Emergency Ultrasound*, 2013

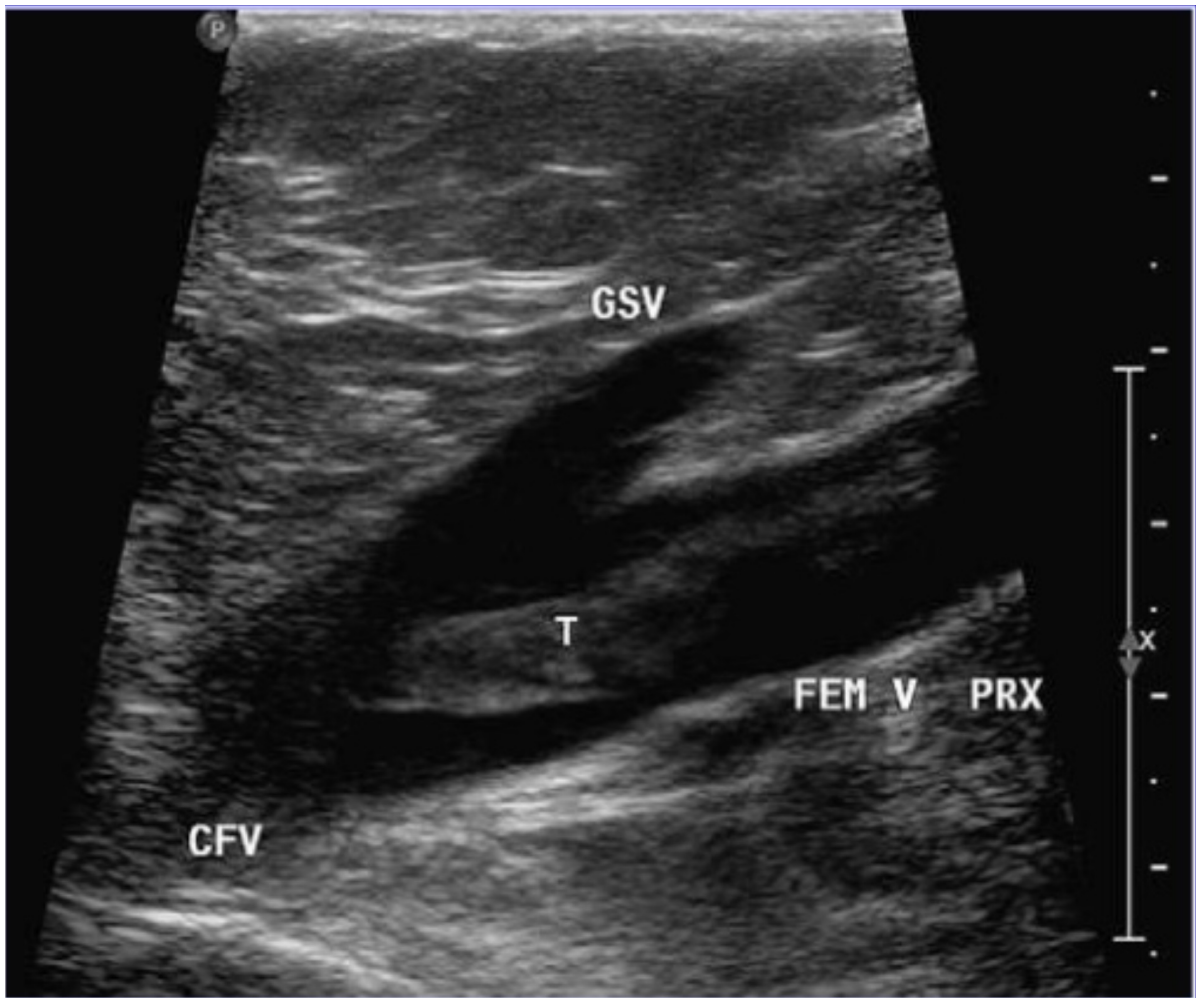

Hamper, *Radiol Clin N Am*, 2007

Formation : de 2 h à 2 h théorique + 3 h pratique

Sensibilité : 89 à 100% & spécificité : 75 à 98%

VPP : 78 à 96% & VPN : 100%

18% de résultats douteux dont 18% TVP

Concordance : 98% (k=0,9)

Durée : 3,5 min

Jolly, *Acad Emerg Med*, 1997 ; Blaivas, *Acad Emerg Med*, 2000 ; Frazee, *J Emerg Med,* 2001 ; Wong, *Ann Emerg Med*, 2003

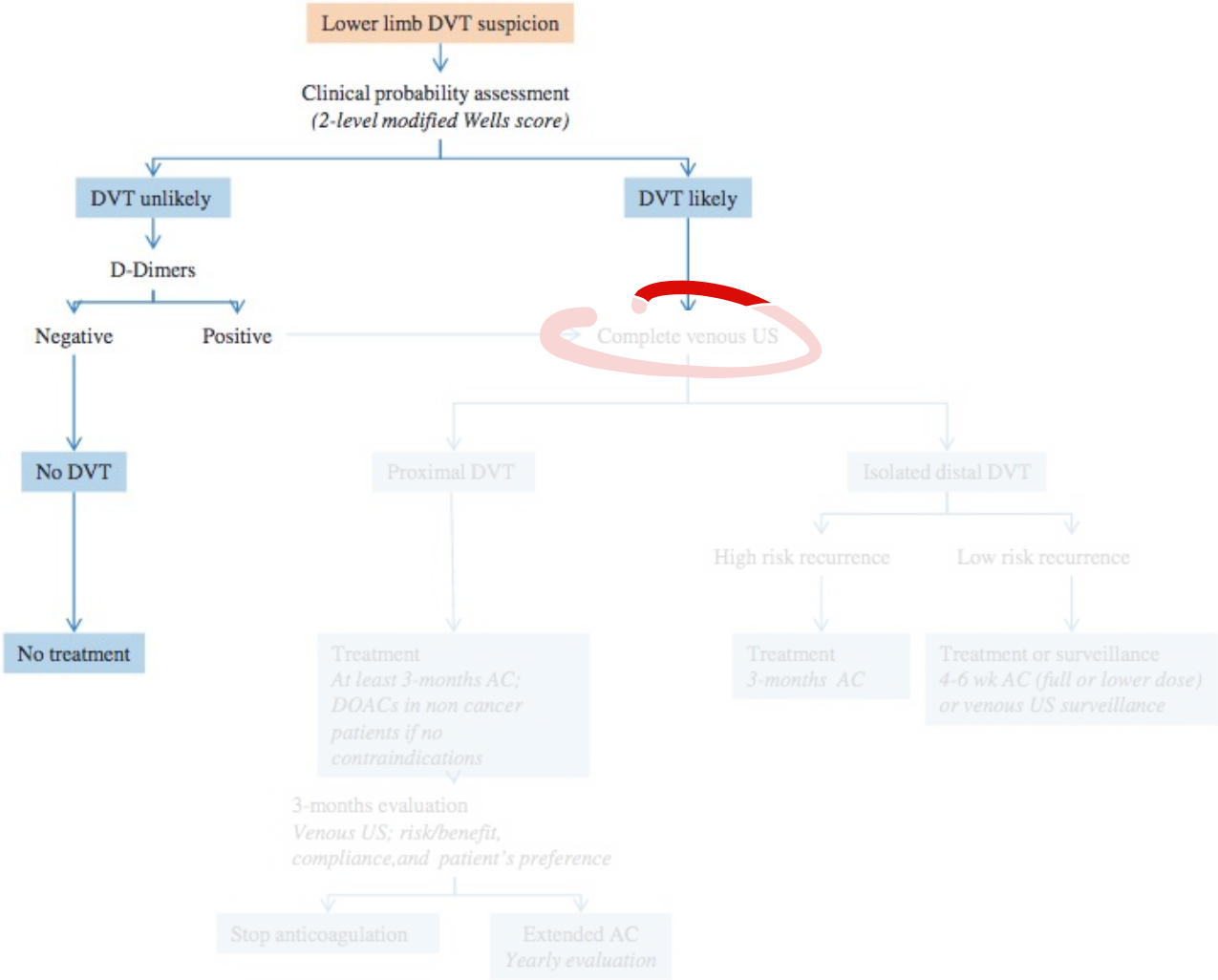

Figure 2 Proposed deep vein thrombosis diagnostic and management algorithm. AC, anticoagulation; DOAC, direct oral anticoagulant.

ESC, *Eur Heart J*, 2018

Imaging

Venous ultrasound (VUS) is the first line DVT imaging modality (other imaging: see Supplementary material online, only section). It is based on B-mode, combined or not with color-Doppler US, and power imaging techniques. DVT diagnostic criteria are cross-sectional vein incompressibility, direct thrombus imaging with vein enlargement, and abnormal spectral and color-Doppler flow. VUS can be performed by examining popliteal and common femoral veins only [2-point/2-region compression venous ultrasonography (CUS) or limited CUS], or by extended imaging of inferior vena cava, iliac and femoral veins, and calf veins (whole-leg VUS or complete VUS). There are controversies as to whether explore symptomatic leg only, or both.[18,19]

In clinically suspected DVT, VUS provides overall sensitivity of 94.2% for proximal, and 63.5% for isolated distal DVT, with an overall specificity of 93.8%.[20] Combination with color-Doppler US increases sensitivity but lowers specificity.[20] When DVT is suspected (without PE symptoms), anticoagulation may be safely withheld in patients with a single normal complete VUS. Same is true for limited CUS provided it can be repeated, and integrated within a diagnostic strategy including clinical probability, and D-dimer assessment.[21] Overall 3-month VTE incidence rate after negative complete VUS is 0.57%,[22] but both methods are reported to be equivalent in randomized trials.[23,24] Complete VUS may be helpful to explain patient's complaint by providing up to 42% alternative diagnosis.[25] Point-of care US performed by emergency physicians using limited CUS has shown good performance (96.1% sensitivity, 96.8% specificity)[26] and may be useful if vascular laboratories are not available 24/7, provided its integration in a validated diagnostic strategy.[27]

In patients with clinically suspected recurrent DVT: comparison of test results with baseline imaging at discontinuation of anticoagulation can safely rule out diagnosis of recurrence.[28] A 2- or 4-mm[29–31] increase in vein diameter between two measurements at the common femoral and popliteal veins, after full compression, is the most validated US criterion.

Deep vein thrombosis with pulmonary embolism symptoms

Diagnostic approach is described in corresponding 2014 European Society of Cardiology (ESC) Guidelines.[6] Proximal DVT confirmation in a normotensive patient with suspected PE essentially confirms VTE and justifies anticoagulation as after formal PE diagnosis. In unstable patients with right ventricular overload but no possibility to confirm PE, CUS showing proximal DVT facilitates initiation of reperfusion therapy. CUS diagnostic yield is high in the presence of clinical DVT signs.[32] Among unselected PE patients, proximal DVT at CUS is found in 1/7 patients.[33] Proximal DVT has high specificity and may justify treatment even if pulmonary CT is negative.[6] While negative CUS

ESC, *Eur Heart J*, 2018

Thrombectomie
Recommandations

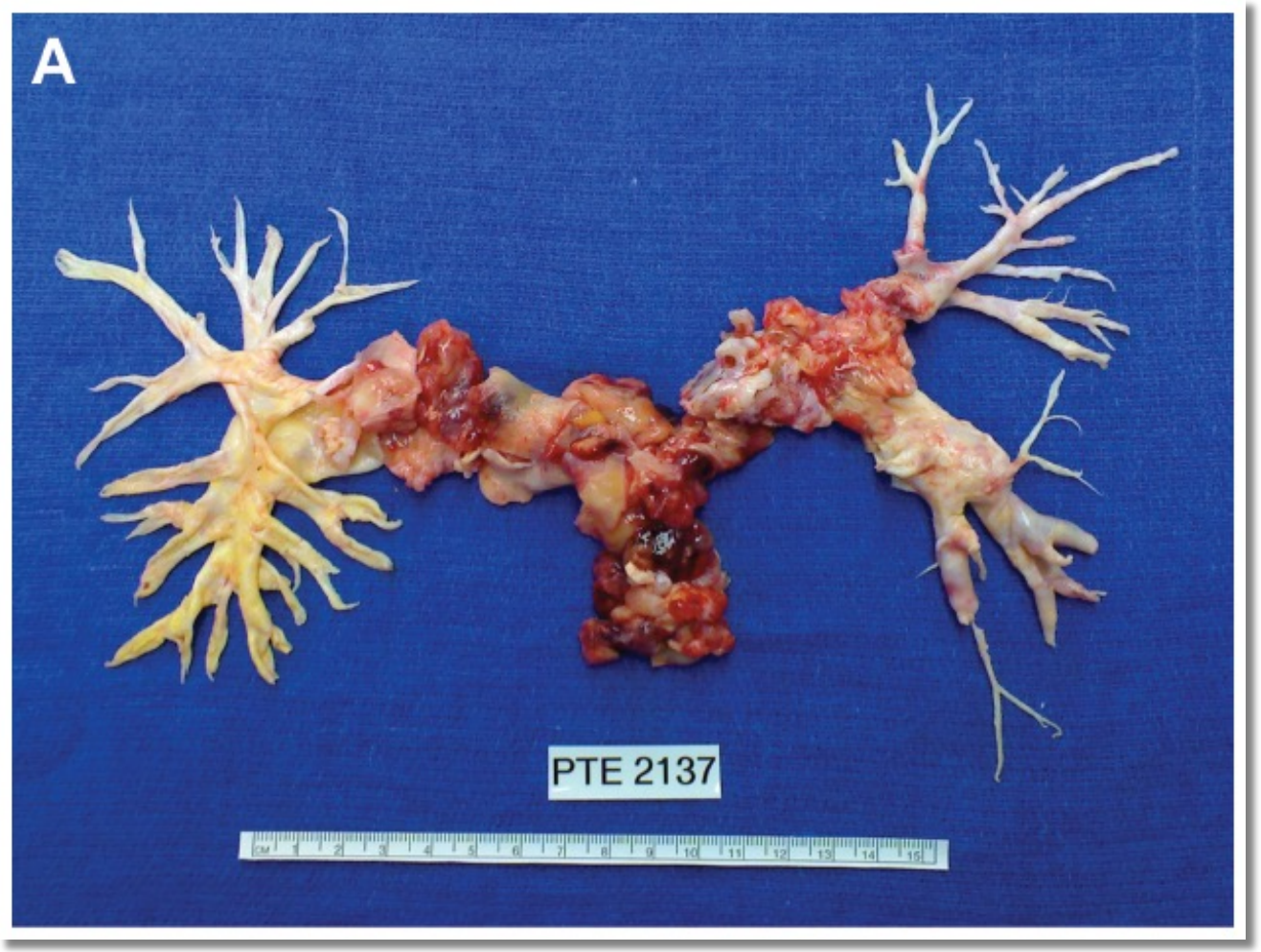

Circulation, 2011

Suspicion d’EP

(Syncope puis) choc

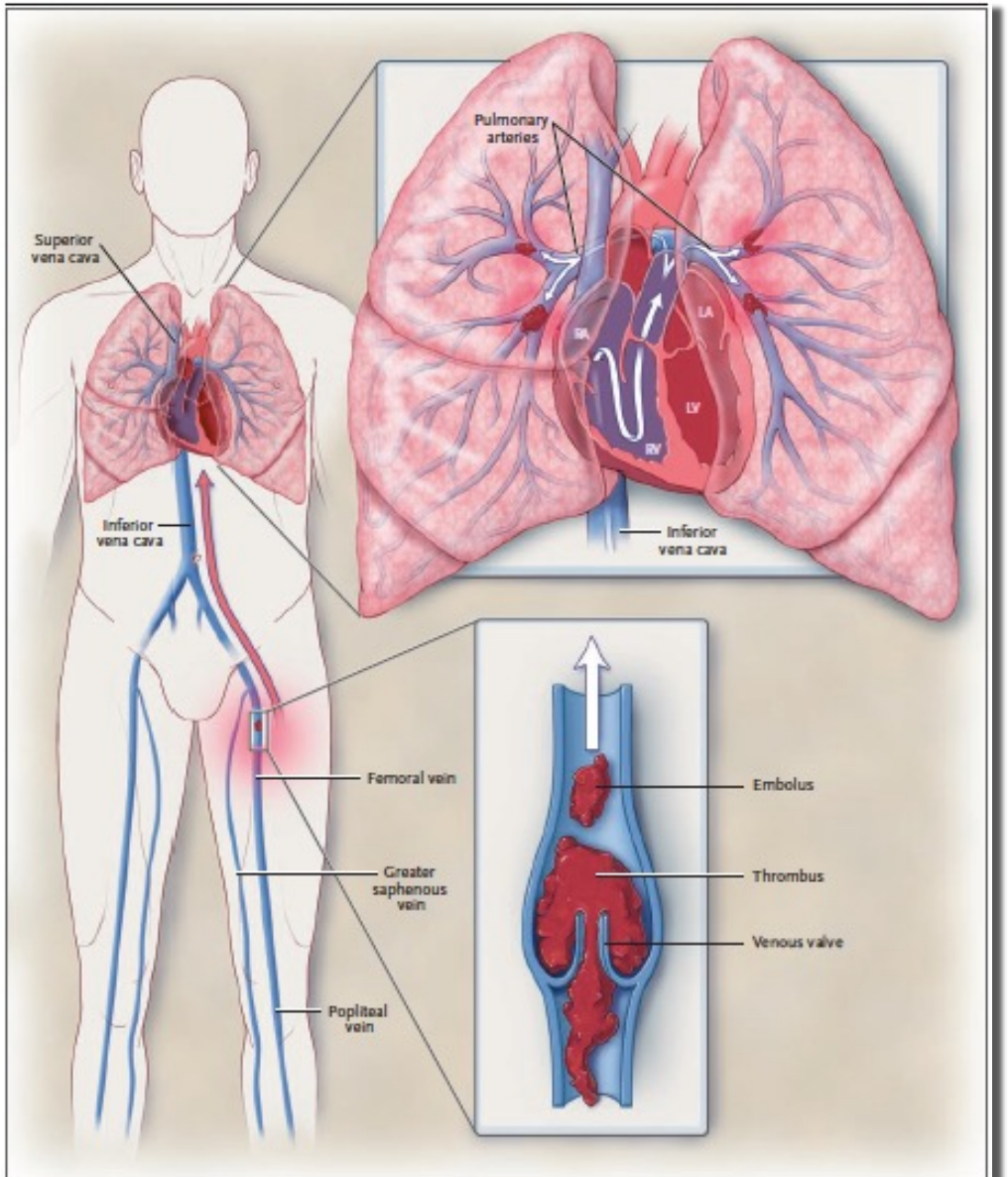

Figure 1. Pathophysiology of Pulmonary Embolism.

Pulmonary embolism usually originates from the deep veins of the legs, most commonly the calf veins. These venous thrombi originate predominantly in venous valve pockets and at other sites of presumed venous stasis (inset, bottom). If a clot propagates to the knee vein or above, or if it originates above the knee, the risk of embolism increases. Thromboemboli travel through the right side of the heart to reach the lungs. LA denotes left atrium, LV left ventricle, RA right atrium, and RV right ventricle.

Tapson, *NEJM*, 2008

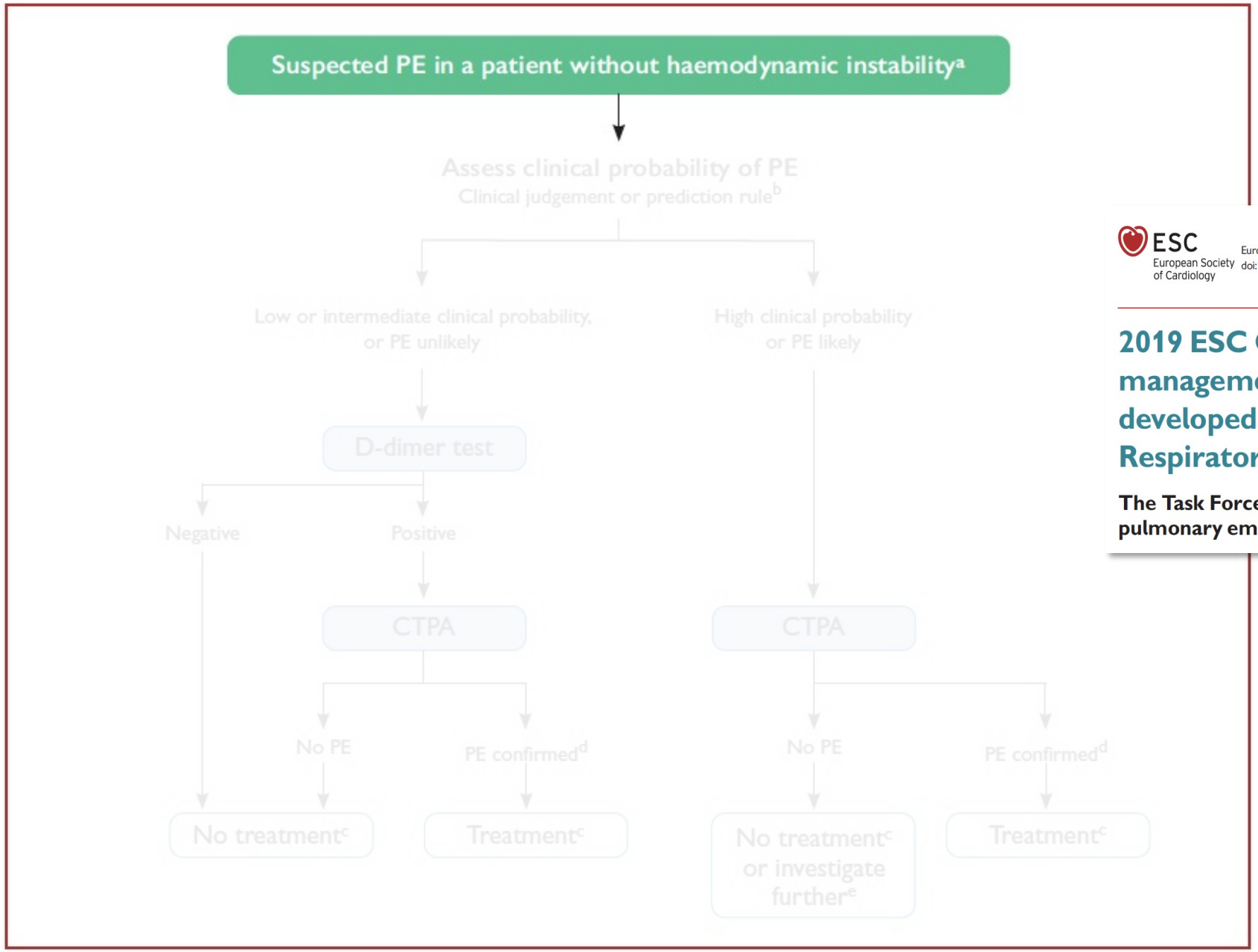

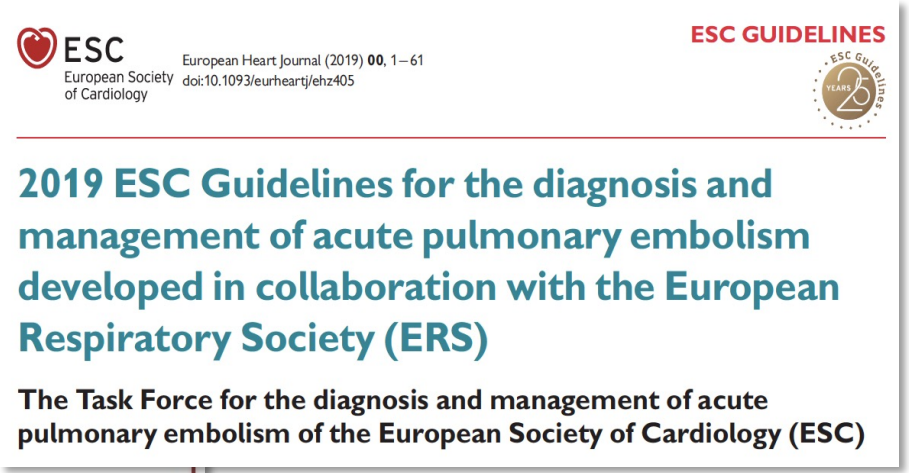
ESC European Society of Cardiology
European Heart Journal (2019) 00, 1–61
doi:10.1093/eurheartj/ehz405
ESC GUIDELINES

2019 ESC Guidelines for the diagnosis and management of acute pulmonary embolism developed in collaboration with the European Respiratory Society (ERS)

The Task Force for the diagnosis and management of acute pulmonary embolism of the European Society of Cardiology (ESC)

ESC, *Eur Heart J*, 2019

ESC
European Society of Cardiology
European Heart Journal (2018) **39**, 4208–4218
doi:10.1093/eurheartj/ehx003

CURRENT OPINION
Pulmonary circulation

Diagnosis and management of acute deep vein thrombosis: a joint consensus document from the European Society of Cardiology working groups of aorta and peripheral vascular diseases and pulmonary circulation and right ventricular function

Lucia Mazzolai[1]*, Victor Aboyans[2], Walter Ageno[3], Giancarlo Agnelli[4], Adriano Alatri[1], Rupert Bauersachs[5,6], Marjolein P.A. Brekelmans[7], Harry R. Büller[7], Antoine Elias[8], Dominique Farge[9], Stavros Konstantinides[6,10], Gualtiero Palareti[11], Paolo Prandoni[12], Marc Righini[13], Adam Torbicki[14], Charalambos Vlachopoulos[15], and Marianne Brodmann[16]

ESC, *Eur Heart J*, 2018

Glissement pleural	Lignes B	Point poumon

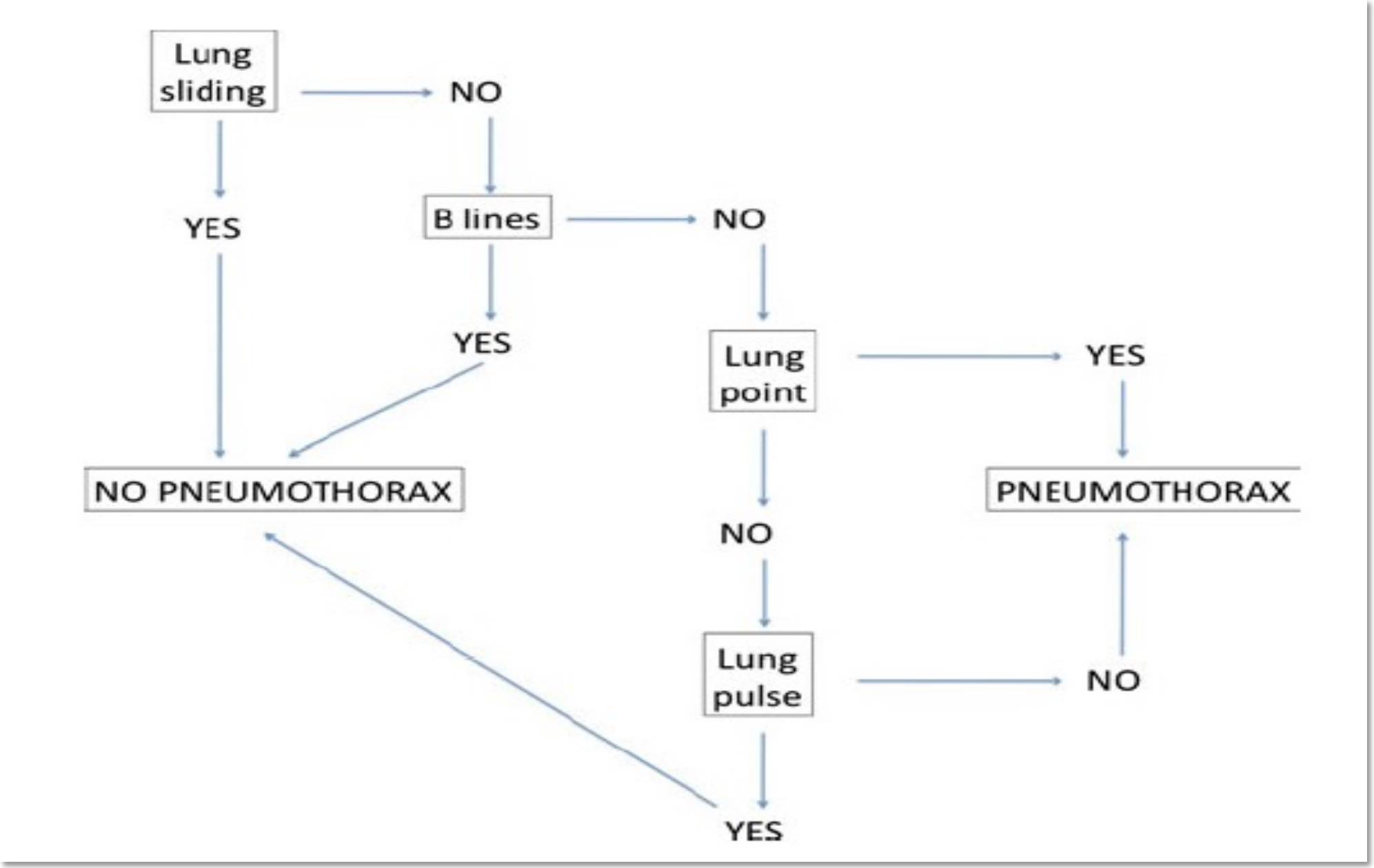

Volpicelli, *Intens Care Med*, 2012