Complications vasculaires du TAVI

P. Commeau

Polyclinique Les Fleurs, Ollioules

Hôpital Saint Joseph, Marseille

CARDIO RUN 2017

PÔLE SANTÉ LES FLEURS

- Pas de conflit d’intérêt pour cette présentation

Complications vasculaires majeures

- Perforation artérielle
- Dissection arterielle (aortique ou iliofemorale)
- Complications locales (FAV, occlusion trépied..)
- Choc hémorragique
- Embolie distale
- Infection

Requérant chirurgie ou stenting

Requérant transfusion sanguine ou entrainant le DC

Requérant chirurgie

Registres initiaux

	POOLED* (503 pts)	SOURCE (1038 pts)	VANCOUVER (250 pts)	PARIS (75 pts)	CA-Multictr (339 pts)
Vascular (maj)** (%)	18.5	10.6	10.3	11.8	13.1
AR >2+ (%)	10.9	4.7	5.0	5.3	7.7
Stroke (%)	4.0	2.5	3.0	4.0	2.3
New Pacemaker (%)	4.4	7.0	5.5	5.3	4.9
Renal Failure (%)	5.2	8.7	4.2	na	2.6
Coronary Obstr (%)	0.4	0.6	na	0	0

* REVIVE, REVIVAL, TRAVERCE, PARTNER EU
** TF Only

CARDIO RUN 2017

PÔLE SANTÉ LES FLEURS

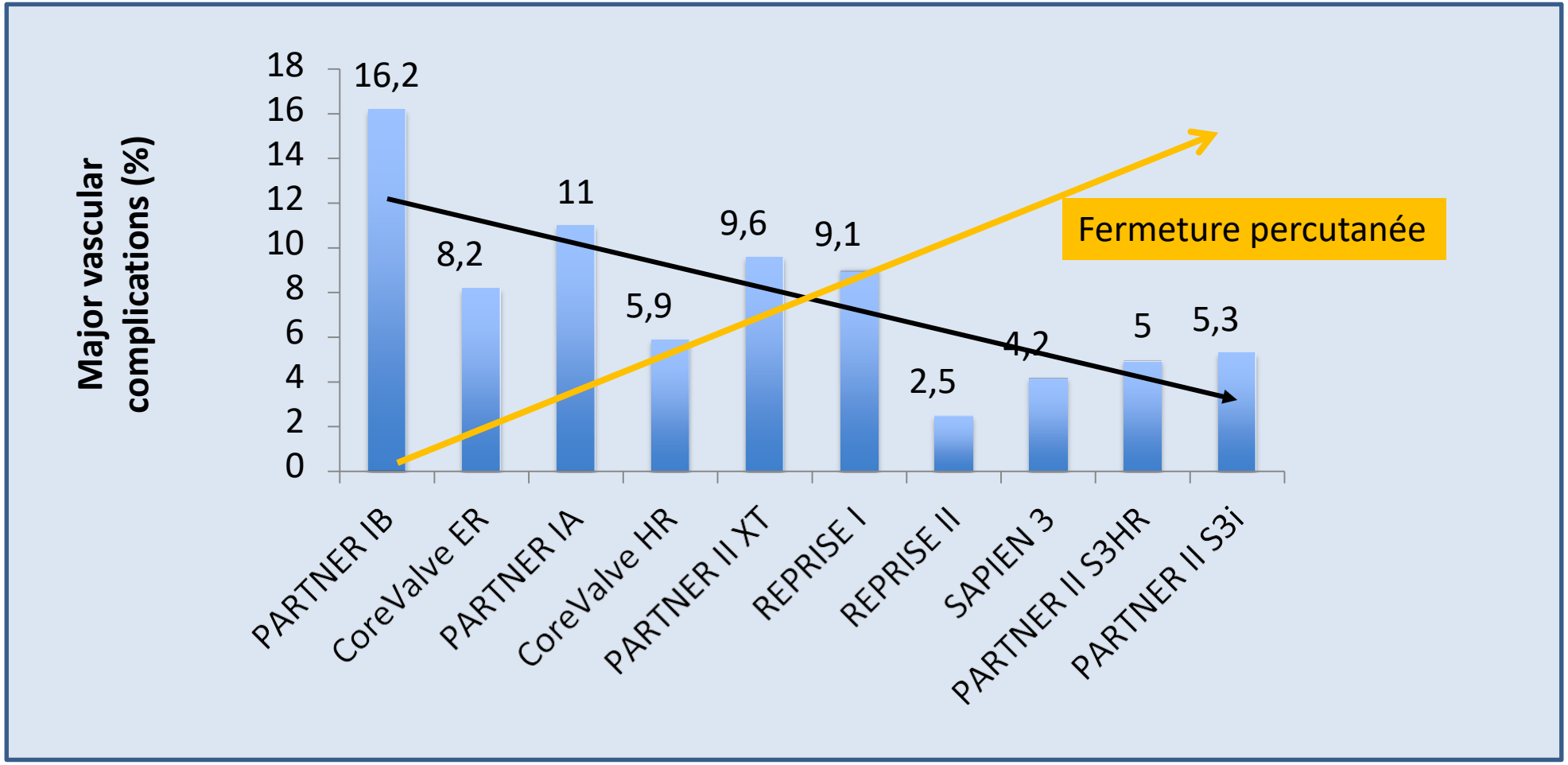



CARDIO RUN 2017

PÔLE SANTÉ LES FLEURS

Other Unadjusted Clinical Outcomes At 30 Days and 1 Year (AT)

THE PARTNER II TRIAL

Events (%)	30 Days		1 Year	
	TAVR (n = 1077)	Surgery (n = 944)	TAVR (n = 1077)	Surgery (n = 944)
Re-hospitalization	4.6	6.8	11.4	15.1
MI	0.3	1.9	1.8	3.1
Major Vascular Complication	6.1	5.4	---	---
AKI (Stage III)	0.5	3.3	---	---
Life-Threatening/Disabling Bleeding	4.6	46.7	---	---
New Atrial Fibrillation	5.0	28.3	5.9	29.2
New Permanent Pacemaker	10.2	7.3	12.4	9.4
Re-intervention	0.1	0.0	0.6	0.5
Endocarditis	0.2	0.0	0.8	0.7

En 2017

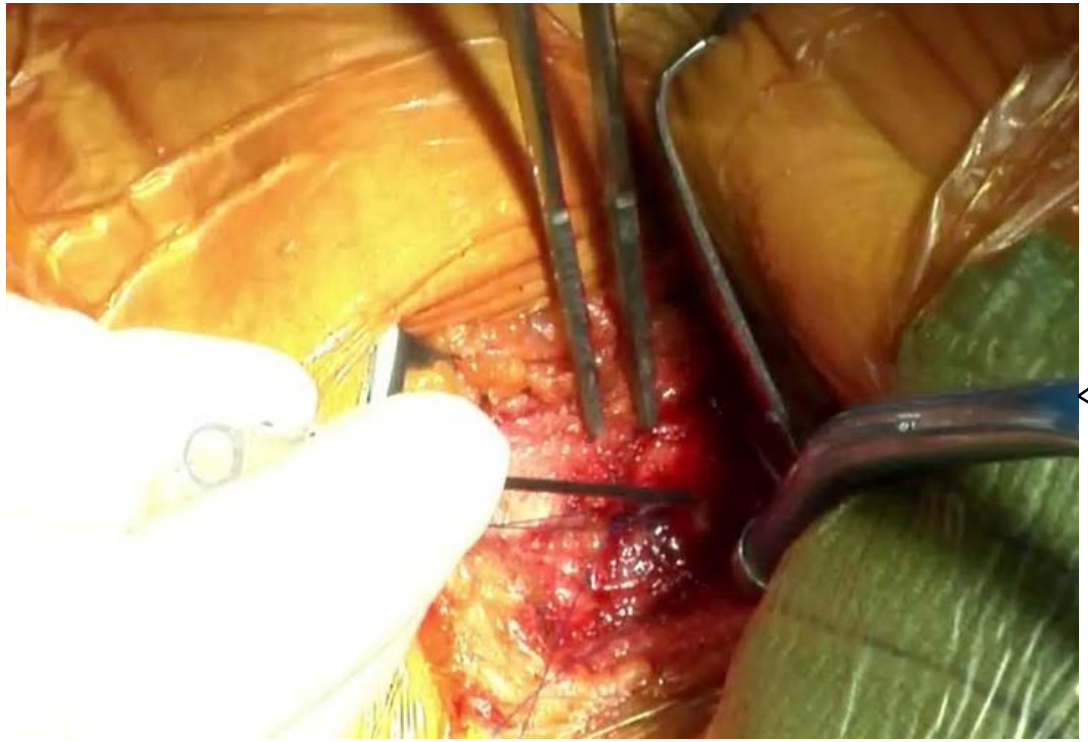

CARDIO RUN 2017

Choix du dispositif

	PROSTAR XL™	PROGLIDE™
PROFIL	10 F	6F
SUTURE	tressée	monofilament
NOEUD	Par l'opérateur	préformé
NOMBRE DE DISPOSITIFS	1 (jusqu'à 24F)	2 (jusqu'à 24F)
SIMPLICITE	+	++

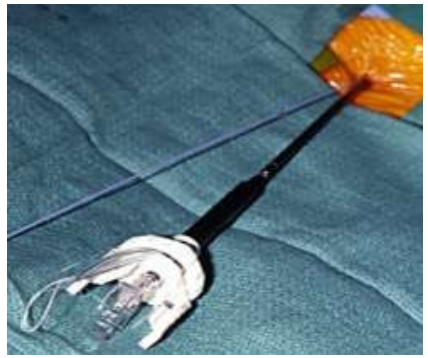

CARDIO RUN 2017

PÔLE SANTÉ LES FLEURS

- Bonne tunnelisation autour du cathéter +++
- Libération des adhérences +++
- Bien individualiser fils par des pinces
- Échange sur guide stiff
- Montée de l’introducteur

L'important c'est le scanner

- Diamètre de l'axe ilio-fémoral
- Rectitude de l'axe
- Localisation et type des calcifications
- Trépied fémoral

CARDIO RUN 2017
PÔLE SANTÉ LES FLEURS

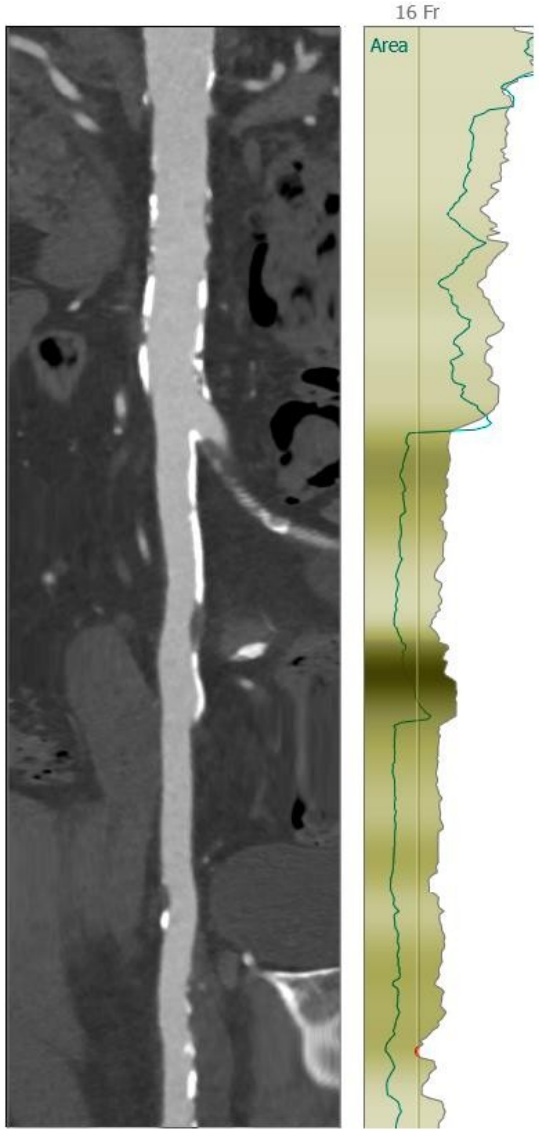

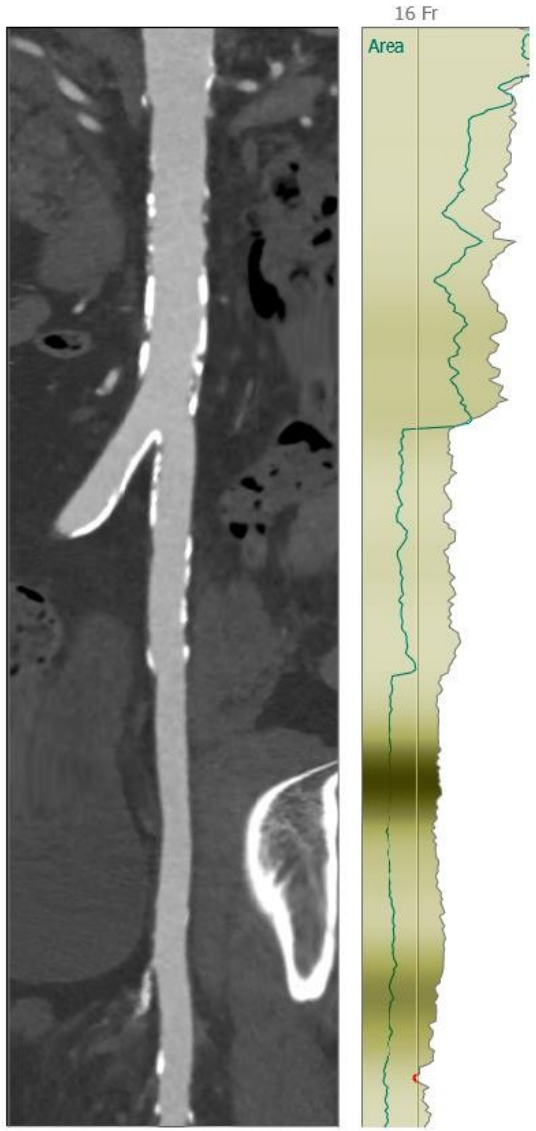

CARDIO RUN 2017

PÔLE SANTÉ LES FLEURS

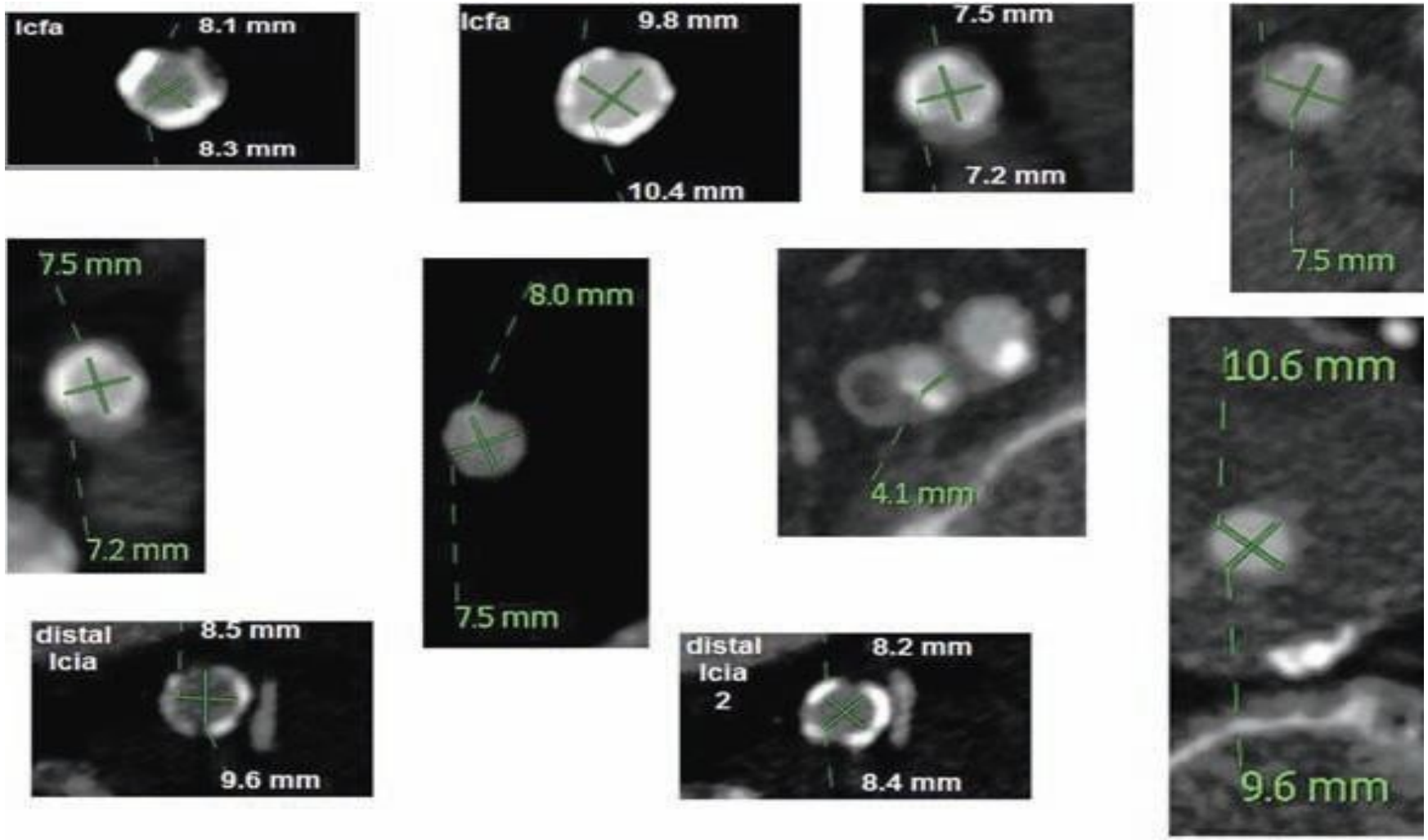

CARDIO RUN 2017
PÔLE SANTÉ LES FLEURS

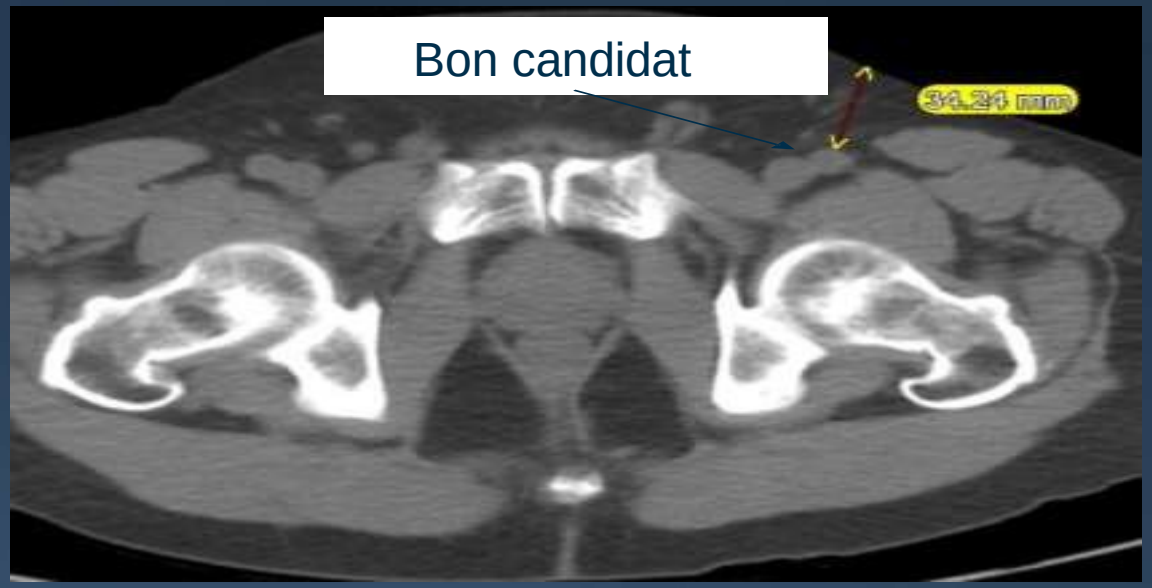

Fuire les artères de petit diamètre et les calcifications circonférentielles +++

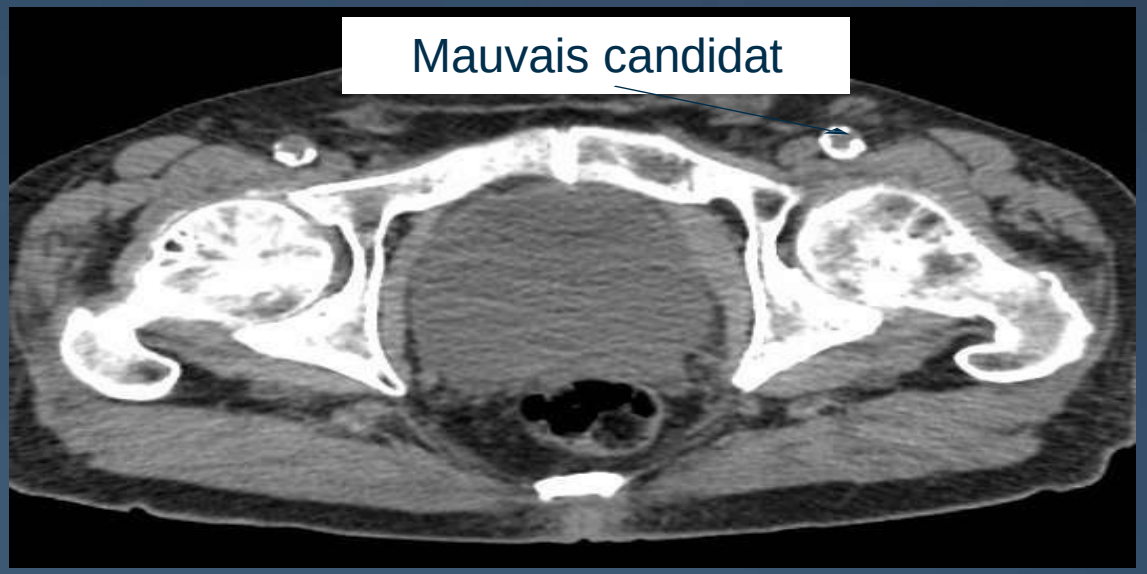

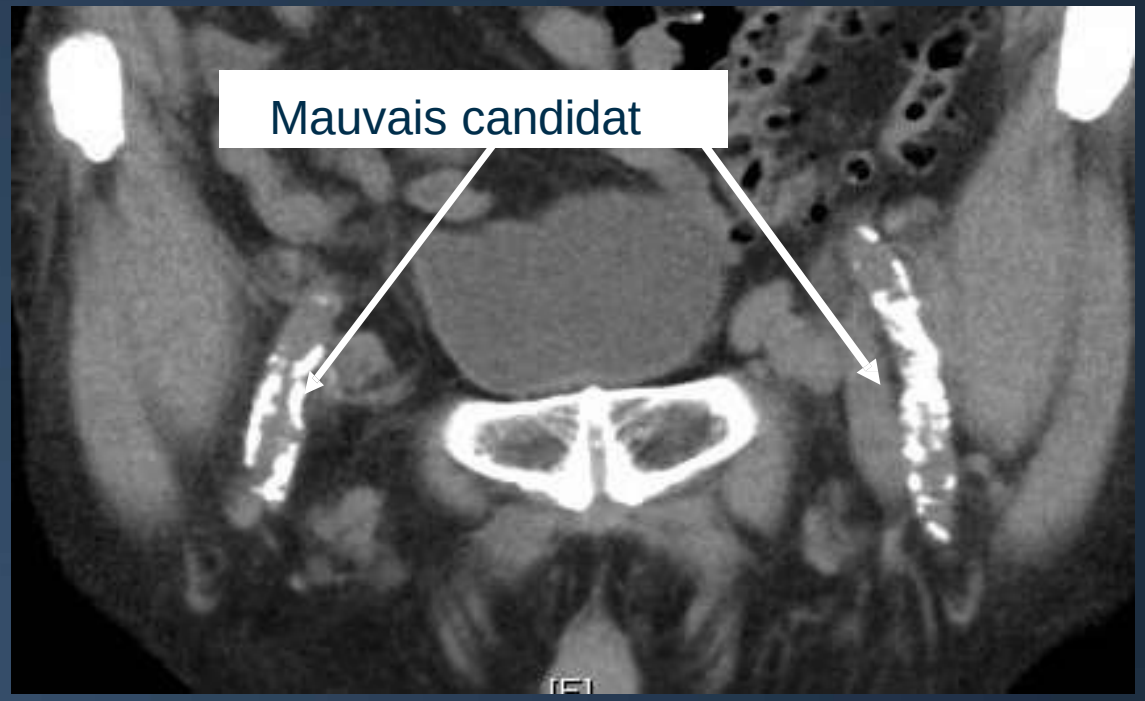

Procédure habituelle

CARDIO RUN 2017

PÔLE SANTÉ LES FLEURS

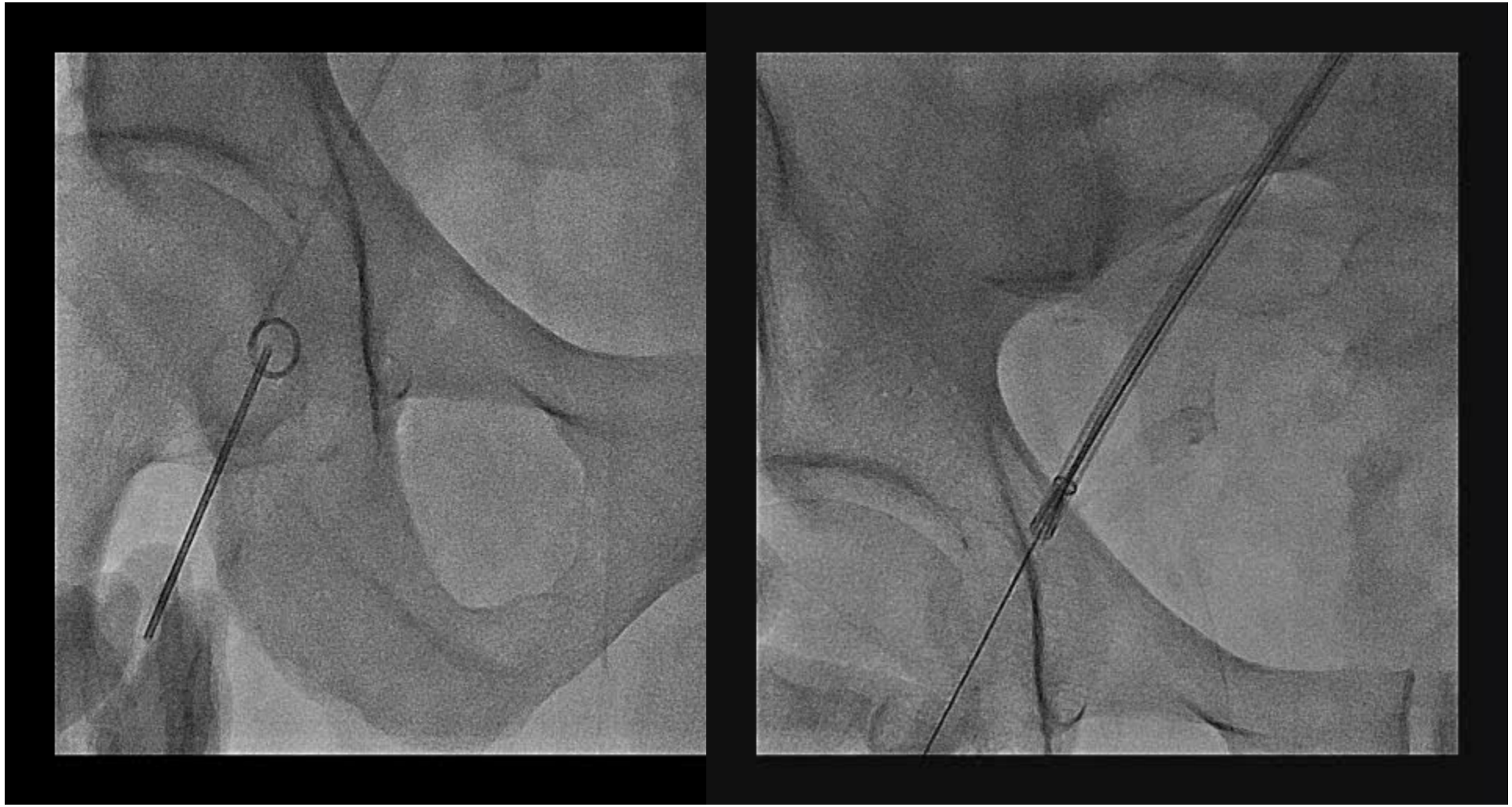

CARDIO RUN 2017

PÔLE SANTÉ LES FLEURS

CARDIO RUN 2017

PÔLE SANTÉ LES FLEURS

Procédure « inhabituelle »

CARDIO RUN 2017

PÔLE SANTÉ LES FLEURS

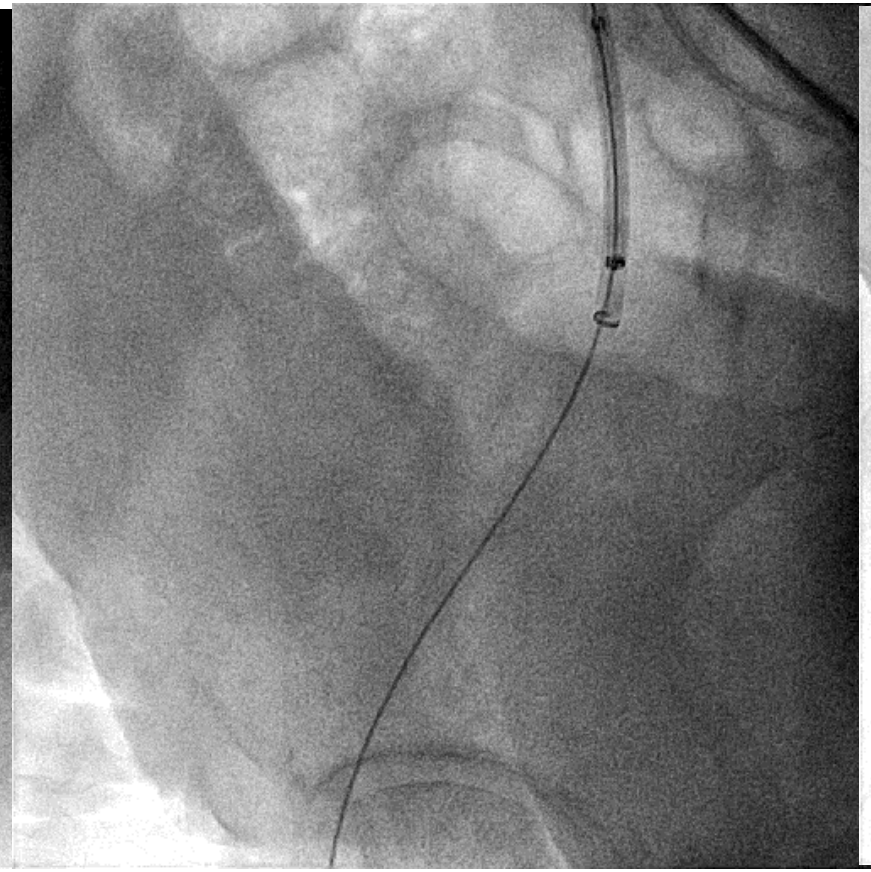

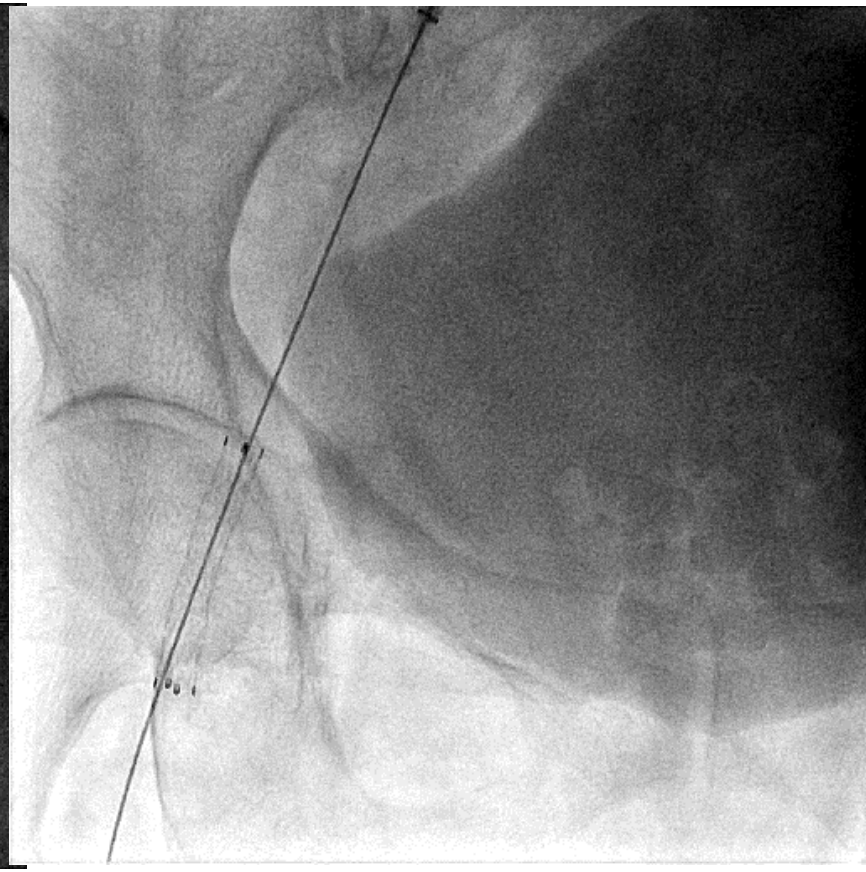

Procédure « inhabituelle »

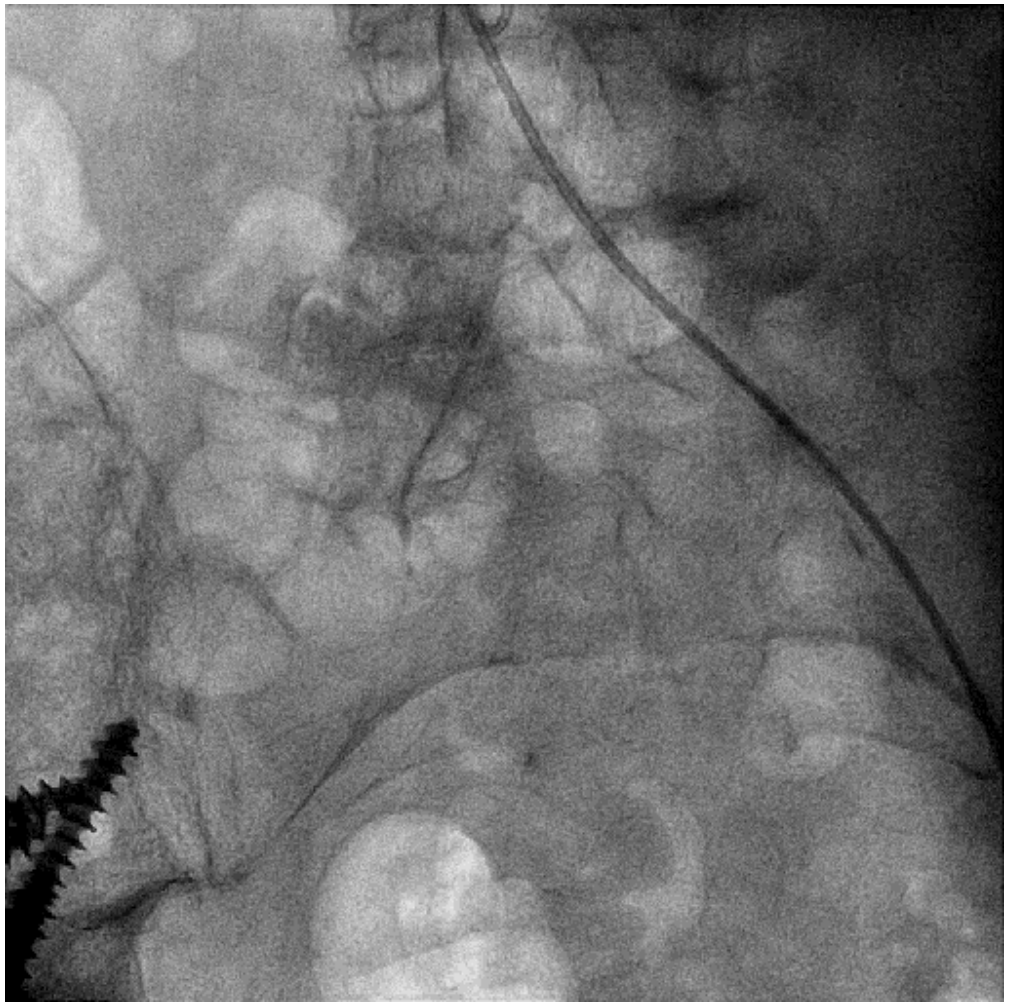

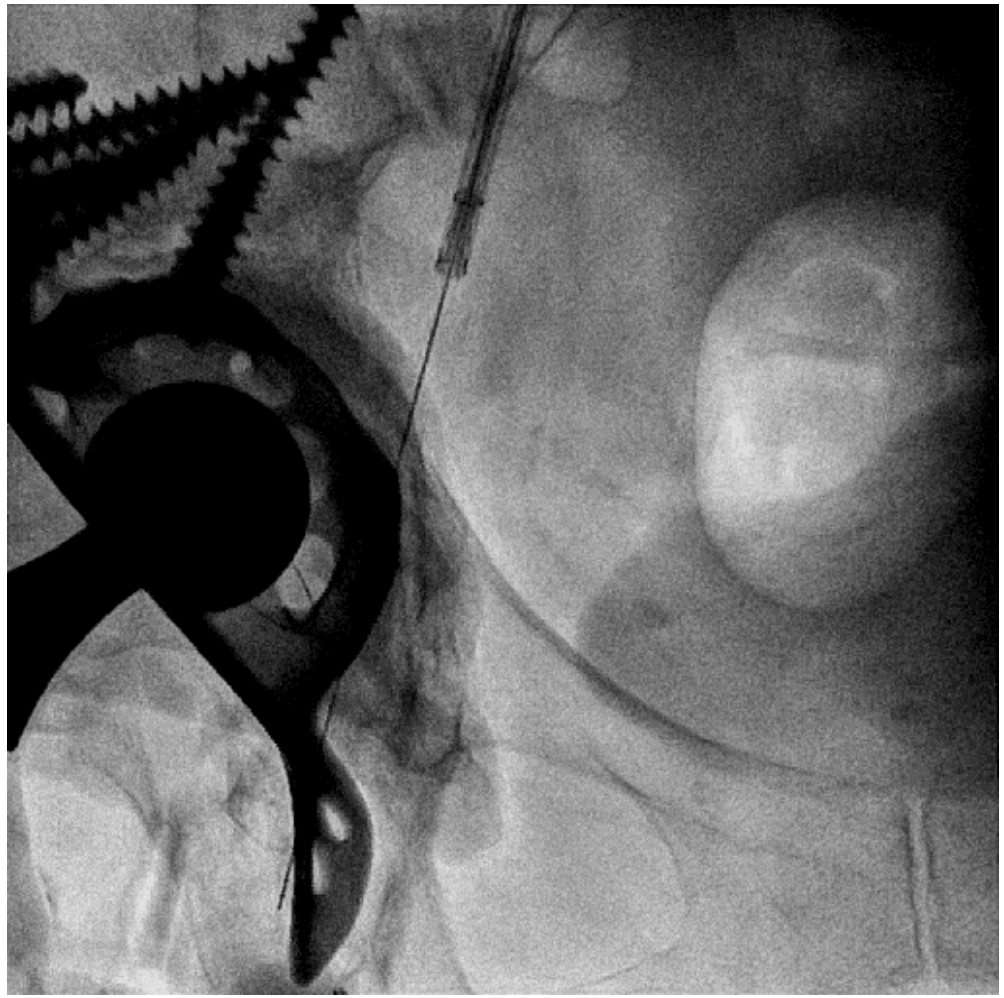

CARDIO RUN 2017

PÔLE SANTÉ LES FLEURS

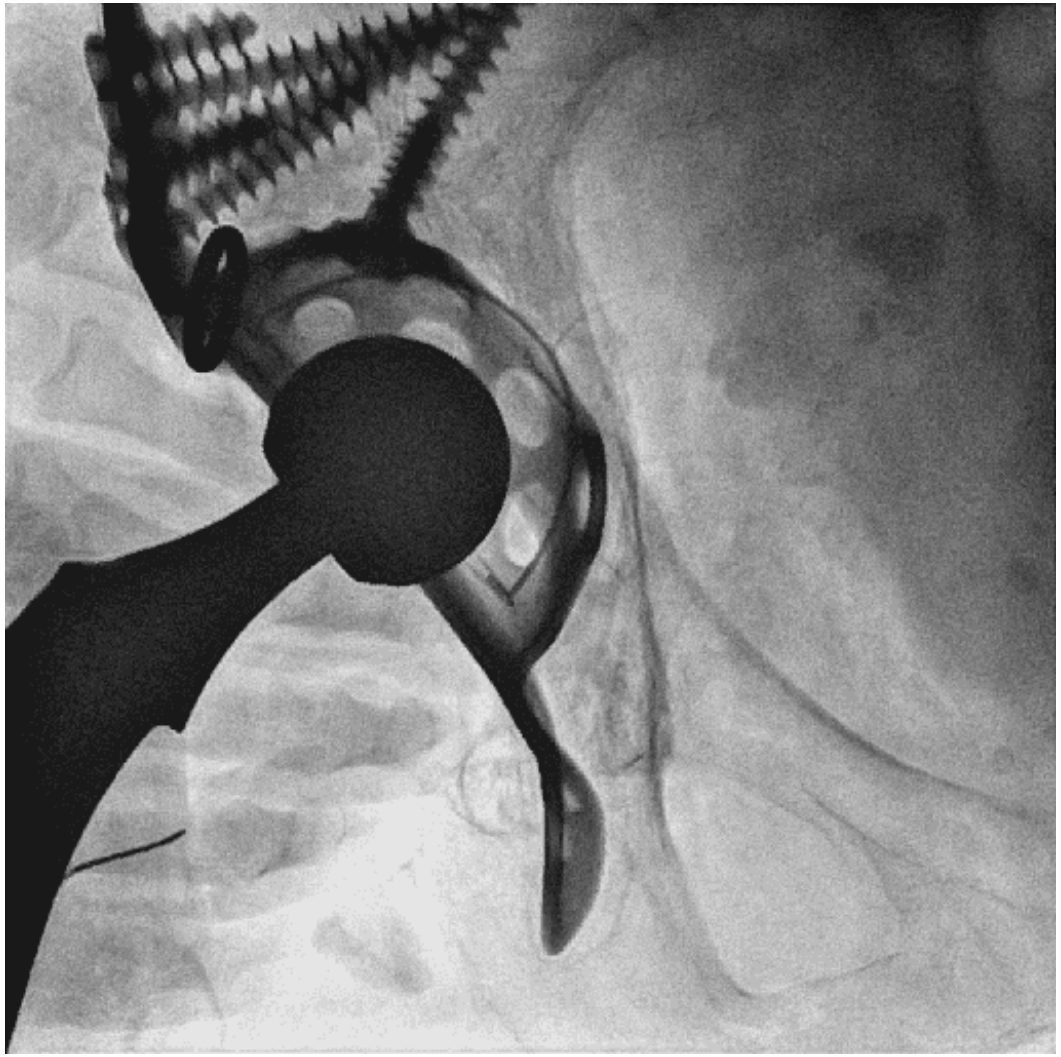

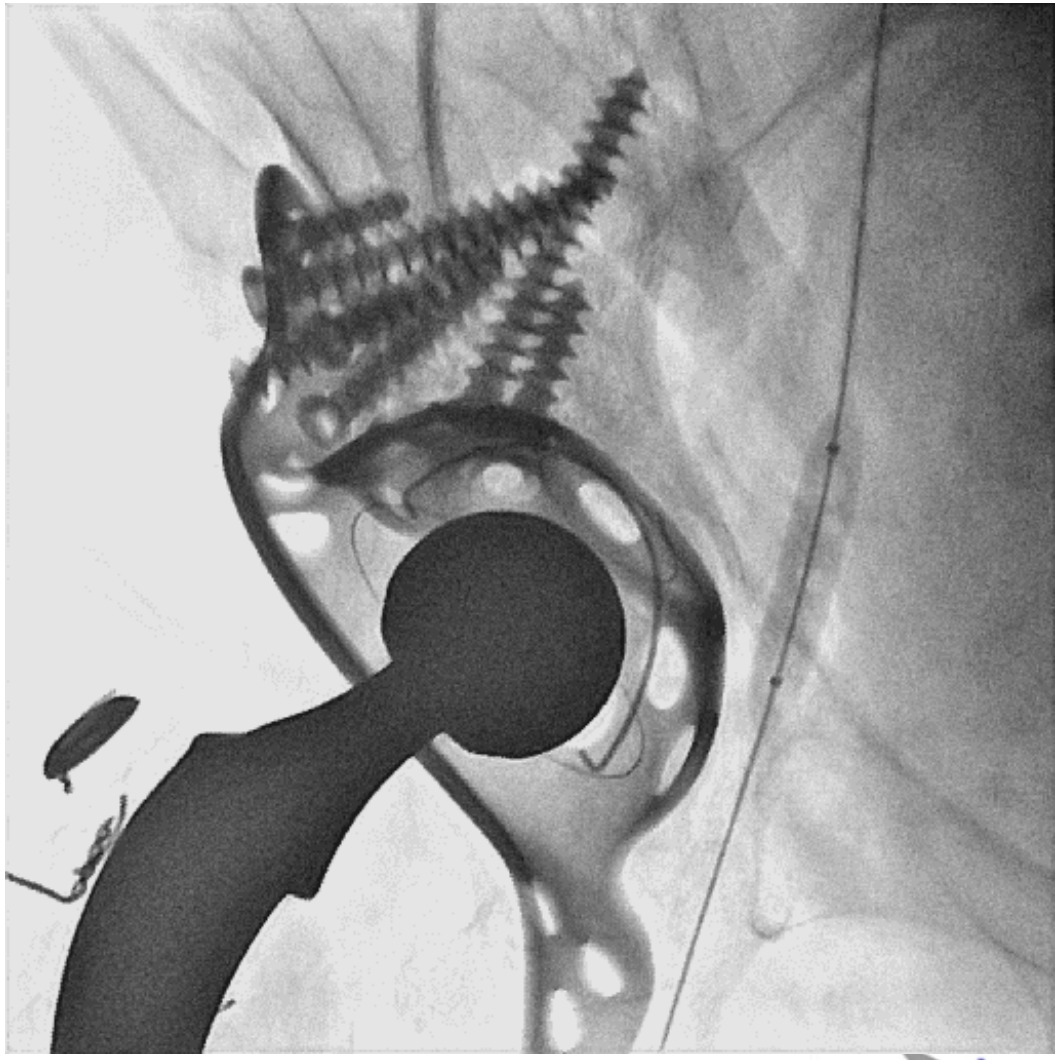

CARDIO RUN 2017

PÔLE SANTÉ LES FLEURS

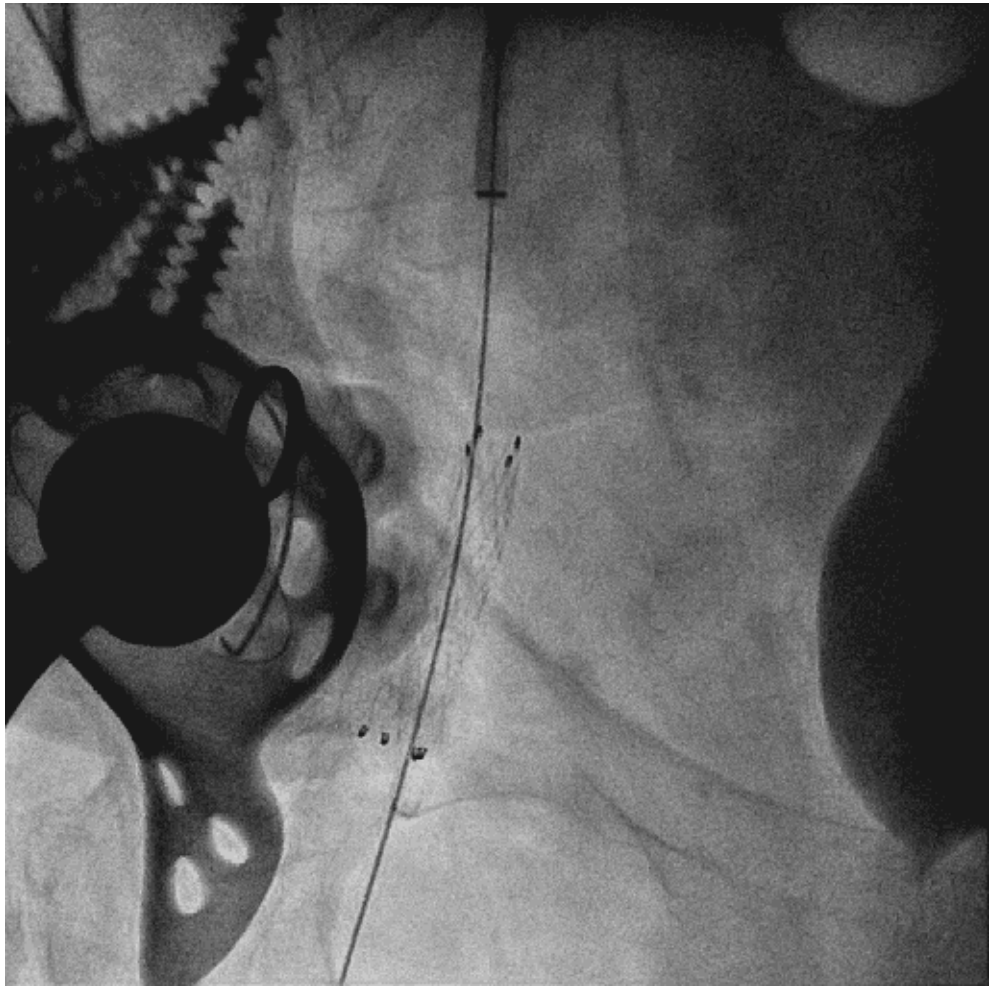

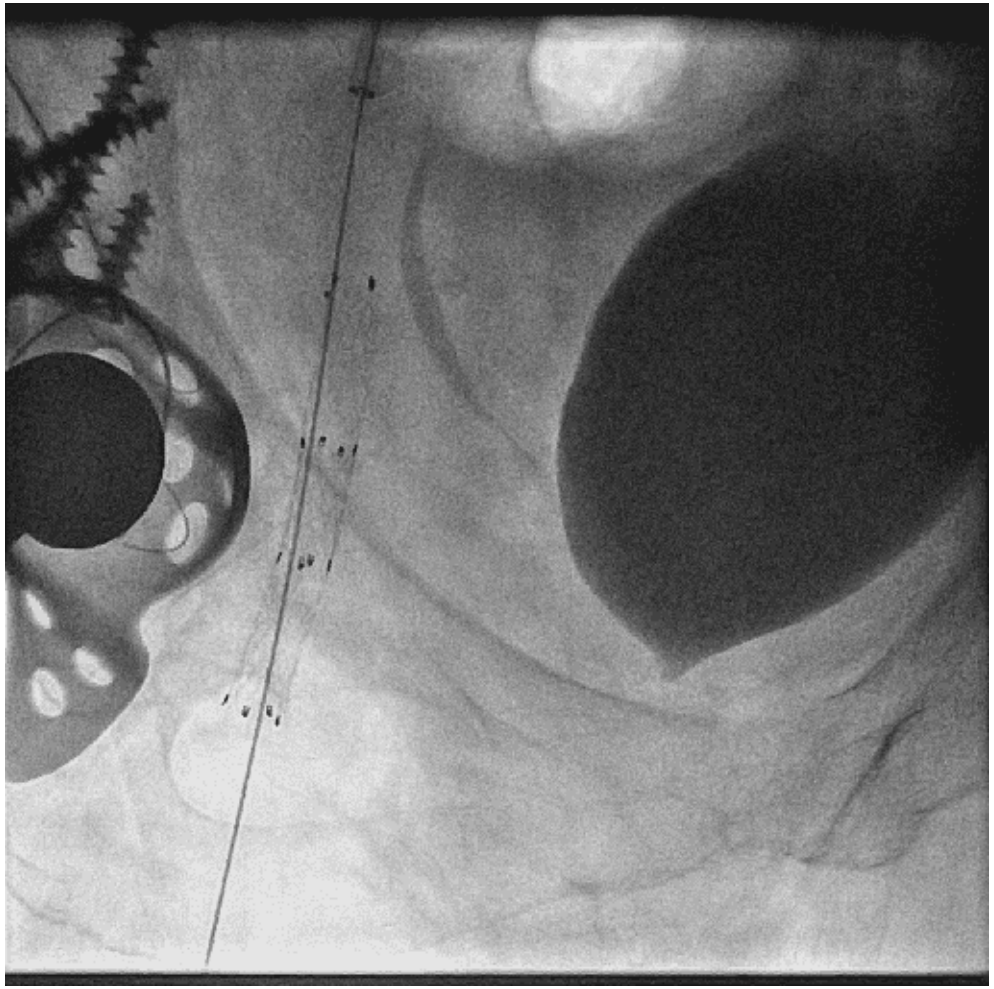

CARDIO RUN 2017

PÔLE SANTÉ LES FLEURS

Procédure « très inhabituelle »

RUN 2017

PÔLE SANTÉ LES FLEURS

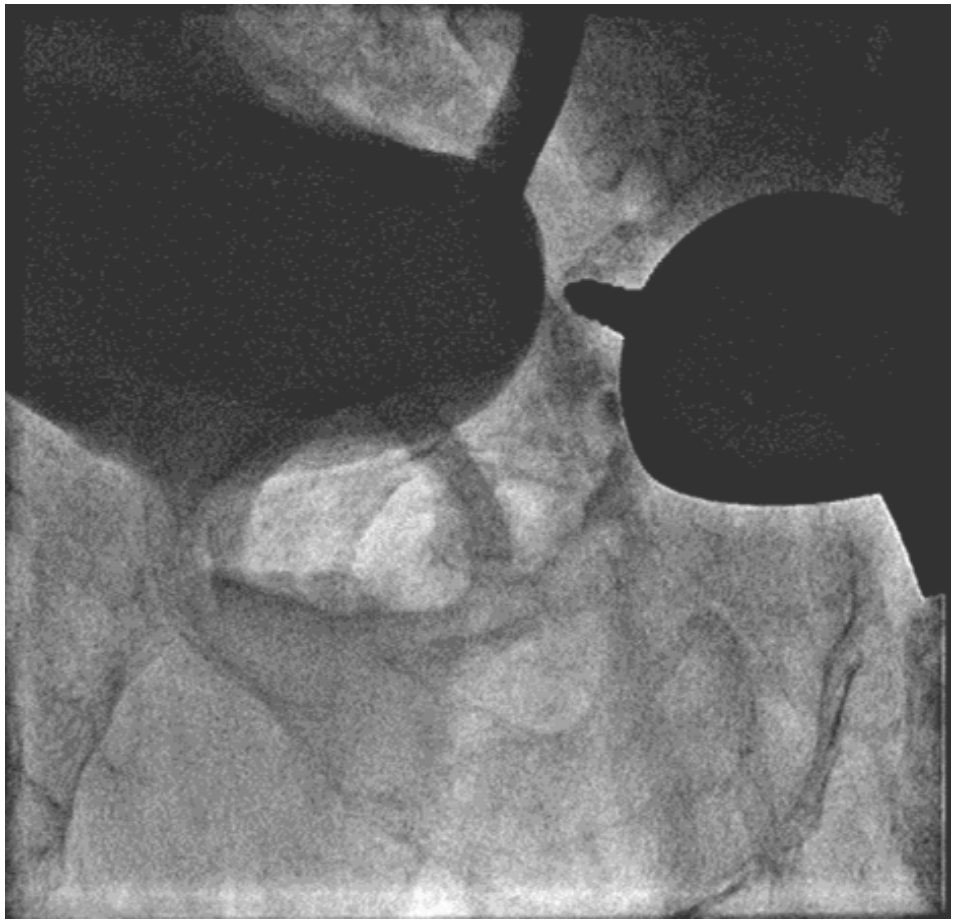

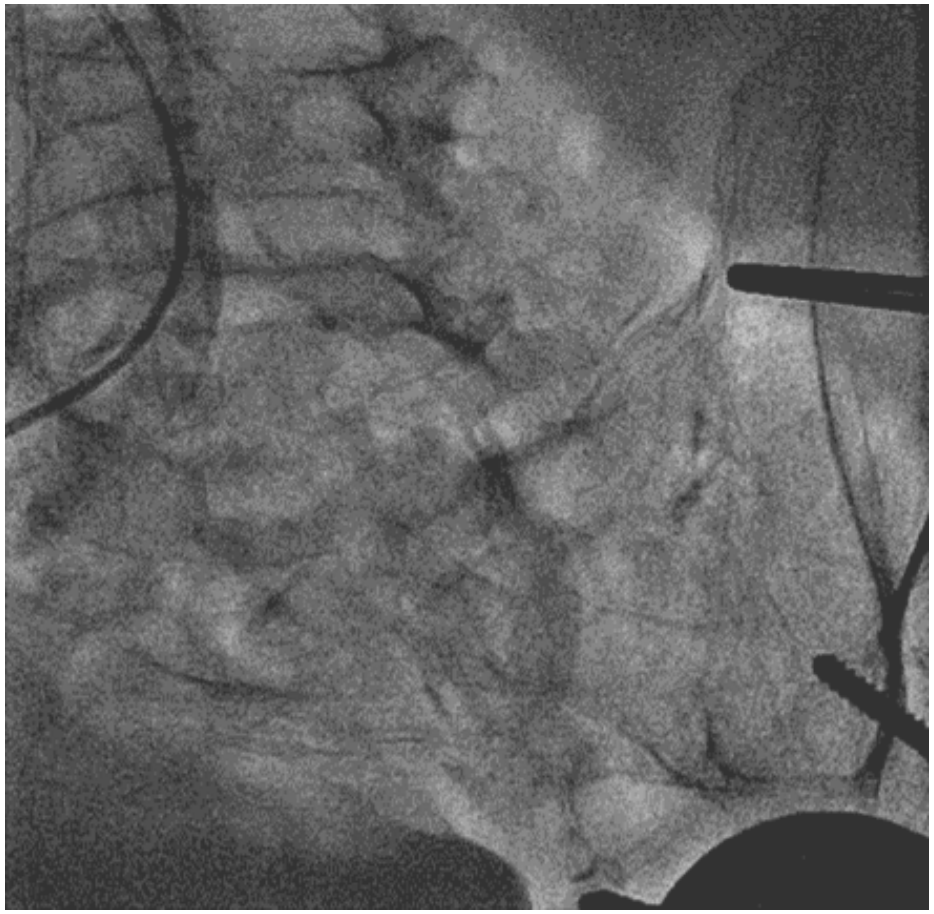

CARDIO RUN 2017

PÔLE SANTÉ LES FLEURS

Procédure « très inhabituelle »

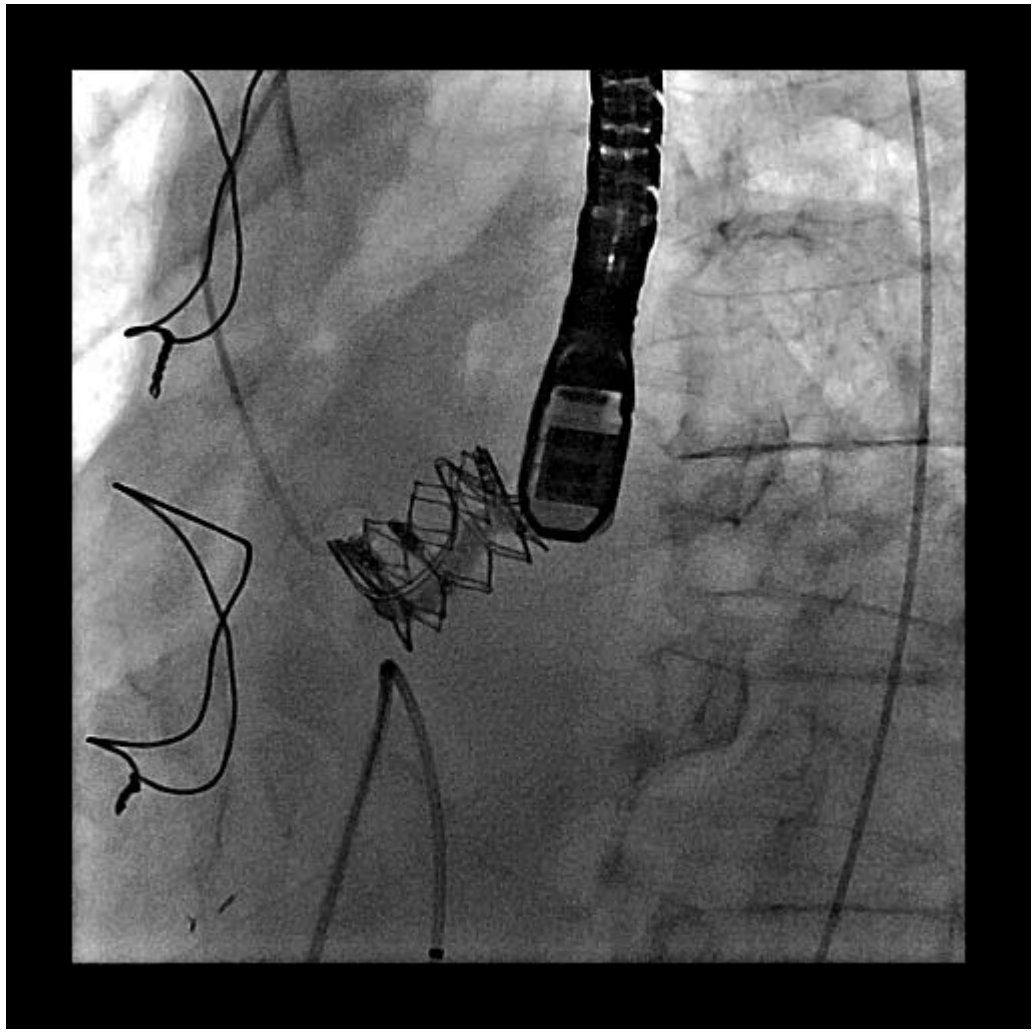

CARDIO RUN 2017

PÔLE SANTÉ LES FLEURS

Ø moy = 6.5mm

CARDIO RUN 2017
PÔLE SANTÉ LES FLEURS

Ø e Sheath 16F ≈ 22mm²

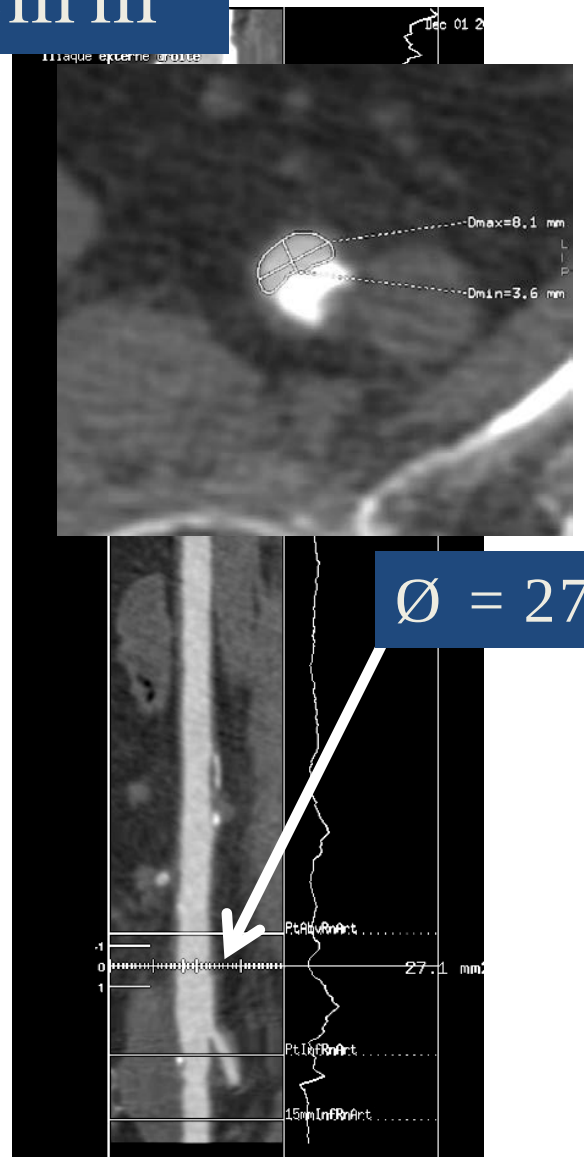

Ø = 27mm²

CARDIO RUN 2017
PÔLE SANTÉ LES FLEURS

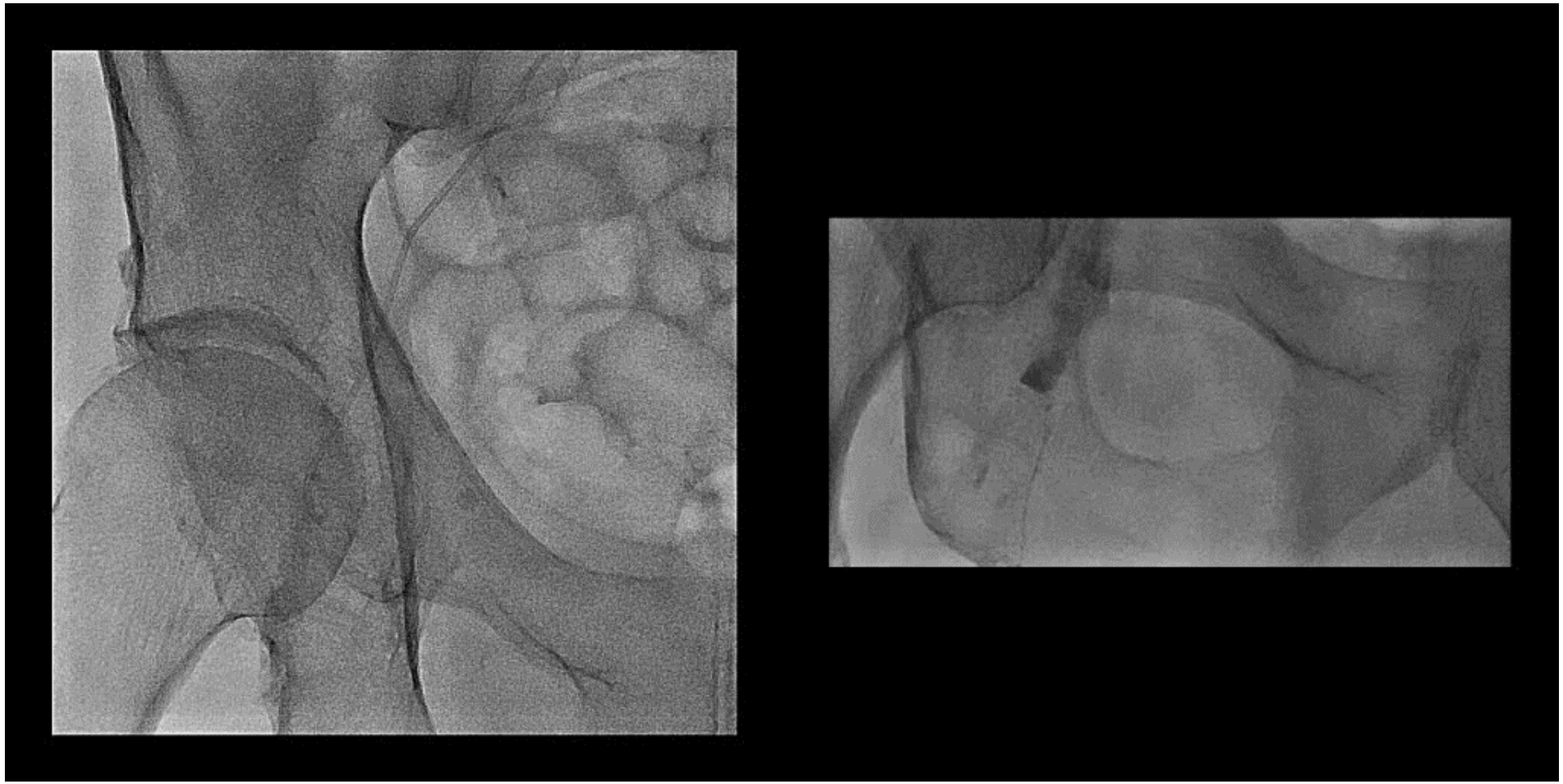

CARDIO RUN 2017

PÔLE SANTÉ LES FLEURS

CARDIO RUN 2017

PÔLE SANTÉ LES FLEURS

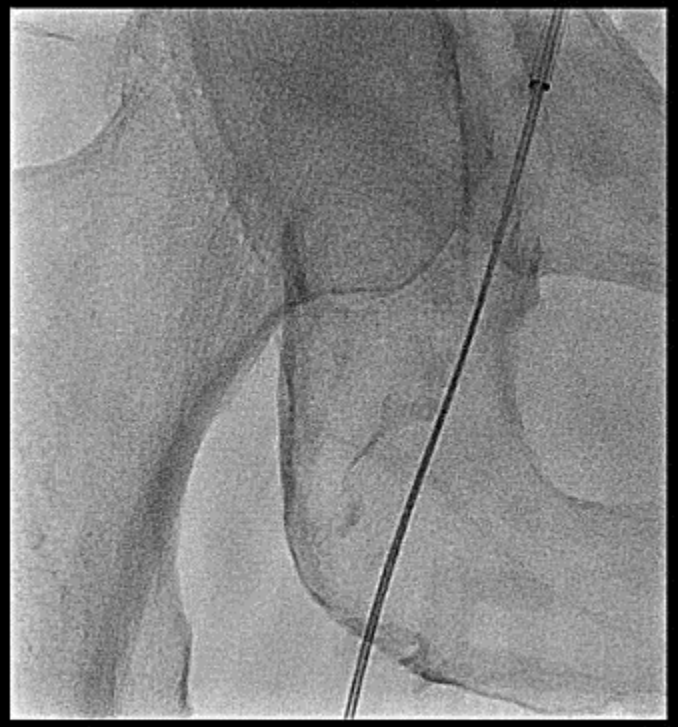

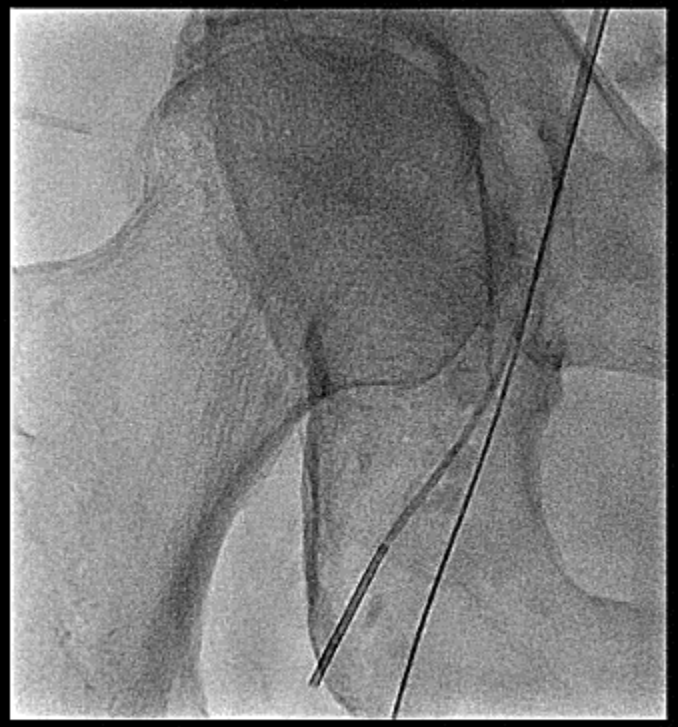

CARDIO RUN 2017

PÔLE SANTÉ LES FLEURS

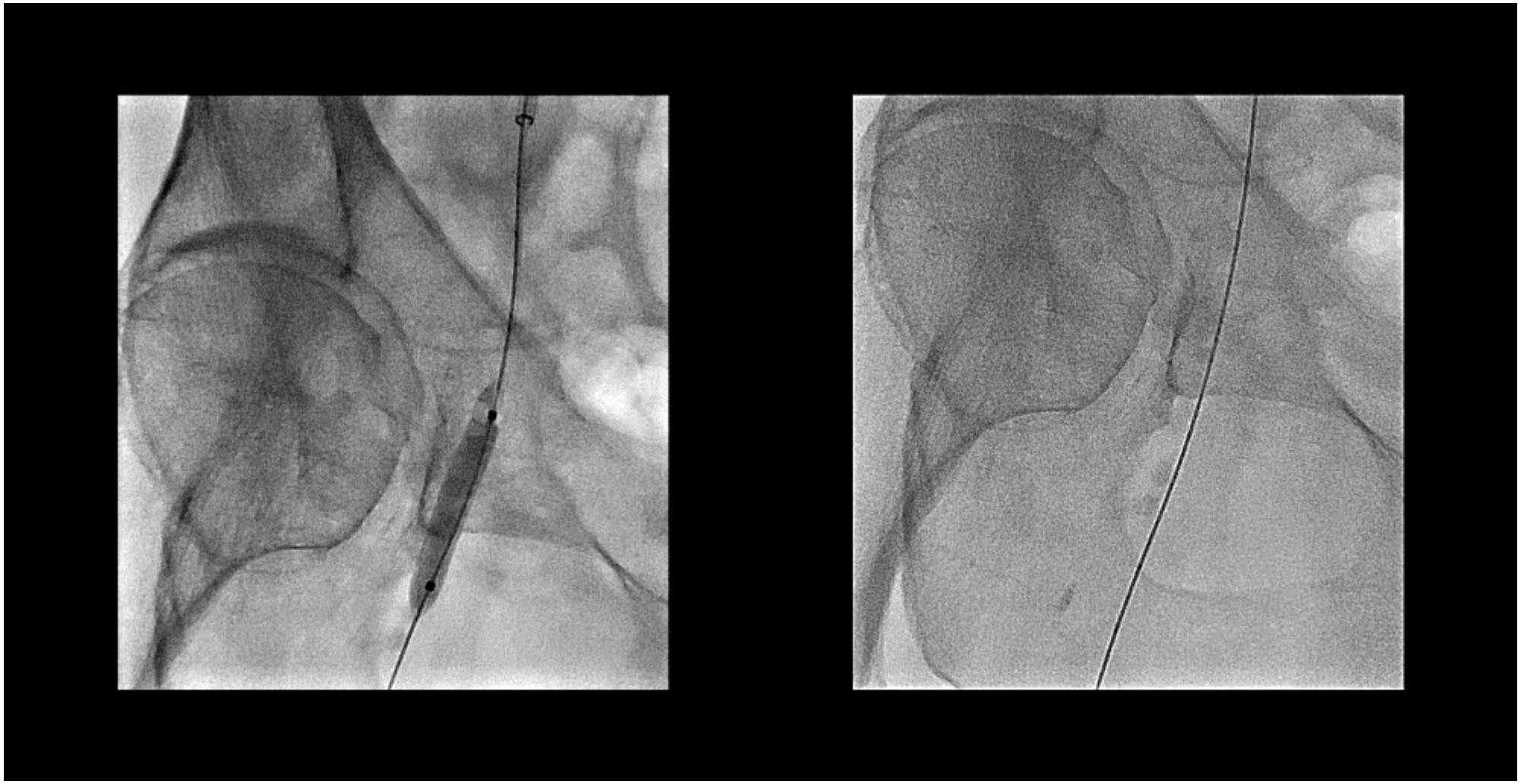

CARDIO RUN 2017

PÔLE SANTÉ LES FLEURS

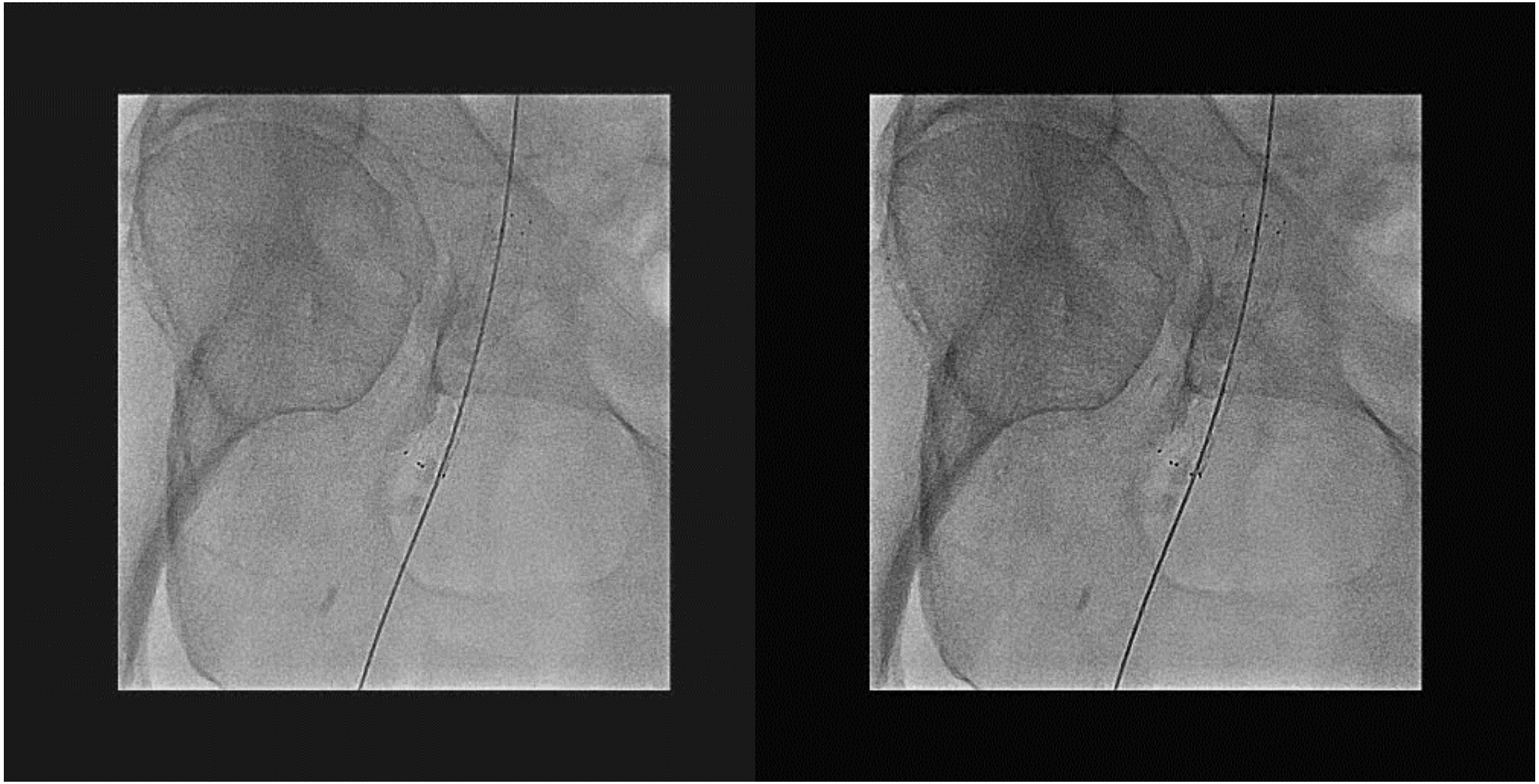

CARDIO RUN 2017

PÔLE SANTÉ LES FLEURS

CARDIO RUN 2017

PÔLE SANTÉ LES FLEURS

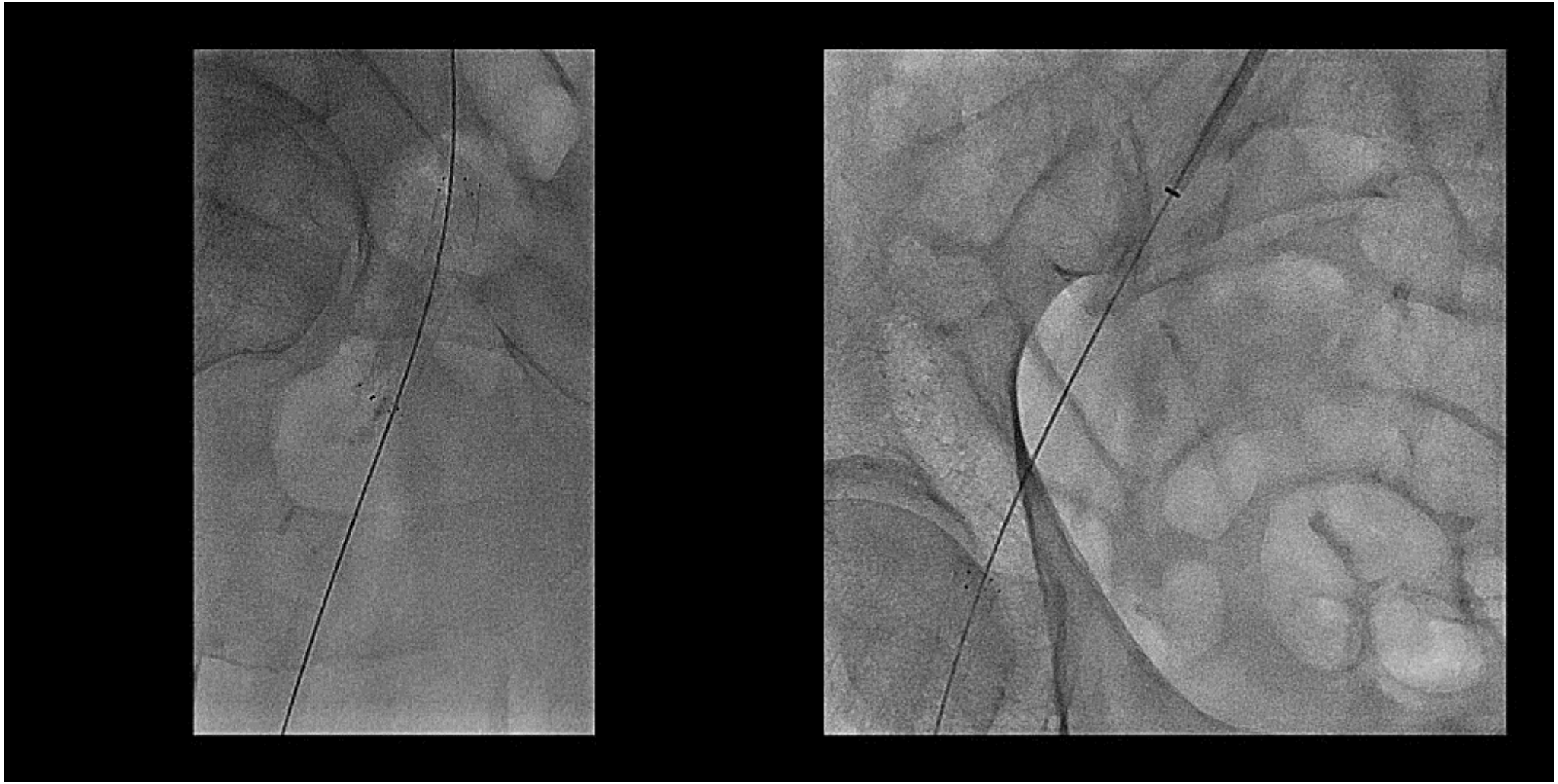

CARDIO RUN 2017

PÔLE SANTÉ LES FLEURS

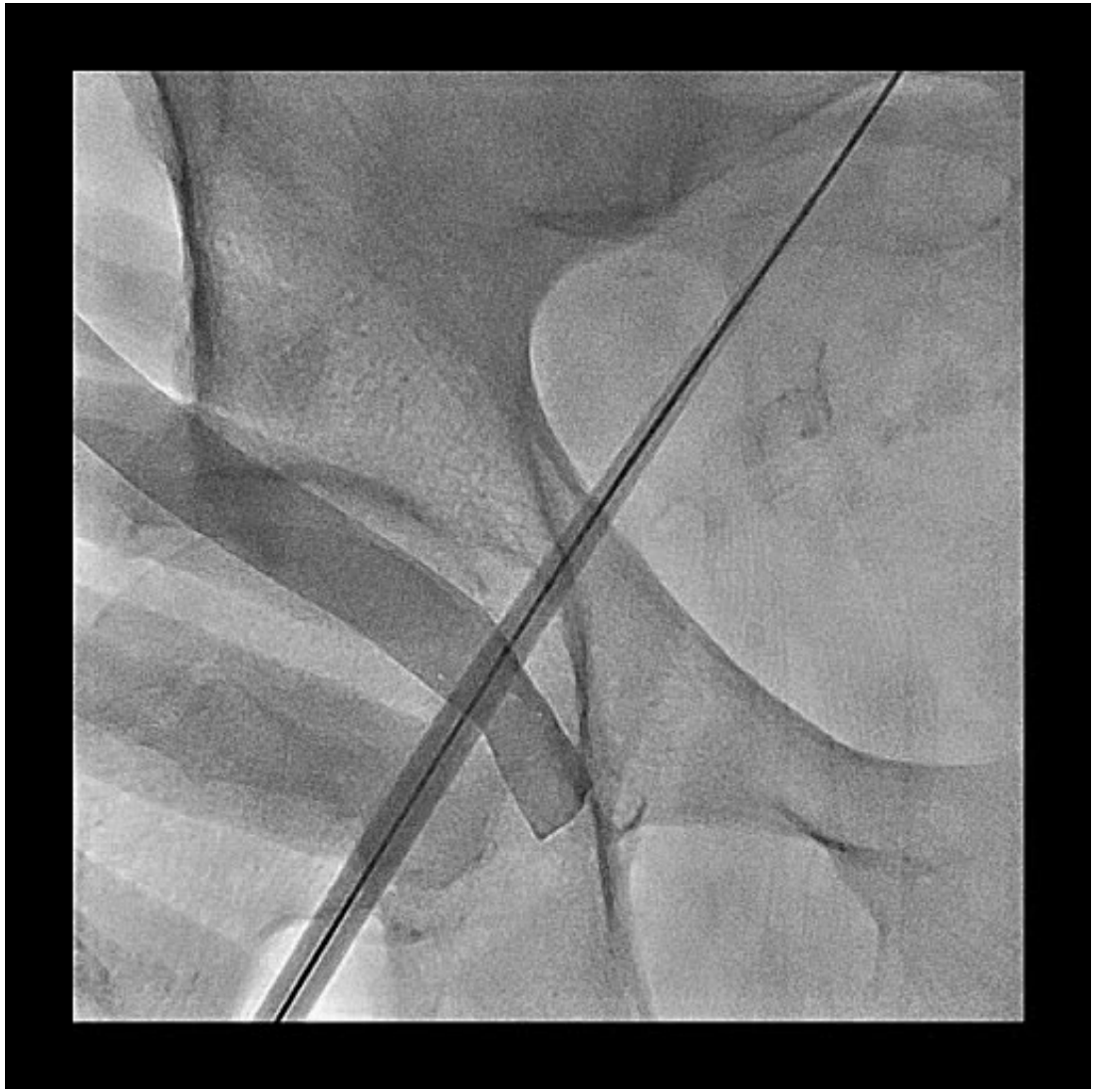

CARDIO RUN 2017

PÔLE SANTÉ LES FLEURS

Complications « devenues » exceptionnelles….

Perforation iliaque

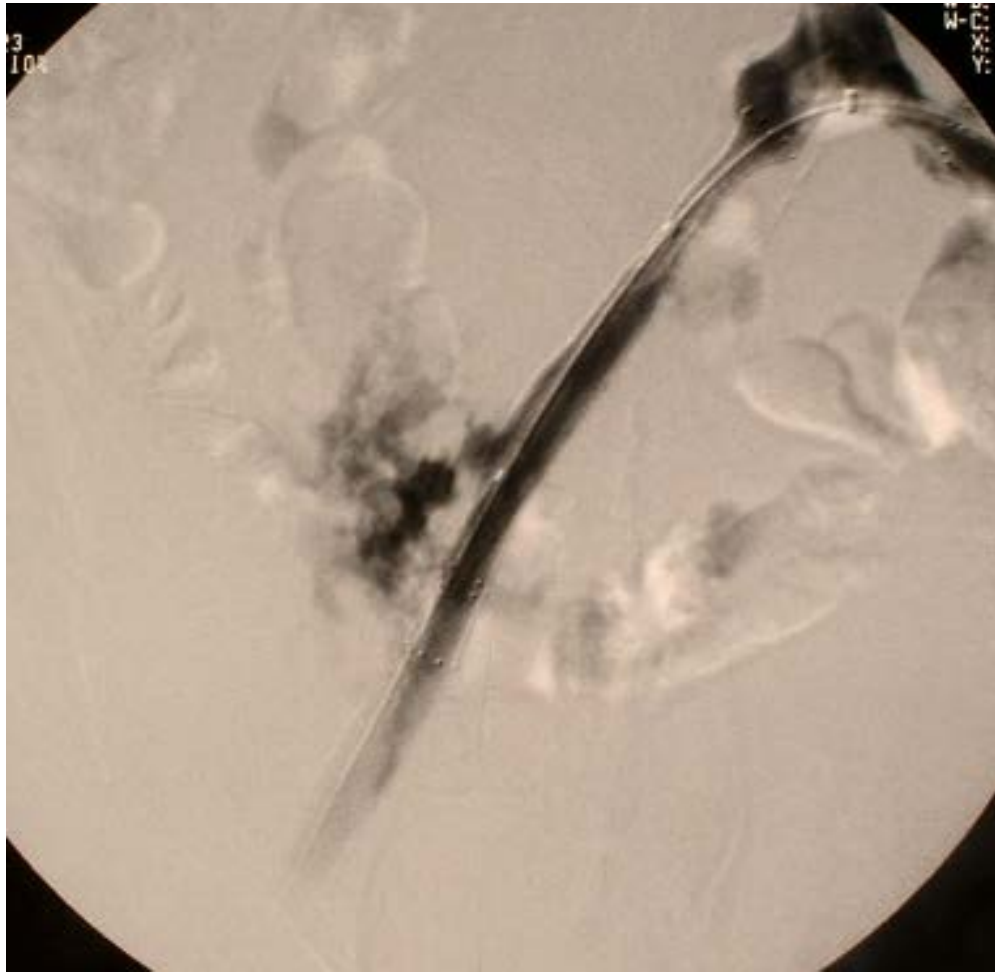

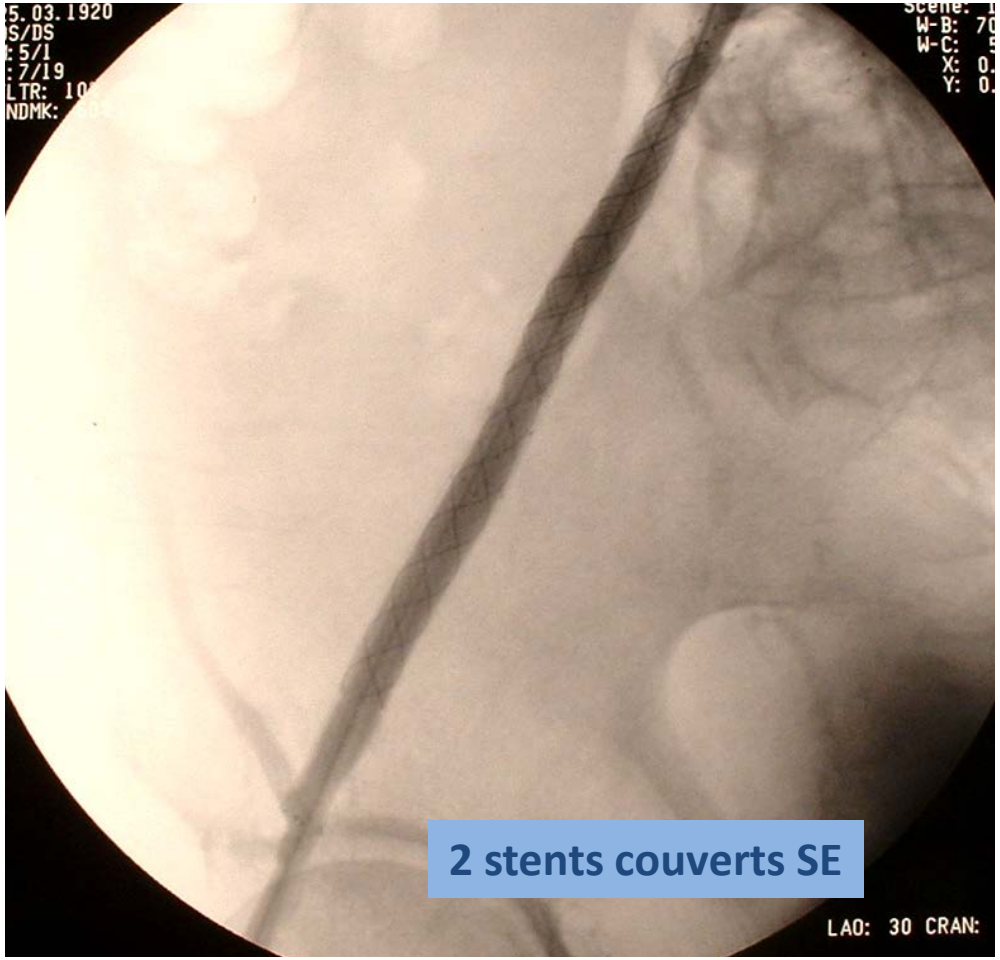

CARDIO RUN 2017
PÔLE SANTÉ LES FLEURS

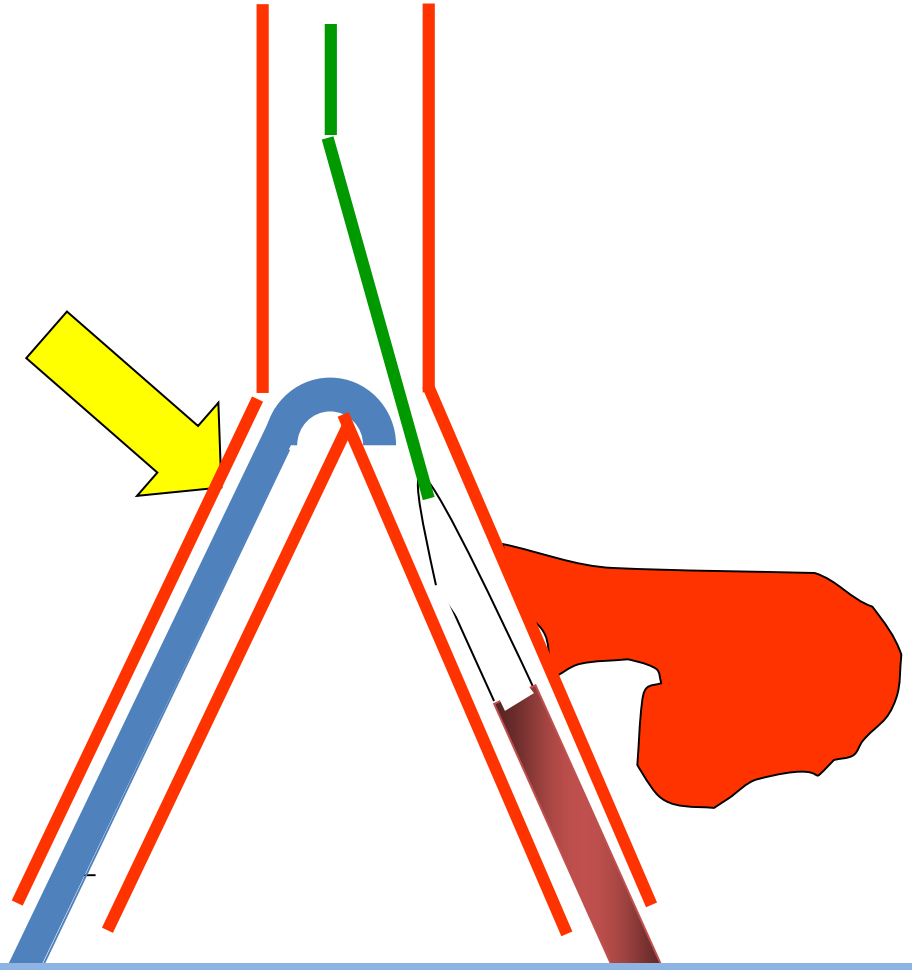

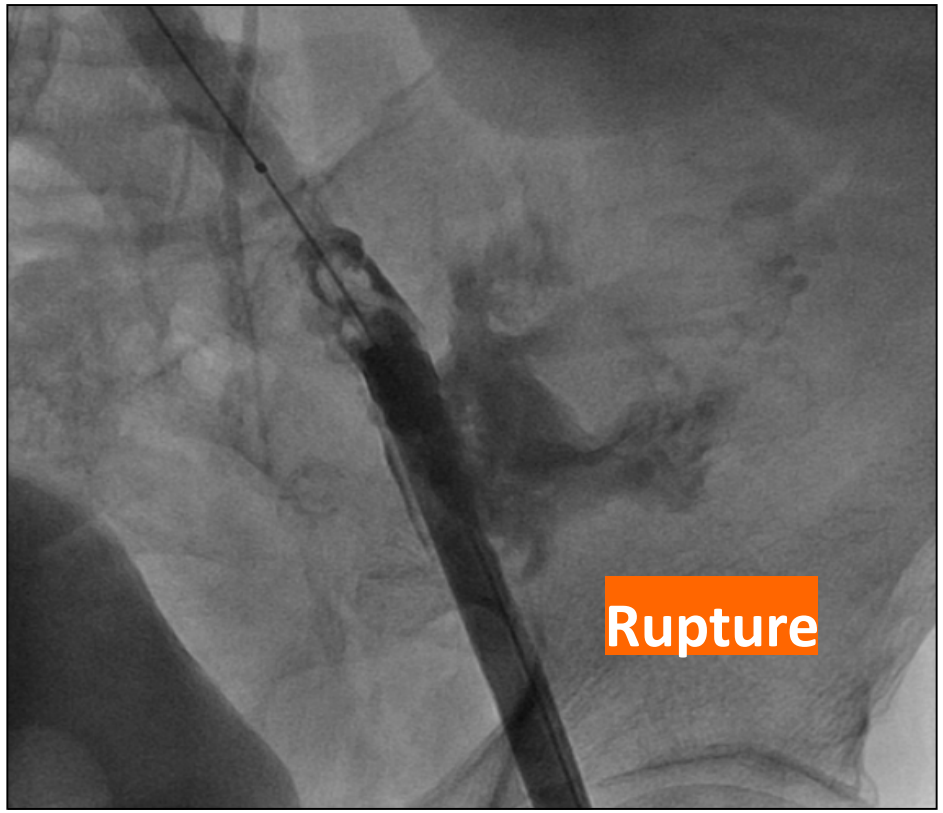

en cas de rupture artérielle:

1. Re-introduire l'introducteur afin d'occlure la brèche
2. Inflater un ballon de gros diamètre (10mm) pour suspendre le flux
3. Implanter un stent couvert

CARDIO RUN 2017

PÔLE SANTÉ LES FLEURS

Il n’y a pas que la fémorale….

- Post procédure immédiate :
  - TAVI en place
  - à l'écho: pas d'épanchement péricardique et FEVG normale,
  - pas de saignement au points de ponction…..
- Choc hypovolémique
- Contrôle artériographique

CARDIO RUN 2017

PÔLE SANTÉ LES FLEURS

????

CARDIO RUN 2017

PÔLE SANTÉ LES FLEURS

Image size: 1024 x 1024
View size: 849 x 849
WL: 2048 WW: 4095
1110266225 (89 y , 89 y)
Face — Face
20101213 143316
25
4096
2048
0
Zoom: 83% Angle: 0
Im: 3/10
JPEGLossless:Non-hierarchical-1stOrderPrediction
Position: HFS
13/12/10 16:30:23
Made in OsiriX

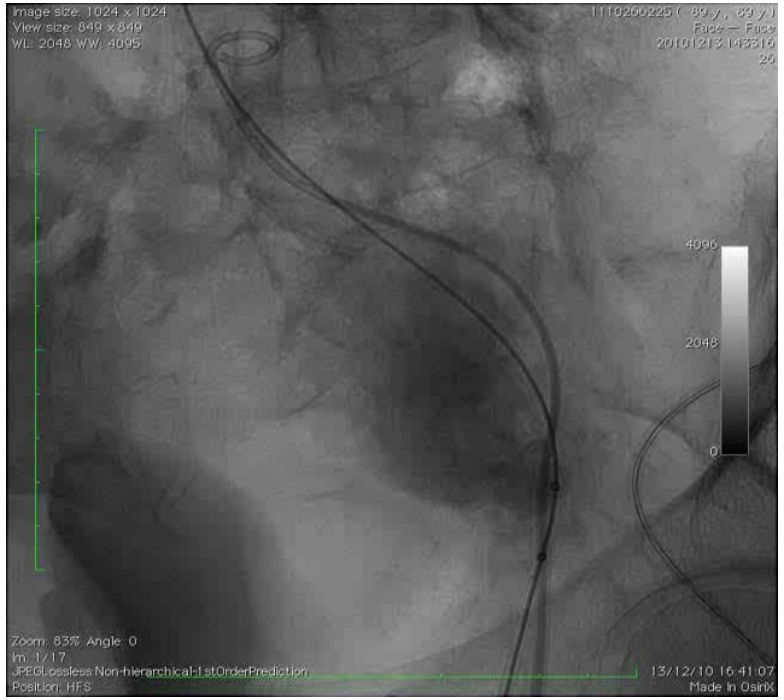
Image size: 1024 x 1024
View size: 849 x 849
WL: 2048 WW: 4095
1110266225 (89 y , 89 y)
Face — Face
20101213 143316
24
4096
2048
0
Zoom: 83% Angle: 0
Im: 1/17
JPEGLossless:Non-hierarchical-1stOrderPrediction
Position: HFS
13/12/10 16:41:07
Made in OsiriX

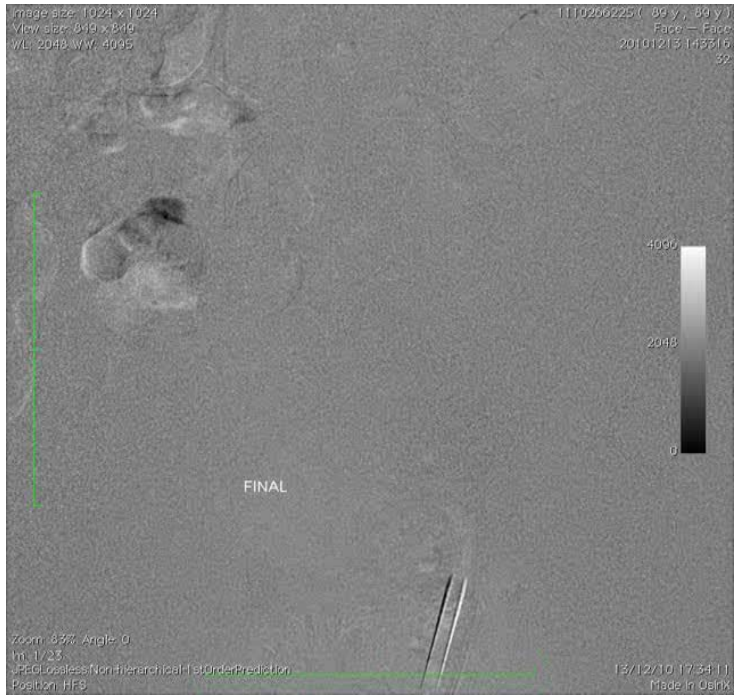
Image size: 1024 x 1024
View size: 849 x 849
WL: 2048 WW: 4095
1110266225 (89 y , 89 y)
Face — Face
20101213 143316
32
4096
2048
0
FINAL
Zoom: 83% Angle: 0
Im: 1/23
JPEGLossless:Non-hierarchical-1stOrderPrediction
Position: HFS
13/12/10 17:34:11
Made in OsiriX

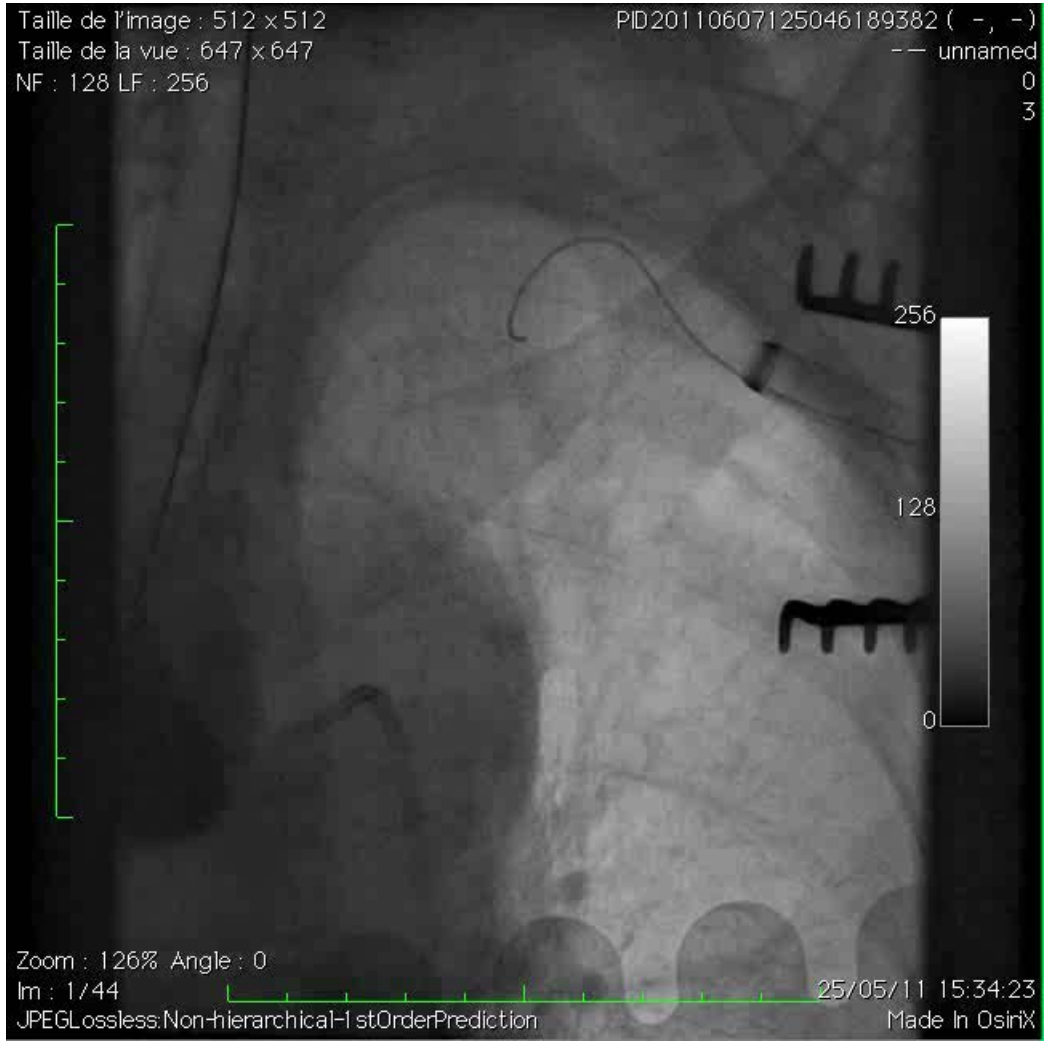
Taille de l'image : 512 x 512
Taille de la vue : 647 x 647
NF : 128 LF : 256
PID201106071250461893 82 (-, -)
-- unnamed
0
3
256
128
0
Zoom : 126% Angle : 0
Im : 1/44
25/05/11 15:34:23
JPEGLossless:Non-hierarchical-1stOrderPrediction
Made In OsiriX

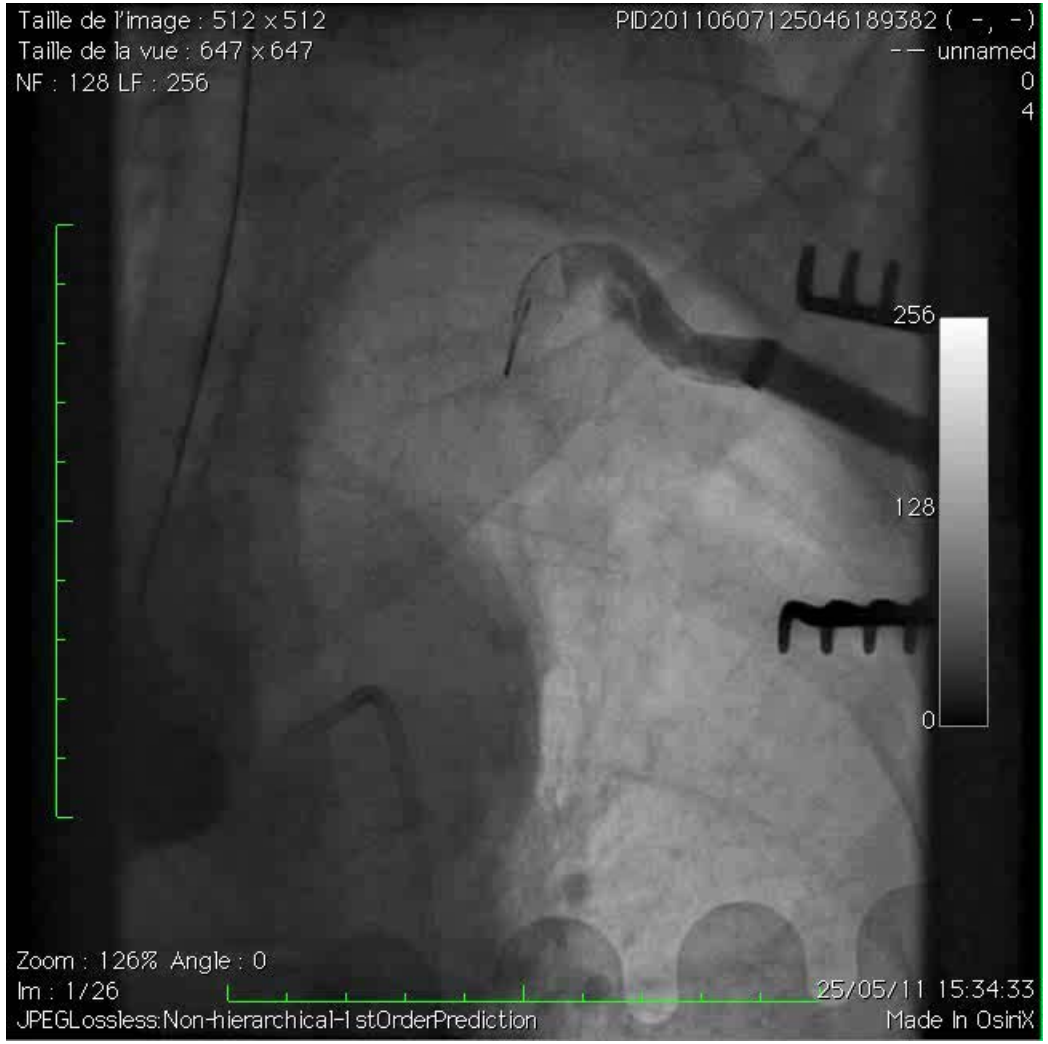
Taille de l'image : 512 x 512
Taille de la vue : 647 x 647
NF : 128 LF : 256
PID201106071250461893 82 (-, -)
-- unnamed
0
4
256
128
0
Zoom : 126% Angle : 0
Im : 1/26
25/05/11 15:34:33
JPEGLossless:Non-hierarchical-1stOrderPrediction
Made In OsiriX

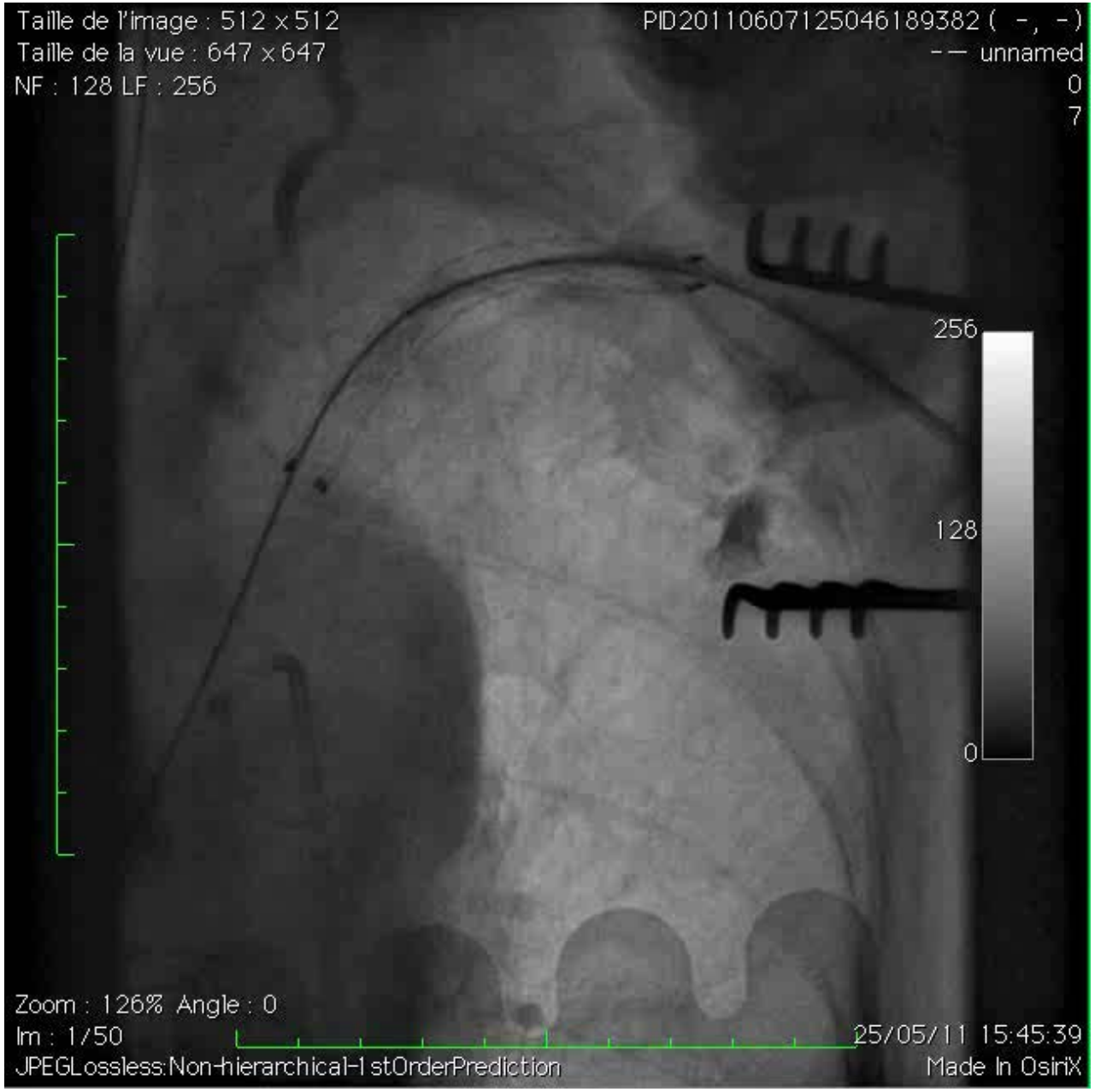

CARDIO RUN 2017

PÔLE SANTÉ LES FLEURS

Stent couvert

- Auto-expandable : Fluency Bard



CARDIO RUN 2017
PÔLE SANTÉ LES FLEURS

Stent couvert

- Ballon expandable : Advanta V12 Atrium

CARDIO RUN 2017

PÔLE SANTÉ LES FLEURS

Stent couvert

- Ballon expandable : LifeStream Bard

CARDIO RUN 2017

PÔLE SANTÉ LES FLEURS

Stent couvert

- Ballon expandable : Be Graft Bentley Innomed



CARDIO RUN 2017

PÔLE SANTÉ LES FLEURS

Conclusions

- Malgré une diminution drastique des complications vasculaires grâce à l'expérience des opérateurs, elles restent redoutables (patients fragiles, transfusion abondante avec les risques biologiques, hospitalisation prolongée..)
- La survenue de ces complications nécessite une prise en charge immédiate et donc d'avoir une bonne formation en interventionnel périphérique (technique de cross over, matériel, imagerie soustraite…)
- Connaissance du matériel en particulier le stent couvert (compatibilité avec l'introducteur+++)